



PATIENT

Zoey Greenan

SPECIES

Feline

BREED

Domestic Shorthair

SEX

Spayed female

AGE

8 years

WEIGHT

11.66 lbs

INTERPRETED BY

Remo Lobetti, BVSc,
MMedVet (Med),
PhD, Dipl. ECVIM

IMAGING PERFORMED BY

Dr. Striano Kaplan

HOSPITAL NAME

Ramsey VH

REFERRING VET

Dr. Striano Kaplan

INVOICE

71264

DATE

2/5/26

PRESENTING CLINICAL SIGNS

- Hematuria - r/o FLUTD vs cystitis vs stones vs other. Inappropriate eliminations, history of constipation
- ON: Dasuquin 1SID, Gabapentin 50 mg tab 1tbid, Fluoxetine 5 mg tab 1tsid, Lactulose 10 mg/ml 0.1 ml po EOD
- Labs 1/23/26 no growth on urine c+s Neutrophil 2415, USG 1.023, PH 8.0 Unremarkable exam Radiology report 1/28 - scant caudal peritoneal effusion

ULTRASONOGRAPHIC EXAMINATION OF THE ABDOMEN

Urinary System

The urinary bladder is full with a normal thickness and smooth appearance of the wall. Normal anechoic urine with no sediment or uroliths evident.

Normal appearance of the trigone area, proximal urethra, and iliac blood vessels.

Normal appearance and size of the iliac lymph nodes. Ureters not visualized, which can be considered a normal finding.

Normal renal size (left measured 4.2 cm, right measured 4.5 cm), architecture, echogenic appearance, cortico-medullary differentiation, which maintains a 1:3 cortex to medulla ratio, pelvis, and capsule. No infarcts, mineralization or renoliths evident.

Adrenal Glands

The adrenal glands were not visualized.

Spleen

Normal size and echogenic appearance. Smooth homogenous parenchyma and regular curvilinear capsule. Normal volume of the splenic vasculature without any overt congestion or thrombosis evident. No inflammatory, neoplastic, infarction, or infiltrative changes evident. The spleen measured 0.7 cm in width.

Liver

Normal size, echogenic appearance, portal markings, and regular curvilinear capsule. No nodules or masses evident. Normal appearance of the hepatic and portal vasculature.

Gallbladder

The gallbladder is small containing normal anechoic bile. Normal thickness and echogenic appearance of the wall. Normal size and appearance of the cystic and common bile duct.



PATIENT

Zoey Greenan

SPECIES

Feline

BREED

Domestic Shorthair

SEX

Spayed female

AGE

8 years

WEIGHT

11.66 lbs

INTERPRETED BY

Remo Lobetti, BVSc,
MMedVet (Med),
PhD, Dipl. ECVIM

IMAGING PERFORMED BY

Dr. Striano Kaplan

HOSPITAL NAME

Ramsey VH

REFERRING VET

Dr. Striano Kaplan

INVOICE

71264

DATE

2/5/26

Gastrointestinal

Normal appearance of the stomach, duodenum, small intestine, ileo-cecal junction, and colon with no loss of layering, 1:3 muscularis to mucosa ratio, normal wall thickness and peristaltic activity, and no distension of the lumen.

Pancreas

The visible sections of the pancreas are of normal size and echogenic appearance with a regular capsule. Normal echogenic appearance of the mesentery and fat surrounding the pancreas.

Free Abdomen

Normal mesenteric lymph nodes.

No ascites evident.

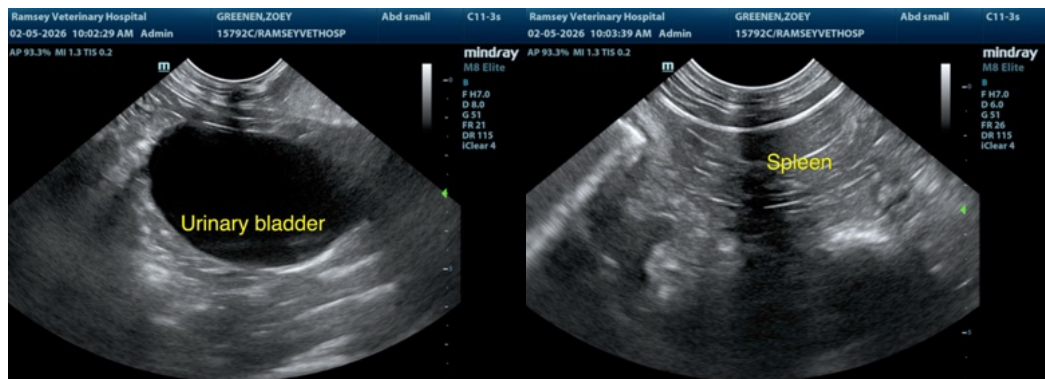
ULTRASONOGRAPHIC FINDINGS

- Normal ultrasound examination of the abdomen.

INTERPRETATION OF THE FINDINGS & FURTHER RECOMMENDATIONS

On this ultrasound there is no obvious etiology for the presenting clinical signs.

The most likely diagnosis would be feline interstitial or idiopathic cystitis. Long term management would be environmental enrichment and feeding a urinary specific diet.





PATIENT

Zoey Greenan

SPECIES

Feline

BREED

Domestic Shorthair

SEX

Spayed female

AGE

8 years

WEIGHT

11.66 lbs

INTERPRETED BY

Remo Lobetti, BVSc,
MMedVet (Med),
PhD, Dipl. ECVIM

IMAGING PERFORMED BY

Dr. Striano Kaplan

HOSPITAL NAME

Ramsey VH

REFERRING VET

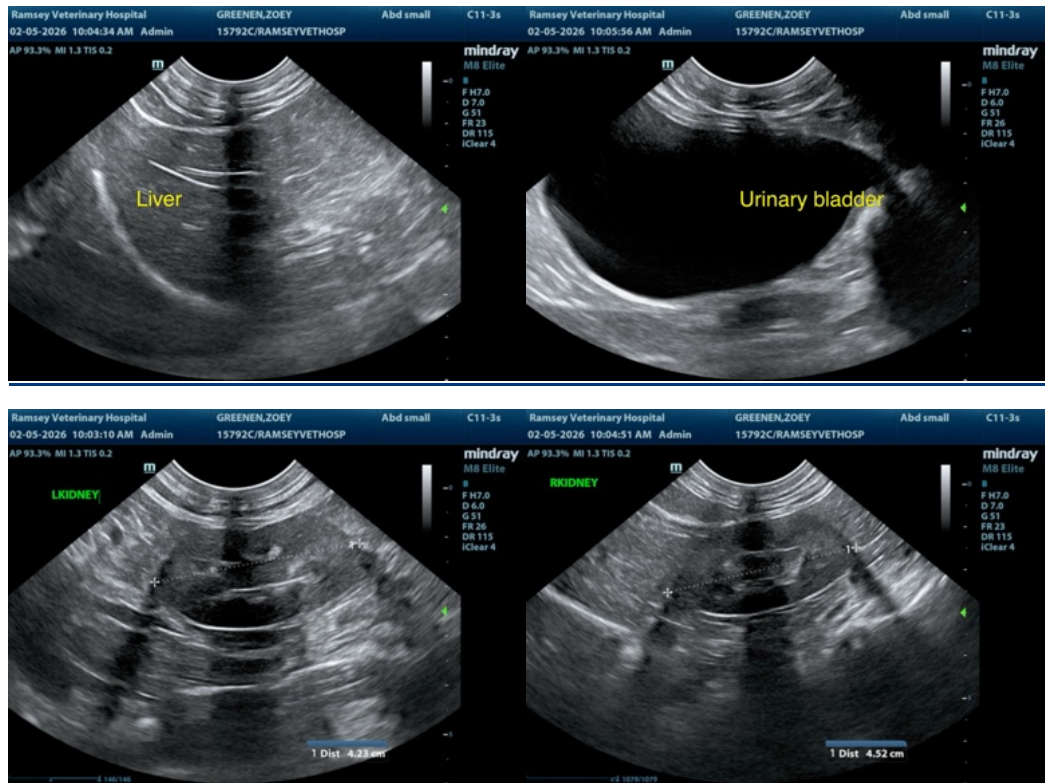
Dr. Striano Kaplan

INVOICE

71264

DATE

2/5/26



The information and recommendations provided are based on the images presented by the referring veterinarian/sonographer. No evaluation can be communicated regarding pathology that was not visible in the image/video clips provided.

Thank you for this referral. If the clinical or image interpretation does not parallel your findings or if I can be of any further assistance please contact me.

Remo Lobetti, BVSc, MMedVet (Med), PhD, Dipl. ECVIM (Internal Medicine)

info@sonopath.com