



PATIENT

Peanut Richartz

SPECIES

Canine

BREED

Terrier Mix

SEX

Neutered male

AGE

13 years

WEIGHT

11 lbs

INTERPRETED BY

Remo Lobetti, BVSc,
MMedVet (Med),
PhD, Dipl. ECVIM

IMAGING PERFORMED BY

Dr. Michael Ferber

HOSPITAL NAME

East Meadow VC

REFERRING VET

Dr. Ferber

INVOICE

71229

DATE

2/4/26

PRESENTING CLINICAL SIGNS

- Chronic soft stool, poor appetite, weight loss
- Elevated ALP, ALT, AST - for about 2 years but values have been increasing normal B12/folate/cortisol
- Patient won't eat HA or enteric diet

ULTRASONOGRAPHIC EXAMINATION OF THE ABDOMEN

Urinary System

The urinary bladder is full with a normal thickness and smooth appearance of the wall. Normal anechoic urine with no sediment or uroliths evident.

Normal appearance of the trigone area, proximal urethra, and iliac blood vessels.

Normal appearance and size of the iliac lymph nodes. Ureters not visualized, which can be considered a normal finding.

Normal renal size (left measured 3.5 cm, right measured 3.9 cm), increased echogenic appearance, some loss of cortico-medullary differentiation, and normal pelvis and capsule. No infarcts, mineralization or renoliths evident. Normal color flow pattern is evident in both kidneys.

The prostate is small and hypoechogenic.

Adrenal Glands

The left adrenal gland is normal in shape, echogenic appearance, size, position, and appearance of the visible peri-adrenal vasculature. Left adrenal gland measured 0.38 cm in width. The right adrenal gland was not clearly visualized, but appears to be of normal shape, echogenic appearance and size.

Spleen

Normal size and echogenic appearance. Smooth homogenous parenchyma and regular curvilinear capsule. Normal volume of the splenic vasculature without any overt congestion or thrombosis evident. Incidental myelolipoma is present. No inflammatory, neoplastic, infarction, or infiltrative changes evident. The spleen measured 1.1 cm in width.

Liver

Normal size with a diffuse increased echogenic and coarse appearance, normal portal markings, and regular curvilinear capsule. No nodules or masses evident. Normal appearance of the hepatic and portal vasculature.



PATIENT

Peanut Richartz

SPECIES

Canine

BREED

Terrier Mix

SEX

Neutered male

AGE

13 years

WEIGHT

11 lbs

INTERPRETED BY

Remo Lobetti, BVSc,
MMedVet (Med),
PhD, Dipl. ECVIM

IMAGING PERFORMED BY

Dr. Michael Ferber

HOSPITAL NAME

East Meadow VC

REFERRING VET

Dr. Ferber

INVOICE

71229

DATE

2/4/26

Gallbladder

The gallbladder is full containing normal anechoic bile. Normal thickness and echogenic appearance of the wall. Normal size and appearance of the cystic and common bile duct.

Gastrointestinal

Normal appearance of the stomach, duodenum, small intestine, ileo-cecal junction, and colon with no loss of layering, 1:3 muscularis to mucosa ratio, normal wall thickness and peristaltic activity, and no distension of the lumen. A small amount of ingesta is present in the stomach and chyme is present within the proximal small intestine, both compatible with a recent meal.

Pancreas

The visible sections of the pancreas are of normal size and echogenic appearance with a regular capsule. Normal echogenic appearance of the mesentery and fat surrounding the pancreas.

Free Abdomen

Normal mesenteric lymph nodes.

No ascites evident.

ULTRASONOGRAPHIC FINDINGS

- Hepatopathy.

INTERPRETATION OF THE FINDINGS & FURTHER RECOMMENDATIONS

Etiologies for the hepatopathy would be reactive hyperplasia, early nodular hyperplasia, vacuolar and metabolic with hepatitis and infiltrative neoplasia an unlikely differential diagnosis.

Further assessment would be FNA cytology of the liver. However, a tru cut or wedge biopsy may be required for a final etiological diagnosis.

Endoscopy of the upper GI tract with biopsies could be considered for further evaluation of the possible chronic enteropathy.

Specific therapy would be dependent on an etiological diagnosis. Symptomatic management of the hepatopathy that can be considered would be the use of Ursodiol with regular monitoring of liver enzyme activity.



PATIENT

Peanut Richartz

SPECIES

Canine

BREED

Terrier Mix

SEX

Neutered male

AGE

13 years

WEIGHT

11 lbs

INTERPRETED BY

Remo Lobetti, BVSc,
MMedVet (Med),
PhD, Dipl. ECVIM

IMAGING PERFORMED BY

Dr. Michael Ferber

HOSPITAL NAME

East Meadow VC

REFERRING VET

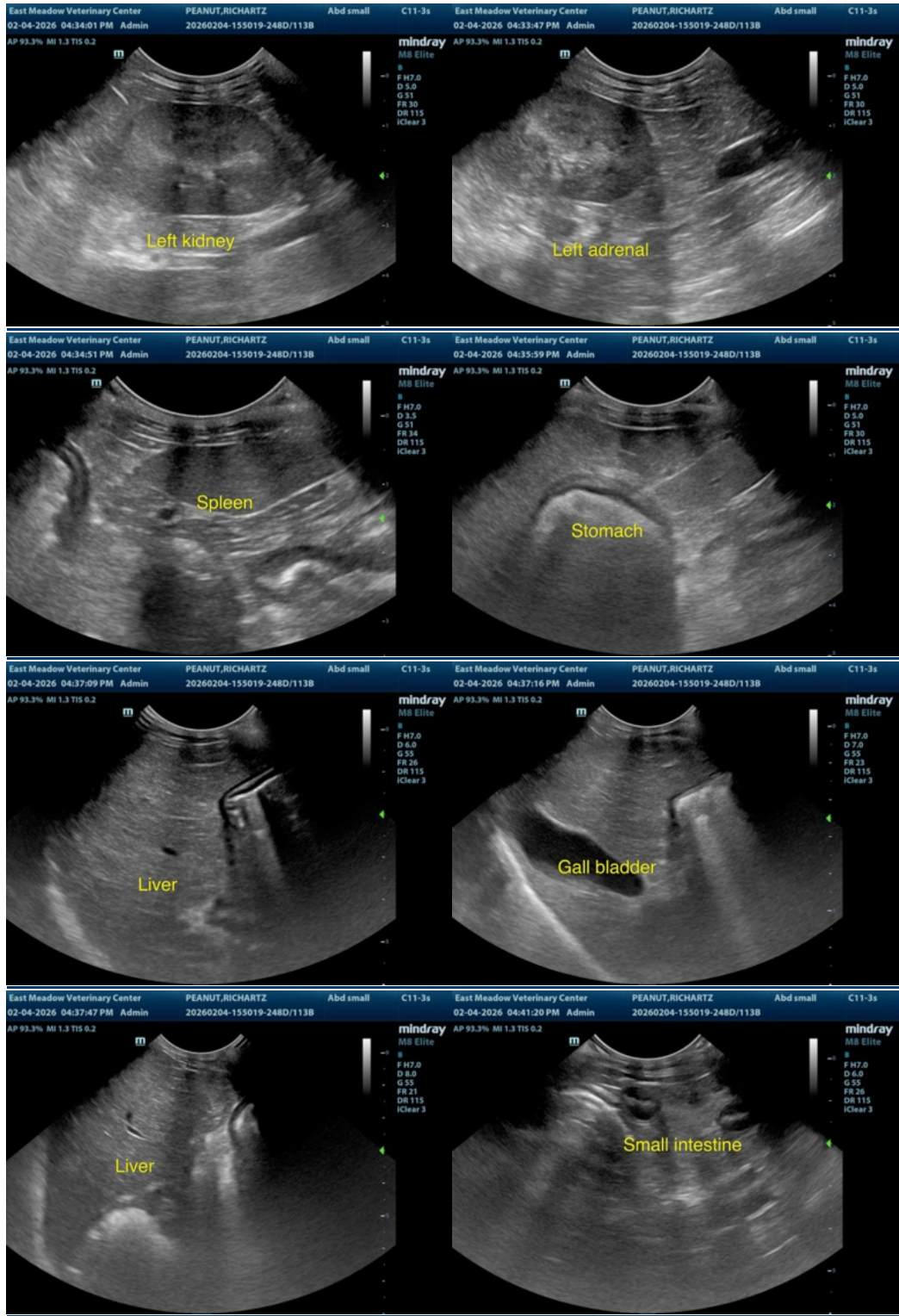
Dr. Ferber

INVOICE

71229

DATE

2/4/26





PATIENT

Peanut Richartz

SPECIES

Canine

BREED

Terrier Mix

SEX

Neutered male

AGE

13 years

WEIGHT

11 lbs

INTERPRETED BY

Remo Lobetti, BVSc,
MMedVet (Med),
PhD, Dipl. ECVIM

IMAGING PERFORMED BY

Dr. Michael Ferber

HOSPITAL NAME

East Meadow VC

REFERRING VET

Dr. Ferber

INVOICE

71229

DATE

2/4/26

The information and recommendations provided are based on the images presented by the referring veterinarian/sonographer. No evaluation can be communicated regarding pathology that was not visible in the image/video clips provided.

Thank you for this referral. If the clinical or image interpretation does not parallel your findings or if I can be of any further assistance please contact me.

Remo Lobetti, BVSc, MMedVet (Med), PhD, Dipl. ECVIM (Internal Medicine)

info@sonopath.com