



## PATIENT

Mindy Coco Mora

## SPECIES

Canine

## BREED

Shih Tzu

## SEX

Spayed female

## AGE

10 years

## WEIGHT

7.5 lbs

## INTERPRETED BY

Remo Lobetti, BVSc,  
MMedVet (Med),  
PhD, Dipl. ECVIM

## IMAGING PERFORMED BY

Dr. Smatt

## HOSPITAL NAME

The Pets I Love

## REFERRING VET

Dr. Smatt

## INVOICE

71210

## DATE

2/4/26

## PRESENTING CLINICAL SIGNS

- Patient came in for routine exam and noticed significant weight loss
- Performed baseline bw.
- 4dx - neg CBC: Lymphocytes - elevated 40% Chem: TP - 7.8 elev Globulin - 4.4 elev AST: 208 ALT: 509 ALP: 468

## ULTRASONOGRAPHIC EXAMINATION OF THE ABDOMEN

### *Urinary System*

The urinary bladder is small with a normal thickness and smooth appearance of the wall. Normal anechoic urine with no sediment or uroliths evident.

Normal appearance of the trigone area, proximal urethra, and iliac blood vessels.

Normal appearance and size of the iliac lymph nodes. Ureters not visualized, which can be considered a normal finding.

Normal renal size (left measured 3.2 cm, right measured 3.0 cm), increased echogenic appearance, some loss of cortico-medullary differentiation and normal pelvis and capsule. No infarcts, mineralization or renoliths evident.

### *Adrenal Glands*

Normal shape, echogenic appearance, size, position, and appearance of the visible peri-adrenal vasculature. Left adrenal gland measured 0.33 cm in width. The right adrenal gland measured 0.38 cm in width.

### *Spleen*

Normal size and echogenic appearance. Smooth homogenous parenchyma and regular curvilinear capsule. Normal volume of the splenic vasculature without any overt congestion or thrombosis evident. No inflammatory, neoplastic, infarction, or infiltrative changes evident. The spleen measured 0.9 cm in width.

### *Liver*

Normal size with a diffuse, mottled echogenic and coarse appearance, normal portal markings, and regular curvilinear capsule. No nodules or masses evident. Normal appearance of the hepatic and portal vasculature.



## PATIENT

Mindy Coco Mora

## SPECIES

Canine

## BREED

Shih Tzu

## SEX

Spayed female

## AGE

10 years

## WEIGHT

7.5 lbs

## INTERPRETED BY

Remo Lobetti, BVSc,  
MMedVet (Med),  
PhD, Dipl. ECVIM

## IMAGING PERFORMED BY

Dr. Smatt

## HOSPITAL NAME

The Pets I Love

## REFERRING VET

Dr. Smatt

## INVOICE

71210

## DATE

2/4/26

## ***Gallbladder***

The gallbladder is full containing normal anechoic bile. Normal thickness and echogenic appearance of the wall. Normal size and appearance of the cystic and common bile duct.

## ***Gastrointestinal***

Normal appearance of the stomach, duodenum, small intestine, ileo-cecal junction, and colon with no loss of layering, 1:3 muscularis to mucosa ratio, normal wall thickness and peristaltic activity, and no distension of the lumen. Small intestine measured up to 0.4 cm.

## ***Pancreas***

The visible sections of the pancreas are of normal size and echogenic appearance with a regular capsule. Normal echogenic appearance of the mesentery and fat surrounding the pancreas.

## ***Free Abdomen***

Normal mesenteric lymph nodes.

No ascites evident.

## **ULTRASONOGRAPHIC FINDINGS**

- Hepatopathy.
- Age related renal changes versus early chronic kidney disease.

## **INTERPRETATION OF THE FINDINGS & FURTHER RECOMMENDATIONS**

Further assessment would be urinalysis and FNA cytology of the liver. A tru cut or wedge biopsy of the liver may be required for a final etiological diagnosis.

Specific therapy would be dependent on an etiological diagnosis.

Symptomatic management that can be considered would be the use of Ursodiol with regular monitoring of liver enzyme activity.



## PATIENT

Mindy Coco Mora

## SPECIES

Canine

## BREED

Shih Tzu

## SEX

Spayed female

## AGE

10 years

## WEIGHT

7.5 lbs

## INTERPRETED BY

Remo Lobetti, BVSc,  
MMedVet (Med),  
PhD, Dipl. ECVIM

## IMAGING PERFORMED BY

Dr. Smatt

## HOSPITAL NAME

The Pets I Love

## REFERRING VET

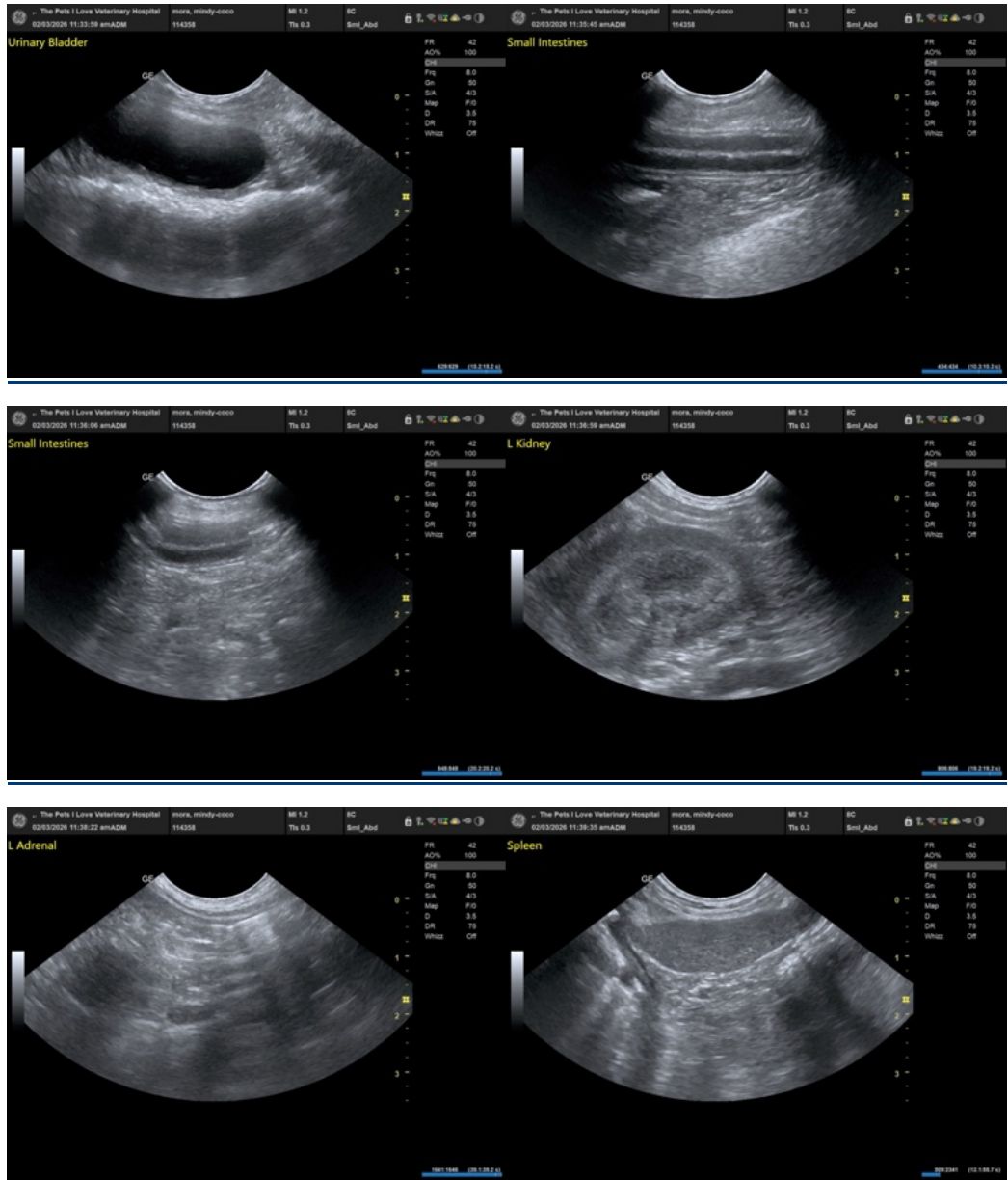
Dr. Smatt

## INVOICE

71210

## DATE

2/4/26





**PATIENT**

Mindy Coco Mora

**SPECIES**

Canine

**BREED**

Shih Tzu

**SEX**

Spayed female

**AGE**

10 years

**WEIGHT**

7.5 lbs

**INTERPRETED BY**

Remo Lobetti, BVSc,  
MMedVet (Med),  
PhD, Dipl. ECVIM

**IMAGING PERFORMED BY**

Dr. Smatt

**HOSPITAL NAME**

The Pets I Love

**REFERRING VET**

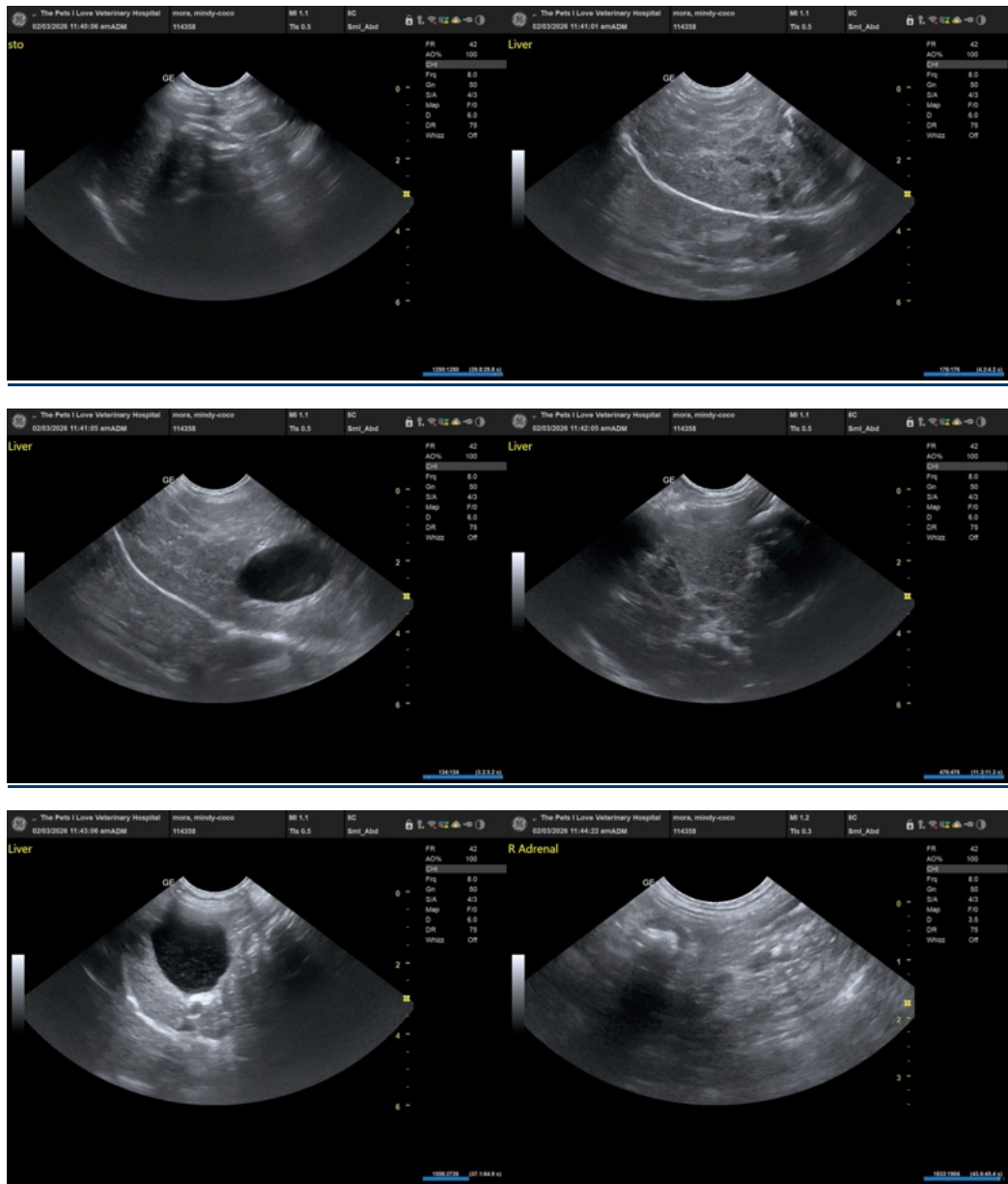
Dr. Smatt

**INVOICE**

71210

**DATE**

2/4/26



The information and recommendations provided are based on the images presented by the referring veterinarian/sonographer. No evaluation can be communicated regarding pathology that was not visible in the image/video clips provided.

Thank you for this referral. If the clinical or image interpretation does not parallel your findings or if I can be of any further assistance please contact me.

Remo Lobetti, BVSc, MMedVet (Med), PhD, Dipl. ECVIM (Internal Medicine)

[info@sonopath.com](mailto:info@sonopath.com)