



## PATIENT

Linus Danielson

## SPECIES

Canine

## BREED

Boston Terrier

## SEX

Neutered male

## AGE

9 years

## WEIGHT

27.6 lbs

## INTERPRETED BY

Remo Lobetti, BVSc,  
MMedVet (Med),  
PhD, Dipl. ECVIM

## IMAGING PERFORMED BY

Eric Randall, DVM

## HOSPITAL NAME

Petroglyph AH

## REFERRING VET

Dr. Whitney Jones

## INVOICE

71240

## DATE

2/4/26

## PRESENTING CLINICAL SIGNS

- 2-3 week history of chronic vomiting. No improvement with diet change. No history of foreign body ingestion

## ULTRASONOGRAPHIC EXAMINATION OF THE ABDOMEN

### *Urinary System*

The urinary bladder is full with a normal thickness and smooth appearance of the wall. Normal anechoic urine with no sediment or uroliths evident.

Normal appearance of the trigone area, proximal urethra, and iliac blood vessels.

Normal appearance and size of the iliac lymph nodes. Ureters not visualized, which can be considered a normal finding.

Normal renal size (left measured 4.4 cm, right measured 4.5 cm), architecture, echogenic appearance, cortico-medullary differentiation, which maintains a 1:3 cortex to medulla ratio, pelvis, and capsule. No infarcts, mineralization or renoliths evident. Normal color flow pattern is evident in both kidneys.

The prostate is small and hypoechogenic.

### *Adrenal Glands*

Normal shape, echogenic appearance, size, position, and appearance of the visible peri-adrenal vasculature. Left adrenal gland measured 0.45 cm in width. The right adrenal gland measured 0.53 cm in width.

### *Spleen*

Normal size and echogenic appearance. Smooth homogenous parenchyma and regular curvilinear capsule. Normal volume of the splenic vasculature without any overt congestion or thrombosis evident. No inflammatory, neoplastic, infarction, or infiltrative changes evident. The spleen measured 1.2 cm in width.

### *Liver*

Normal size, echogenic appearance, portal markings, and regular curvilinear capsule. No nodules or masses evident. Normal appearance of the hepatic and portal vasculature.

### *Gallbladder*

The gallbladder is full containing a moderate amount of non-adhered, hyperechogenic sediment. Normal thickness and echogenic appearance of the wall. Normal size and appearance of the cystic and common bile duct.



## PATIENT

Linus Danielson

## SPECIES

Canine

## BREED

Boston Terrier

## SEX

Neutered male

## AGE

9 years

## WEIGHT

27.6 lbs

## INTERPRETED BY

Remo Lobetti, BVSc,  
MMedVet (Med),  
PhD, Dipl. ECVIM

## IMAGING PERFORMED BY

Eric Randall, DVM

## HOSPITAL NAME

Petroglyph AH

## REFERRING VET

Dr. Whitney Jones

## INVOICE

71240

## DATE

2/4/26

## *Gastrointestinal*

Normal appearance of the stomach, duodenum, small intestine, ileo-cecal junction, and colon with no loss of layering, 1:3 muscularis to mucosa ratio, normal wall thickness and peristaltic activity, and no distension of the lumen.

## *Pancreas*

The pancreas is not clearly visualized, but the visible sections of the pancreas are of normal size and echogenic appearance with a regular capsule. Normal echogenic appearance of the mesentery and fat surrounding the pancreas.

## *Free Abdomen*

Normal mesenteric lymph nodes.

No ascites evident.

## ULTRASONOGRAPHIC FINDINGS

- Gallbladder sediment.

## INTERPRETATION OF THE FINDINGS & FURTHER RECOMMENDATIONS

In essence this is a normal ultrasound examination of the abdomen as gallbladder sediment can be considered an incidental finding.

On this ultrasound there is no obvious etiology for the chronic vomiting.

Although the stomach appears ultrasonographically normal, with the chronic vomiting, etiologies to consider would be chronic gastritis, Helicobacter gastritis, parasitic gastroenteritis, ulcerative disease, dietary hypersensitivity and inflammatory bowel disease.

Further assessment would be fecal analysis, cobalamin and folate assay and endoscopy of the upper GI tract with biopsies.

Specific therapy would be dependent on an etiological diagnosis.

Symptomatic management that can be considered would be feeding small frequent meals of a novel protein/hypoallergenic diet, course of Fenbendazole, cobalamin supplementation and gastric protectants (Omeprazole, Sucralfate). If there is not a satisfactory improvement then triple therapy for helicobacter gastritis should be considered and if there is still not a satisfactory improvement then a course of Prednisolone would then be indicated.



**PATIENT**

Linus Danielson

**SPECIES**

Canine

**BREED**

Boston Terrier

**SEX**

Neutered male

**AGE**

9 years

**WEIGHT**

27.6 lbs

**INTERPRETED BY**

Remo Lobetti, BVSc,  
MMedVet (Med),  
PhD, Dipl. ECVIM

**IMAGING PERFORMED BY**

Eric Randall, DVM

**HOSPITAL NAME**

Petroglyph AH

**REFERRING VET**

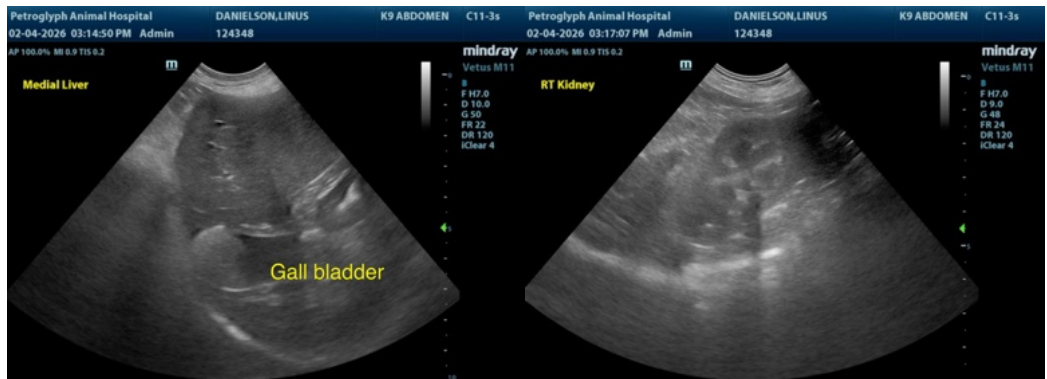
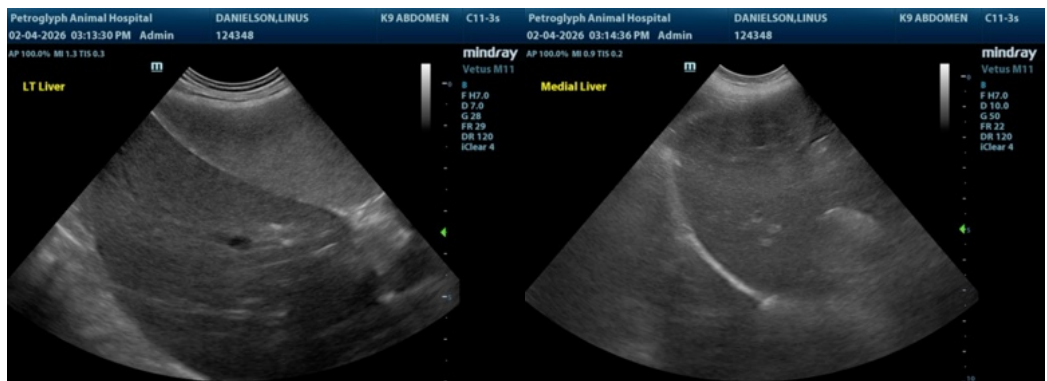
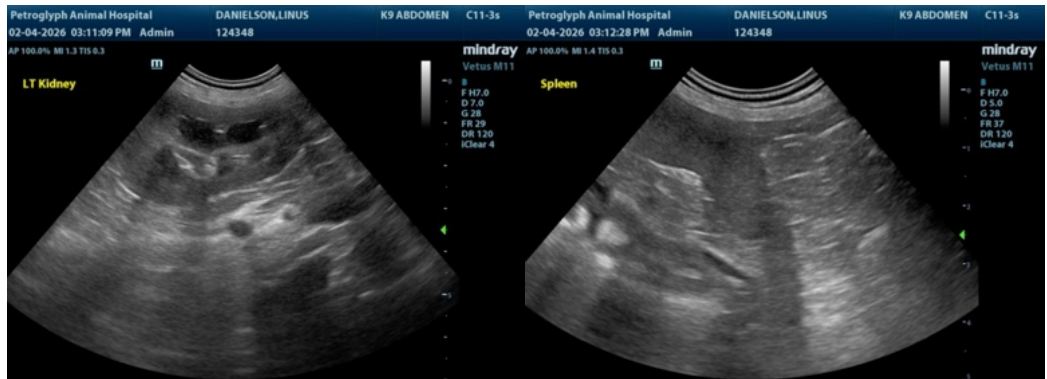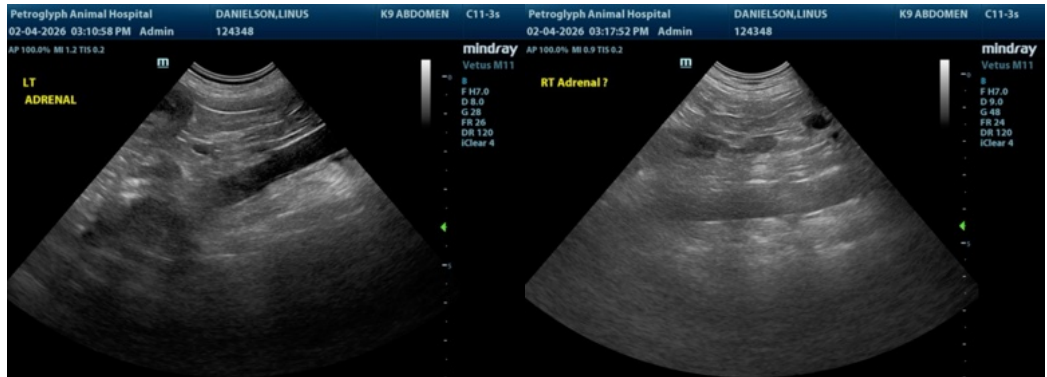Dr. Whitney Jones

**INVOICE**

71240

**DATE**

2/4/26





## PATIENT

Linus Danielson

## SPECIES

Canine

## BREED

Boston Terrier

## SEX

Neutered male

## AGE

9 years

## WEIGHT

27.6 lbs

## INTERPRETED BY

Remo Lobetti, BVSc,  
MMedVet (Med),  
PhD, Dipl. ECVIM

## IMAGING PERFORMED BY

Eric Randall, DVM

## HOSPITAL NAME

Petroglyph AH

## REFERRING VET

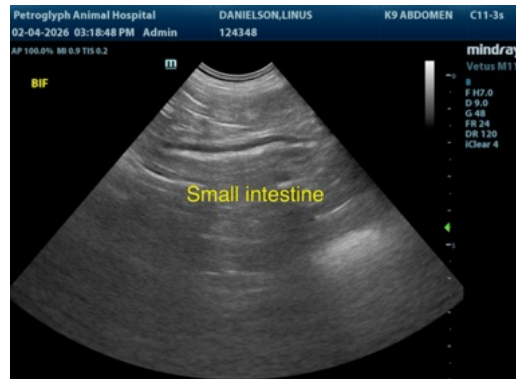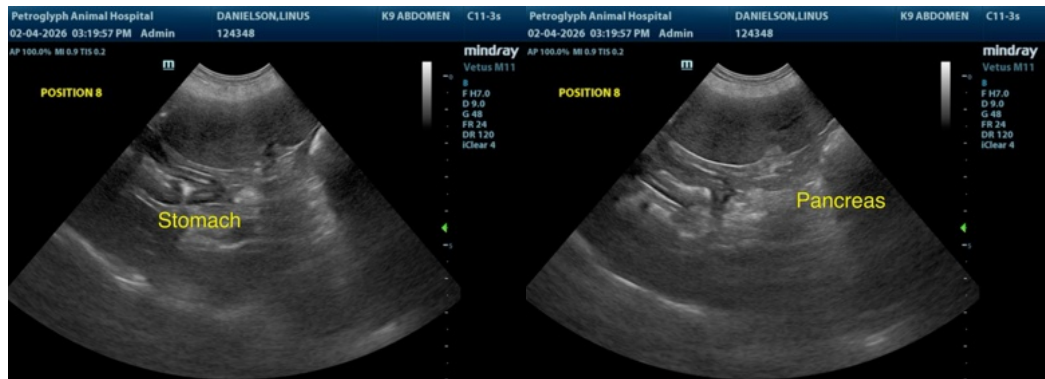
Dr. Whitney Jones

## INVOICE

71240

## DATE

2/4/26



The information and recommendations provided are based on the images presented by the referring veterinarian/sonographer. No evaluation can be communicated regarding pathology that was not visible in the image/video clips provided.

Thank you for this referral. If the clinical or image interpretation does not parallel your findings or if I can be of any further assistance please contact me.

Remo Lobetti, BVSc, MMedVet (Med), PhD, Dipl. ECVIM (Internal Medicine)

[info@sonopath.com](mailto:info@sonopath.com)