



PATIENT

Jacob Fight Hall

SPECIES

Canine

BREED

Golden

SEX

Neutered male

AGE

6 years

WEIGHT

80.6 lbs

INTERPRETED BY

Remo Lobetti, BVSc,
MMedVet (Med),
PhD, Dipl. ECVIM

IMAGING PERFORMED BY

Celene Hendricks

HOSPITAL NAME

Grove Small AH

REFERRING VET

Dr. Hendricks

INVOICE

71232

DATE

2/4/26

PRESENTING CLINICAL SIGNS

- Losing weight without increase in activity or decrease in food intake. Increased food and did not see an increase in weight. Texas GI panel pending
- Neutrophils 57 (60-77)% lymph 36 (12-30)% AST 13 (15-66) ALT 11 (12-118) CPK 47 (59-895)

ULTRASONOGRAPHIC EXAMINATION OF THE ABDOMEN

Urinary System

The urinary bladder is small with a normal thickness and smooth appearance of the wall. Normal anechoic urine with no sediment or uroliths evident.

Normal appearance of the trigone area, proximal urethra, and iliac blood vessels.

Normal appearance and size of the iliac lymph nodes. Ureters not visualized, which can be considered a normal finding.

Normal renal size (left measured 5.5 cm), architecture, echogenic appearance, cortico-medullary differentiation, which maintains a 1:3 cortex to medulla ratio, pelvis, and capsule. No infarcts, mineralization or renoliths evident. The right kidney was not visualized.

Adrenal Glands

The left adrenal gland poorly visualized, but appears to be of normal shape, echogenic appearance and size. The right adrenal gland was not visualized.

Spleen

Normal size and echogenic appearance. Smooth homogenous parenchyma and regular curvilinear capsule. Normal volume of the splenic vasculature without any overt congestion or thrombosis evident. No inflammatory, neoplastic, infarction, or infiltrative changes evident. The spleen measured 2.4 cm in width.

Liver

Normal size, echogenic appearance, portal markings, and regular curvilinear capsule. No nodules or masses evident. Normal appearance of the hepatic and portal vasculature.

Gallbladder

The gallbladder is full containing a small amount of non-adhered hyperechogenic sediment. Normal thickness and echogenic appearance of the wall. Normal size and appearance of the cystic and common bile duct.



PATIENT

Jacob Fight Hall

SPECIES

Canine

BREED

Golden

SEX

Neutered male

AGE

6 years

WEIGHT

80.6 lbs

INTERPRETED BY

Remo Lobetti, BVSc,
MMedVet (Med),
PhD, Dipl. ECVIM

IMAGING PERFORMED BY

Celene Hendricks

HOSPITAL NAME

Grove Small AH

REFERRING VET

Dr. Hendricks

INVOICE

71232

DATE

2/4/26

Gastrointestinal

Normal appearance of the stomach, duodenum, small intestine, ileo-cecal junction, and colon with no loss of layering, 1:3 muscularis to mucosa ratio, normal wall thickness and peristaltic activity, and no distension of the lumen. A large amount of ingesta is present within the stomach compatible with a recent meal.

Pancreas

The visible sections of the pancreas are of normal size and echogenic appearance with a regular capsule. Normal echogenic appearance of the mesentery and fat surrounding the pancreas.

Free Abdomen

Normal mesenteric lymph nodes.

No ascites evident.

ULTRASONOGRAPHIC FINDINGS

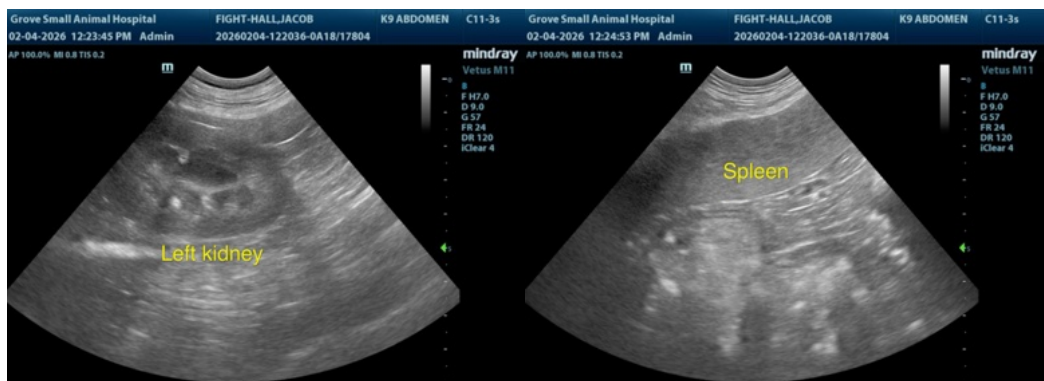- Gallbladder sediment.

INTERPRETATION OF THE FINDINGS & FURTHER RECOMMENDATIONS

In essence a normal ultrasound examination of the abdomen as the gallbladder sediment can be considered an incidental finding.

Further assessment would be based on the pending results but could include fecal analysis and endoscopy of the upper GI tract with biopsies.

Specific therapy would be dependent on an etiological diagnosis.





PATIENT

Jacob Fight Hall

SPECIES

Canine

BREED

Golden

SEX

Neutered male

AGE

6 years

WEIGHT

80.6 lbs

INTERPRETED BY

Remo Lobetti, BVSc,
MMedVet (Med),
PhD, Dipl. ECVIM

IMAGING PERFORMED BY

Celene Hendricks

HOSPITAL NAME

Grove Small AH

REFERRING VET

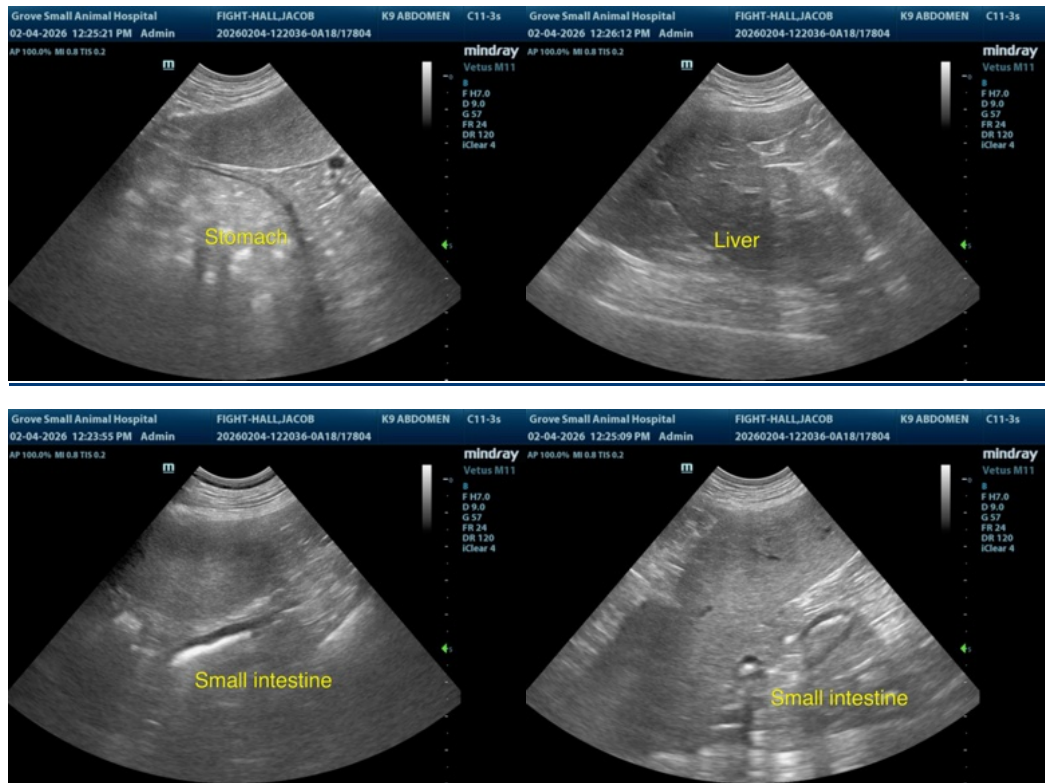
Dr. Hendricks

INVOICE

71232

DATE

2/4/26



The information and recommendations provided are based on the images presented by the referring veterinarian/sonographer. No evaluation can be communicated regarding pathology that was not visible in the image/video clips provided.

Thank you for this referral. If the clinical or image interpretation does not parallel your findings or if I can be of any further assistance please contact me.

Remo Lobetti, BVSc, MMedVet (Med), PhD, Dipl. ECVIM (Internal Medicine)

info@sonopath.com