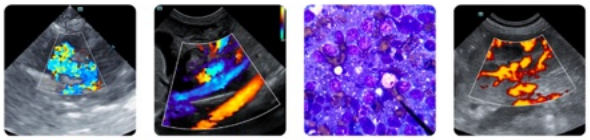

PATIENT
Sadie Lynch

SPECIES
Canine

BREED
Golden Doodle

SEX
Spayed female

AGE
10 years

WEIGHT
lbs

INTERPRETED BY
Remo Lobetti, BVSc, MMedVet (Med), PhD, Dipl. ECVIM

IMAGING PERFORMED BY
Dr. Gillian Striano-Kaplan

HOSPITAL NAME
Ramsey VH

REFERRING VET
Dr. Kaplan

INVOICE
71168

DATE
2/3/26

PRESENTING CLINICAL SIGNS

- History of intermittent vomiting and PU/PD on Metronidazole 100mg/mL 0.5mL PO BID, Omeprazole 5mg BID, worsening liver values
- hx of CKD
- * H/O Liver shunt
- Labs-12/19/25-T4 0.8, Sodium 153, Albumin 2.6, ALT 452, AST 166, ALP 172, RBC 9.43, MCV 50, MCH 16.4, Retic HGB 18.0, Monocyte 1132, RDW 21.2, USG 1.006

ULTRASONOGRAPHIC EXAMINATION OF THE ABDOMEN

Urinary System

The urinary bladder is full with a normal thickness and smooth appearance of the wall. A small amount of floating, hyperechogenic sediment.

Normal appearance of the trigone area, proximal urethra, and iliac blood vessels.

Normal appearance and size of the iliac lymph nodes. Ureters not visualized, which can be considered a normal finding.

Normal renal size (left measured 4.3 cm, right measured 4.3 cm), increased echogenic appearance, some loss of cortico-medullary differentiation, and normal pelvis and capsule. No infarcts, mineralization or renoliths evident.

Adrenal Glands

The left adrenal gland was poorly visualized, but appears to be of normal shape, echogenic appearance and size. The right adrenal gland was not visualized.

Spleen

Normal size and echogenic appearance. Smooth homogenous parenchyma and regular curvilinear capsule. Normal volume of the splenic vasculature without any overt congestion or thrombosis evident. No inflammatory, neoplastic, infarction, or infiltrative changes evident. The spleen measured 1.0 cm in width.

Liver

The liver is small in size with a diffuse, increased echogenic and coarse appearance, normal portal markings, and regular curvilinear capsule. No nodules or masses evident. Normal appearance of the hepatic and portal vasculature.

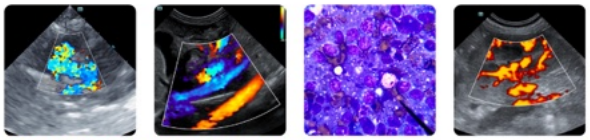

PATIENT
Sadie Lynch

SPECIES
Canine

BREED
Golden Doodle

SEX
Spayed female

AGE
10 years

WEIGHT
lbs

INTERPRETED BY
Remo Lobetti, BVSc, MMedVet (Med), PhD, Dipl. ECVIM

IMAGING PERFORMED BY
Dr. Gillian Striano-Kaplan

HOSPITAL NAME
Ramsey VH

REFERRING VET
Dr. Kaplan

INVOICE
71168

DATE
2/3/26

Gallbladder

The gallbladder is full containing a small amount of non-adhered, hyperechogenic sediment. Normal thickness and echogenic appearance of the wall. Normal size and appearance of the cystic and common bile duct.

Gastrointestinal

Normal appearance of the stomach, duodenum, small intestine, ileo-cecal junction, and colon with no loss of layering, 1:3 muscularis to mucosa ratio, normal wall thickness and peristaltic activity, and no distension of the lumen.

Pancreas

The visible sections of the pancreas are of normal size and echogenic appearance with a regular capsule. Normal echogenic appearance of the mesentery and fat surrounding the pancreas.

Free Abdomen

Normal mesenteric lymph nodes.

No ascites evident.

ULTRASONOGRAPHIC FINDINGS

- Hepatopathy.
- Gallbladder sediment.
- Urinary bladder sediment.
- Age related renal changes versus early chronic kidney disease.

INTERPRETATION OF THE FINDINGS & FURTHER RECOMMENDATIONS

Although the most likely etiology for the hepatopathy would be secondary to the liver shunt, reactive hyperplasia, vacuolar and metabolic hepatopathy should still be considered. Hepatitis and infiltrative neoplasia would be an unlikely differential diagnosis.

Etiologies for the urinary bladder sediment would be incidental debris, crystalluria and possibly bacterial cystitis.

The gallbladder sediment can be considered an incidental finding.

Further assessment would be urinalysis, possibly urine culture, pre and post prandial bile acids and FNA cytology of the liver.

A tru cut or wedge biopsy of the liver may be required for a final etiological diagnosis.

PATIENT

Sadie Lynch

SPECIES

Canine

BREED

Golden Doodle

SEX

Spayed female

AGE

10 years

WEIGHT

lbs

INTERPRETED BY

Remo Lobetti, BVSc, MMedVet (Med), PhD, Dipl. ECVIM

IMAGING PERFORMED BY

Dr. Gillian Striano-Kaplan

HOSPITAL NAME

Ramsey VH

REFERRING VET

Dr. Kaplan

INVOICE

71168

DATE

2/3/26

Specific therapy would be dependent on an etiological diagnosis.

Symptomatic management that can be considered for both the hepatopathy and the gallbladder sediment would be the use of Ursodiol with regular monitoring of liver enzyme activity.

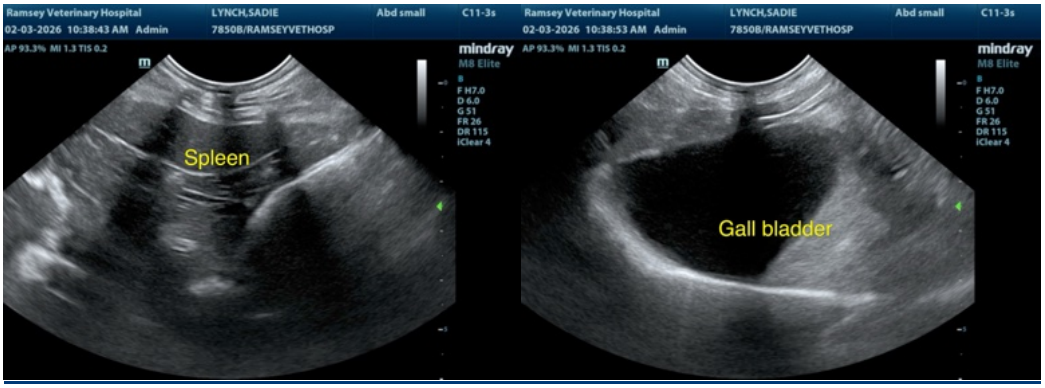

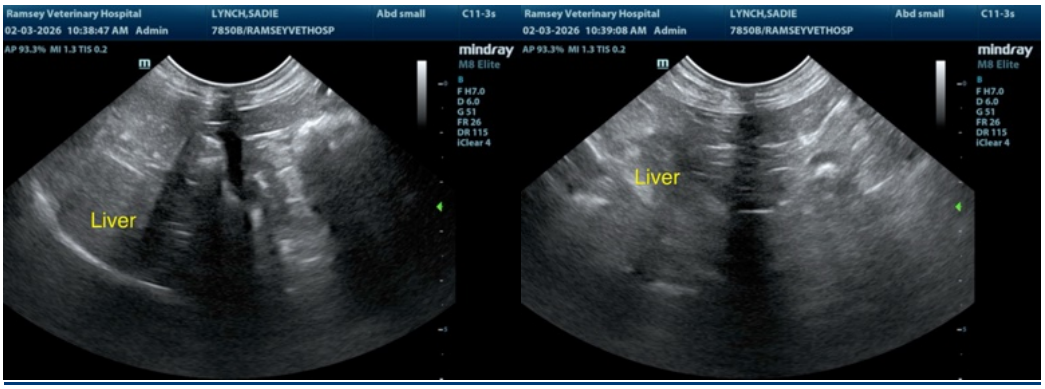

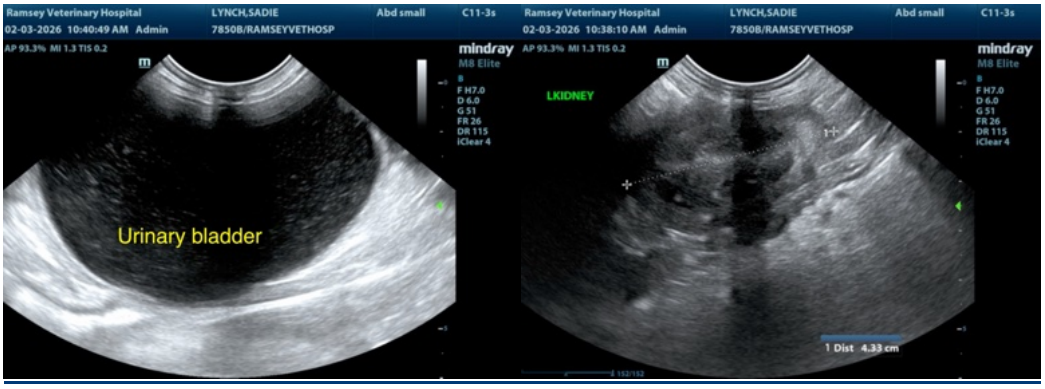

SonoPath
FOSTERING THE ART OF VETERINARY MEDICINE™

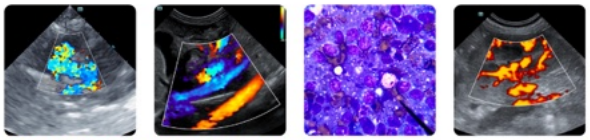

Clinical Sonography & Telecytology
Educational Teleconsultation Services™

SonoPath.com info@sonopath.com 1.800.838.4268

PATIENT

Sadie Lynch

SPECIES

Canine

BREED

Golden Doodle

SEX

Spayed female

AGE

10 years

WEIGHT

lbs

INTERPRETED BY

Remo Lobetti, BVSc, MMedVet (Med), PhD, Dipl. ECVIM

IMAGING PERFORMED BY

Dr. Gillian Striano-Kaplan

HOSPITAL NAME

Ramsey VH

REFERRING VET

Dr. Kaplan

INVOICE

71168

DATE

2/3/26

The information and recommendations provided are based on the images presented by the referring veterinarian/sonographer. No evaluation can be communicated regarding pathology that was not visible in the image/video clips provided.

Thank you for this referral. If the clinical or image interpretation does not parallel your findings or if I can be of any further assistance please contact me.

Remo Lobetti, BVSc, MMedVet (Med), PhD, Dipl. ECVIM (Internal Medicine)

info@sonopath.com