



PATIENT

Albert McElwain

SPECIES

Canine

BREED

Mix

SEX

Spayed female

AGE

9 years

WEIGHT

37.3 lbs

INTERPRETED BY

Remo Lobetti, BVSc,
MMedVet (Med),
PhD, Dipl. ECVIM

IMAGING PERFORMED BY

Dr. Scott

HOSPITAL NAME

Wyckoff VH

REFERRING VET

Dr. Scott

INVOICE

71201

DATE

2/3/26

PRESENTING CLINICAL SIGNS

- Up and down vomiting/diarrhea for the last week - sometimes the vomit is bile and sometimes its food. Diarrhea- colitis signs
- PE WNL- slight weight loss CBC/chem pending

ULTRASONOGRAPHIC EXAMINATION OF THE ABDOMEN

Urinary System

The urinary bladder is small with a normal thickness and smooth appearance of the wall. Normal anechoic urine with no sediment or uroliths evident.

Normal appearance of the trigone area, proximal urethra, and iliac blood vessels.

Normal appearance and size of the iliac lymph nodes. Ureters not visualized, which can be considered a normal finding.

Normal renal size (left measured 5.1 cm, right measured 5.0 cm), architecture, echogenic appearance, cortico-medullary differentiation, which maintains a 1:3 cortex to medulla ratio, pelvis, and capsule. No infarcts, mineralization or renoliths evident.

Adrenal Glands

Normal shape, echogenic appearance, size, position, and appearance of the visible peri-adrenal vasculature. Left adrenal gland measured 0.57 cm and 0.46 cm in width. The right adrenal gland measured 0.45 cm in width.

Spleen

Normal size and echogenic appearance. Smooth homogenous parenchyma and regular curvilinear capsule. Normal volume of the splenic vasculature without any overt congestion or thrombosis evident. No inflammatory, neoplastic, infarction, or infiltrative changes evident. The spleen measured 2.6 cm in width.

Liver

Normal size, echogenic appearance, portal markings, and regular curvilinear capsule. No nodules or masses evident. Normal appearance of the hepatic and portal vasculature.

Gallbladder

The gallbladder is full containing a small amount of non-adhered, hyperechogenic sediment. Normal thickness and echogenic appearance of the wall. Normal size and appearance of the cystic and common bile duct.



PATIENT

Albert McElwain

SPECIES

Canine

BREED

Mix

SEX

Spayed female

AGE

9 years

WEIGHT

37.3 lbs

INTERPRETED BY

Remo Lobetti, BVSc,
MMedVet (Med),
PhD, Dipl. ECVIM

IMAGING PERFORMED BY

Dr. Scott

HOSPITAL NAME

Wyckoff VH

REFERRING VET

Dr. Scott

INVOICE

71201

DATE

2/3/26

Gastrointestinal

Normal appearance of the stomach, duodenum, small intestine, ileo-cecal junction, and colon with no loss of layering, 1:3 muscularis to mucosa ratio, normal wall thickness and peristaltic activity, and no distension of the lumen. A moderate amount of ingesta is present within the stomach compatible with a recent meal.

Pancreas

The visible sections of the pancreas are of normal size and echogenic appearance with a regular capsule. Normal echogenic appearance of the mesentery and fat surrounding the pancreas.

Free Abdomen

Normal mesenteric lymph nodes.

No ascites evident.

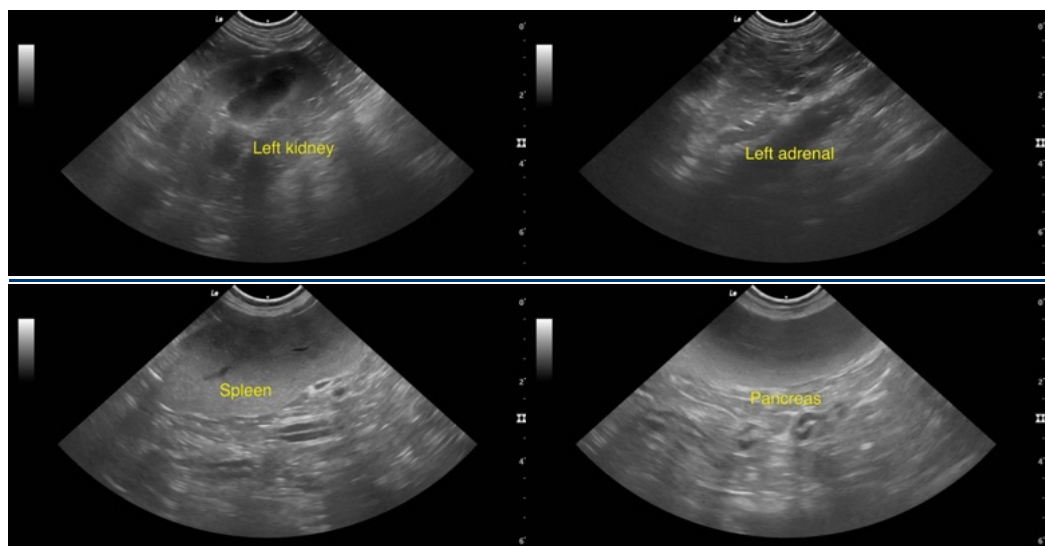
ULTRASONOGRAPHIC FINDINGS

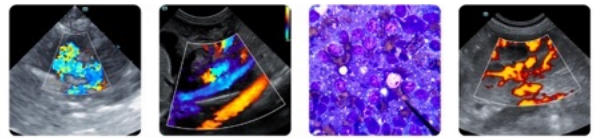
- Gallbladder sediment.

INTERPRETATION OF THE FINDINGS & FURTHER RECOMMENDATIONS

In essence a normal ultrasound examination of the abdomen with no obvious etiology for the presenting clinical signs.

Further assessment and therapy needs to be based on the pending results, but could include fecal analysis and a GI panel.





PATIENT

Albert McElwain

SPECIES

Canine

BREED

Mix

SEX

Spayed female

AGE

9 years

WEIGHT

37.3 lbs

INTERPRETED BY

Remo Lobetti, BVSc,
MMedVet (Med),
PhD, Dipl. ECVIM

IMAGING PERFORMED BY

Dr. Scott

HOSPITAL NAME

Wyckoff VH

REFERRING VET

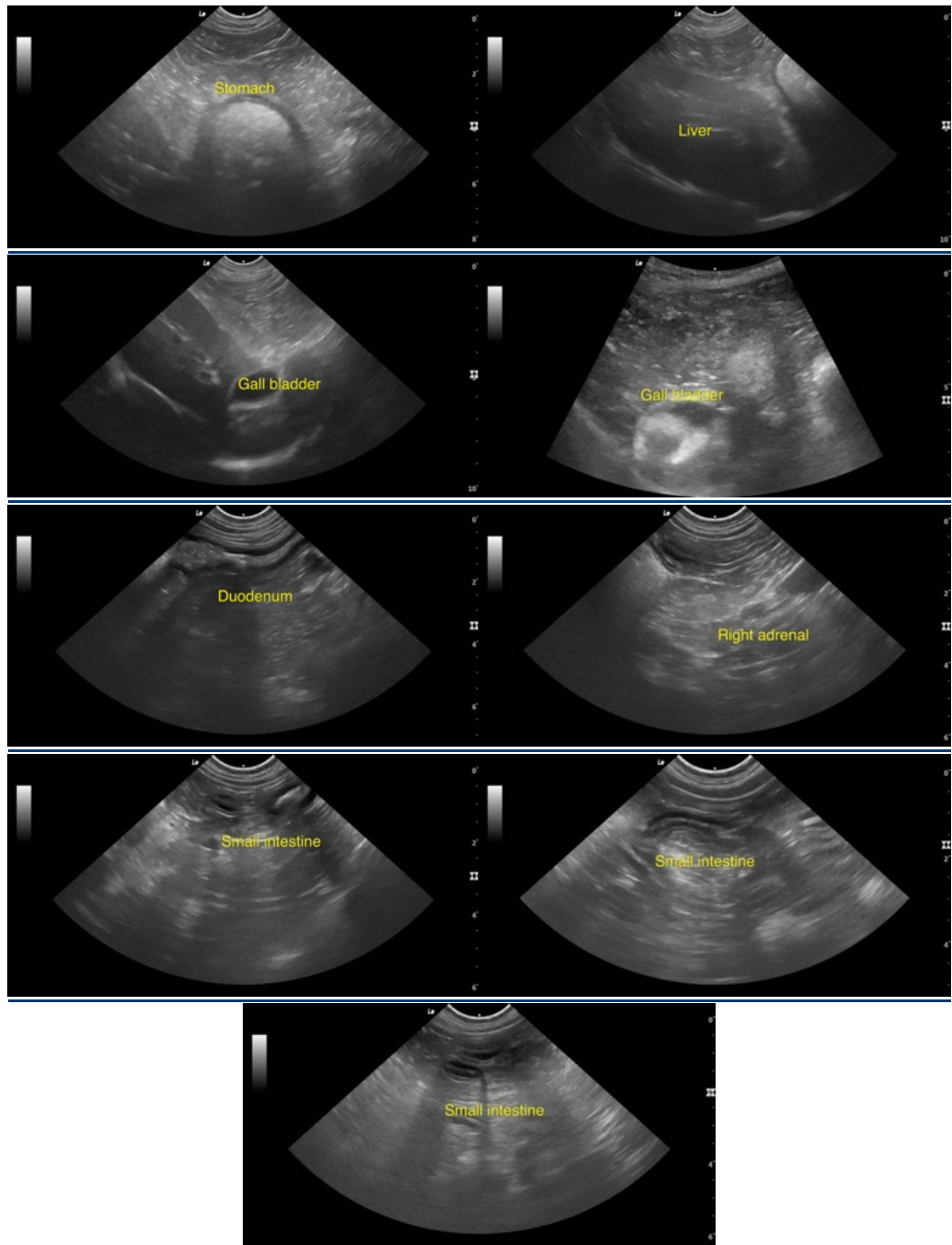
Dr. Scott

INVOICE

71201

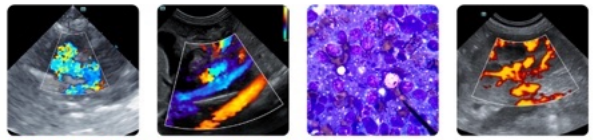
DATE

2/3/26



The information and recommendations provided are based on the images presented by the referring veterinarian/sonographer. No evaluation can be communicated regarding pathology that was not visible in the image/video clips provided.

Thank you for this referral. If the clinical or image interpretation does not parallel your findings or if I can be of any further assistance please contact me.



PATIENT

Albert McElwain

Remo Lobetti, BVSc, MMedVet (Med), PhD, Dipl. ECVIM (Internal Medicine)

info@sonopath.com

SPECIES

Canine

BREED

Mix

SEX

Spayed female

AGE

9 years

WEIGHT

37.3 lbs

INTERPRETED BY

Remo Lobetti, BVSc,
MMedVet (Med),
PhD, Dipl. ECVIM

IMAGING PERFORMED BY

Dr. Scott

HOSPITAL NAME

Wyckoff VH

REFERRING VET

Dr. Scott

INVOICE

71201

DATE

2/3/26