



PATIENT

Jerry Rattanni

SPECIES

Canine

BREED

Chihuahua Mix

SEX

Neutered male

AGE

5 years

WEIGHT

16.8 lbs

INTERPRETED BY

Remo Lobetti, BVSc,
MMedVet (Med),
PhD, Dipl. ECVIM

IMAGING PERFORMED BY

Dr. Brandon Holmes

HOSPITAL NAME

West Newton AC

REFERRING VET

Dr. Hofmeister/Dr.
Holmes

INVOICE

72001

DATE

2/26/26

PRESENTING CLINICAL SIGNS

- The primary concern is weight gain; he is now almost 17 pounds, which the owner finds excessive for his diet. Jerry has a history of seizure-like episodes which have completely resolved since his diet was changed from a high-calorie food to the current prescription diet (Hill's z/d) approximately two months ago. Bloodwork from December 2025 revealed elevated bile acids, and an abdominal ultrasound was recommended at that time.

ULTRASONOGRAPHIC EXAMINATION OF THE ABDOMEN

Urinary System

The urinary bladder is small almost empty with a normal thickness and smooth appearance of the wall. Normal anechoic urine with no sediment or uroliths evident.

Normal appearance of the trigone area, proximal urethra, and iliac blood vessels.

Normal appearance and size of the iliac lymph nodes. Ureters not visualized, which can be considered a normal finding.

Normal renal size (left measured 4.2 cm, right measured 4.1 cm), architecture, echogenic appearance, cortico-medullary differentiation, which maintains a 1:3 cortex to medulla ratio, pelvis, and capsule. No infarcts, mineralization or renoliths evident. Normal color flow pattern is evident in both kidneys.

The prostate is small and hypoechogenic measuring 0.7 cm in width.

Adrenal Glands

Normal shape, echogenic appearance, size, position, and appearance of the visible peri-adrenal vasculature. Left adrenal gland measured 1.77 cm in length x 0.67 cm in width. The right adrenal gland measured 1.19 cm in length x 0.43 cm in width.

Spleen

Normal size and echogenic appearance. Smooth homogenous parenchyma and regular curvilinear capsule. Normal volume of the splenic vasculature without any overt congestion or thrombosis evident. No inflammatory, neoplastic, infarction, or infiltrative changes evident. The spleen measured 1.5 cm in width.

Liver

Normal size, echogenic appearance, portal markings, and regular curvilinear capsule. No nodules or masses evident. Normal appearance of the hepatic and portal vasculature.



PATIENT

Jerry Rattanni

SPECIES

Canine

BREED

Chihuahua Mix

SEX

Neutered male

AGE

5 years

WEIGHT

16.8 lbs

INTERPRETED BY

Remo Lobetti, BVSc,
MMedVet (Med),
PhD, Dipl. ECVIM

IMAGING PERFORMED BY

Dr. Brandon Holmes

HOSPITAL NAME

West Newton AC

REFERRING VET

Dr. Hofmeister/Dr.
Holmes

INVOICE

72001

DATE

2/26/26

Gallbladder

The gallbladder is full containing a small amount of non-adhered hyperechogenic sediment. Normal thickness and echogenic appearance of the wall. Normal size and appearance of the cystic and common bile duct.

Gastrointestinal

Normal appearance of the stomach, duodenum, small intestine, ileo-cecal junction, and colon with no loss of layering, 1:3 muscularis to mucosa ratio, normal wall thickness and peristaltic activity, and no distension of the lumen.

Pancreas

The visible sections of the pancreas are of normal size and echogenic appearance with a regular capsule. Normal echogenic appearance of the mesentery and fat surrounding the pancreas.

Free Abdomen

Normal mesenteric lymph nodes.

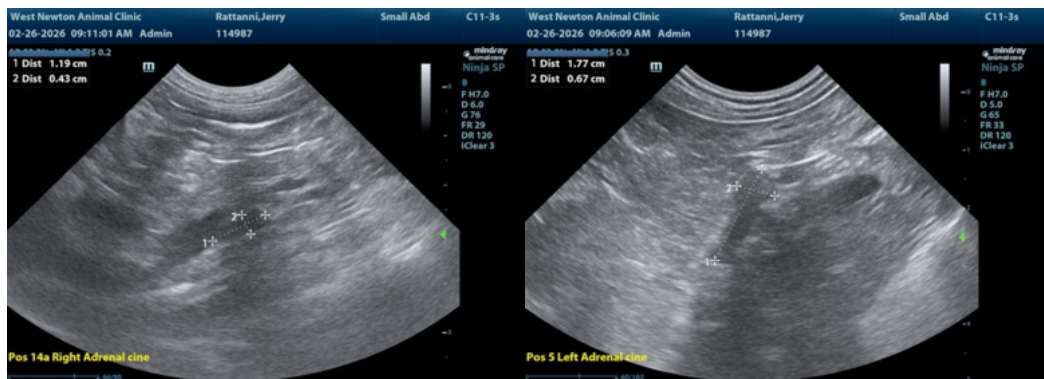
No ascites evident.

ULTRASONOGRAPHIC FINDINGS

- Gallbladder sediment.

INTERPRETATION OF THE FINDINGS & FURTHER RECOMMENDATIONS

In essence this is a normal ultrasound examination of the abdomen as the gallbladder sediment can be considered an incidental finding.





PATIENT

Jerry Rattanni

SPECIES

Canine

BREED

Chihuahua Mix

SEX

Neutered male

AGE

5 years

WEIGHT

16.8 lbs

INTERPRETED BY

Remo Lobetti, BVSc,
MMedVet (Med),
PhD, Dipl. ECVIM

IMAGING PERFORMED BY

Dr. Brandon Holmes

HOSPITAL NAME

West Newton AC

REFERRING VET

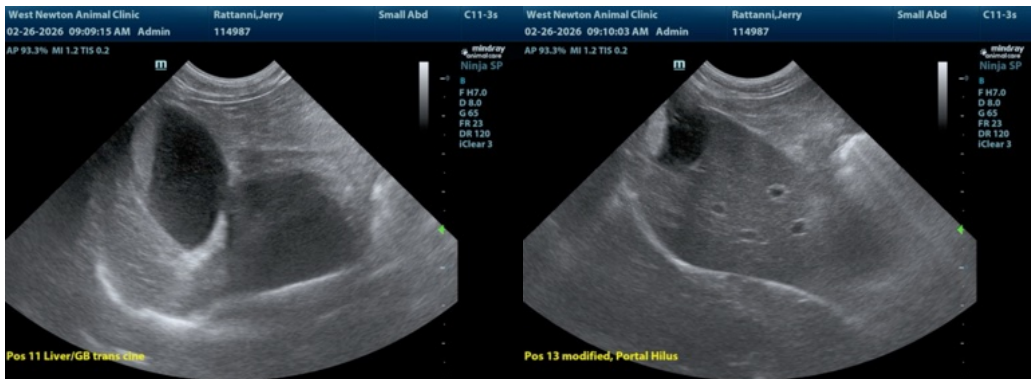
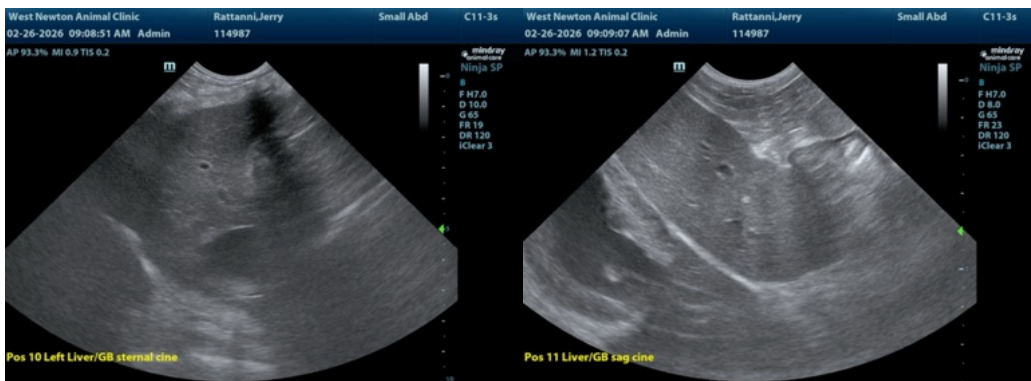
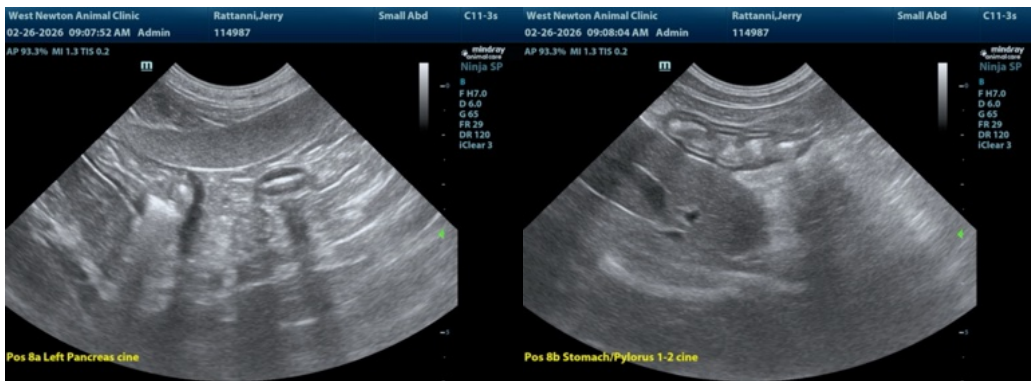
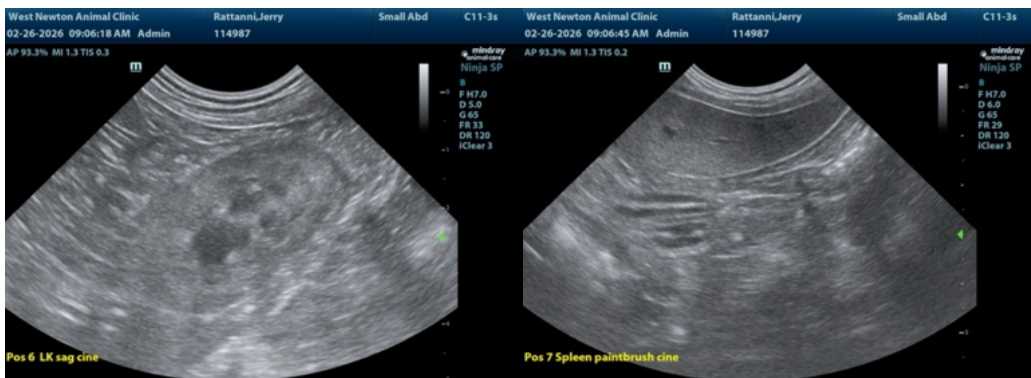
Dr. Hofmeister/Dr.
Holmes

INVOICE

72001

DATE

2/26/26





PATIENT

Jerry Rattanni

SPECIES

Canine

BREED

Chihuahua Mix

SEX

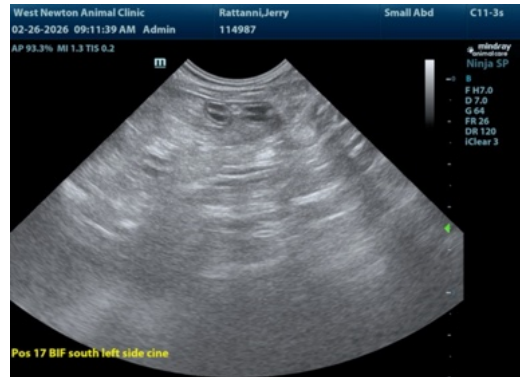Neutered male

AGE

5 years

WEIGHT

16.8 lbs



The information and recommendations provided are based on the images presented by the referring veterinarian/sonographer. No evaluation can be communicated regarding pathology that was not visible in the image/video clips provided.

Thank you for this referral. If the clinical or image interpretation does not parallel your findings or if I can be of any further assistance please contact me.

Remo Lobetti, BVSc, MMedVet (Med), PhD, Dipl. ECVIM (Internal Medicine)

info@sonopath.com

INTERPRETED BY

Remo Lobetti, BVSc,
MMedVet (Med),
PhD, Dipl. ECVIM

IMAGING PERFORMED BY

Dr. Brandon Holmes

HOSPITAL NAME

West Newton AC

REFERRING VET

Dr. Hofmeister/Dr.
Holmes

INVOICE

72001

DATE

2/26/26