



PATIENT

Doori Yoon

SPECIES

Canine

BREED

Golden Retriever

SEX

Neutered male

AGE

15 years

WEIGHT

39 lbs

INTERPRETED BY

Remo Lobetti, BVSc,
MMedVet (Med),
PhD, Dipl. ECVIM

IMAGING PERFORMED BY

Dr. Paul Kim

HOSPITAL NAME

Ridgefield Park AH

REFERRING VET

Dr. Kim

INVOICE

71971

DATE

2/26/26

PRESENTING CLINICAL SIGNS

- Significant Weight loss in the past 12 months
- 3/9 BCS

ULTRASONOGRAPHIC EXAMINATION OF THE ABDOMEN

Urinary System

The urinary bladder is full with a normal thickness and smooth appearance of the wall. Normal anechoic urine with no sediment or uroliths evident.

Normal appearance of the trigone area, proximal urethra, and iliac blood vessels.

Normal appearance and size of the iliac lymph nodes. Ureters not visualized, which can be considered a normal finding.

Normal renal size (left measured 5.0 cm, right measured 6.1 cm), architecture, echogenic appearance, cortico-medullary differentiation, which maintains a 1:3 cortex to medulla ratio, pelvis, and capsule. No infarcts, mineralization or renoliths evident.

The prostate was not visualized.

Adrenal Glands

Normal shape, echogenic appearance, size, position, and appearance of the visible peri-adrenal vasculature. Left adrenal gland measured 1.66 cm in length x 0.41 cm in width. The right adrenal gland measured 1.4 cm in length x 0.45 cm in width.

Spleen

A large, irregular, mottled echogenic cystic mass measuring 4.7 cm in size. The rest of the spleen is of normal size (1.5 cm in width) maintaining a normal echogenic appearance, smooth homogenous parenchyma and regular curvilinear capsule. Normal volume of the splenic vasculature without any overt congestion or thrombosis evident.

Liver

Normal size, echogenic appearance, portal markings, and regular curvilinear capsule. No nodules or masses evident. Normal appearance of the hepatic and portal vasculature.

Gallbladder

The gallbladder is full containing normal anechoic bile. Normal thickness and echogenic appearance of the wall. Normal size and appearance of the cystic and common bile duct.



PATIENT

Doori Yoon

SPECIES

Canine

BREED

Golden Retriever

SEX

Neutered male

AGE

15 years

WEIGHT

39 lbs

INTERPRETED BY

Remo Lobetti, BVSc,
MMedVet (Med),
PhD, Dipl. ECVIM

IMAGING PERFORMED BY

Dr. Paul Kim

HOSPITAL NAME

Ridgefield Park AH

REFERRING VET

Dr. Kim

INVOICE

71971

DATE

2/26/26

Gastrointestinal

Normal appearance of the stomach, duodenum, small intestine, ileo-cecal junction, and colon with no loss of layering, 1:3 muscularis to mucosa ratio, normal wall thickness and peristaltic activity, and no distension of the lumen. The stomach wall measured up to 0.41 cm.

Pancreas

Normal size and echogenic appearance with a regular capsule. Normal echogenic appearance of the mesentery and fat surrounding the pancreas. The left pancreas measured 0.7 cm in width.

Free Abdomen

Normal mesenteric lymph nodes.

No ascites evident.

ULTRASONOGRAPHIC FINDINGS

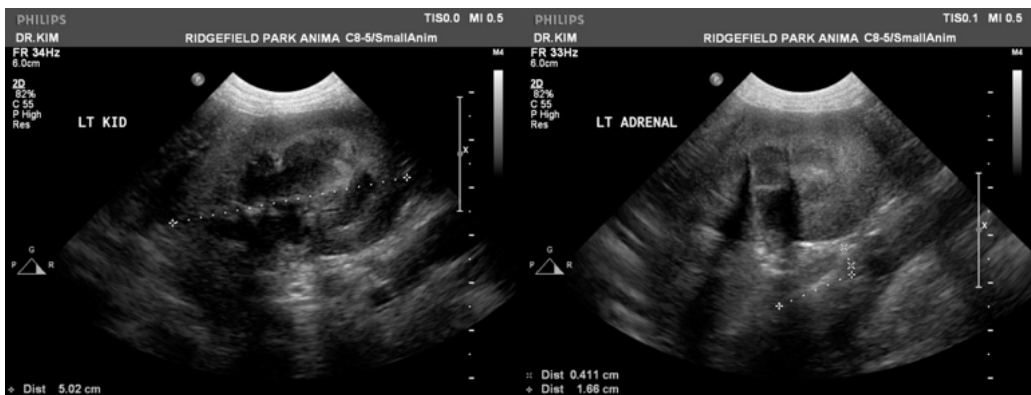- Splenic mass.

INTERPRETATION OF THE FINDINGS & FURTHER RECOMMENDATIONS

The most likely etiology for the splenic mass would be neoplasia with hematoma and granuloma a less likely differential diagnosis.

Further assessment would be three view thoracic radiographs, echocardiography to evaluate the right atrium and right auricle and possibly FNA cytology of the mass.

Splenectomy should be considered as it could be both diagnostic and therapeutic with further specific therapy dependent on an etiological diagnosis.





PATIENT

Doori Yoon

SPECIES

Canine

BREED

Golden Retriever

SEX

Neutered male

AGE

15 years

WEIGHT

39 lbs

INTERPRETED BY

Remo Lobetti, BVSc,
MMedVet (Med),
PhD, Dipl. ECVIM

IMAGING PERFORMED BY

Dr. Paul Kim

HOSPITAL NAME

Ridgefield Park AH

REFERRING VET

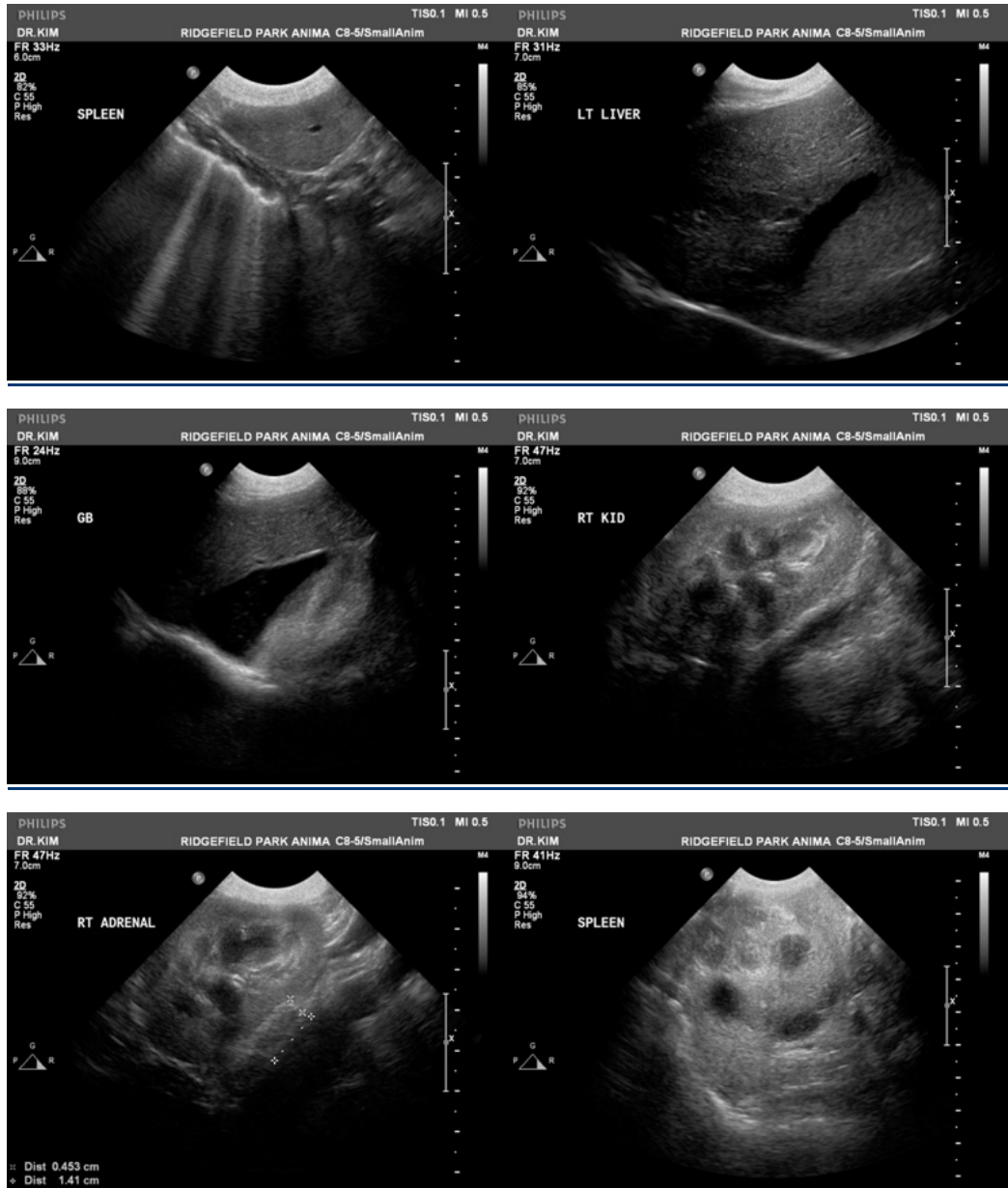
Dr. Kim

INVOICE

71971

DATE

2/26/26



The information and recommendations provided are based on the images presented by the referring veterinarian/sonographer. No evaluation can be communicated regarding pathology that was not visible in the image/video clips provided.

Thank you for this referral. If the clinical or image interpretation does not parallel your findings or if I can be of any further assistance please contact me.

Remo Lobetti, BVSc, MMedVet (Med), PhD, Dipl. ECVIM (Internal Medicine)

info@sonopath.com