



## PATIENT

Savi Garret

## SPECIES

Canine

## BREED

Miniature Schnauzer

## SEX

Spayed female

## AGE

12 years

## WEIGHT

6.65 kg

## INTERPRETED BY

Remo Lobetti, BVSc,  
MMedVet (Med),  
PhD, Dipl. ECVIM

## IMAGING PERFORMED BY

Dr. Maria Lara

## HOSPITAL NAME

Allure Veterinary  
Hospital & Urgent Care

## REFERRING VET

Dr. Lara

## INVOICE

71878

## DATE

2/25/26

## PRESENTING CLINICAL SIGNS

- Patient is back for recheck ultrasound after being diagnosed with PLE, had changes in gallbladder and started treatment. She has remained stable after initial plasma transfusion to normalize albumin.
- 12/02/25 TP 4.1 g/dL ( 5.0-7.4) L ALB 1.3 g/dL ( 2.7-4.4) L A/g Ratio 0.5 (0.8-2.0) ALP 302 IU/L ( 5-131) H CREA 0.4 mg/dL ( 0.5-1.6) L BUN/CREA 45 (4-27) H Ca 7.8 mg/dL (8.9-11.4) L Precision PSL 146 U/L (24-140) H CBC NEU 79% (60-77) H HGB 11.6 g/dL (12.1-20.3) L MCV 55 fL (58-79) L MCH 17.1 pg (19-28) L 2/25/26 CBC RBC 5.12 (5.65 - 8.87 M/μL) L MCV 74.6 (61.6 - 73.5 fL) H MCH 26.4 (21.2 - 25.9 pg) H Eosinophils 0.04 (0.06 - 1.23 K/μL) L Chem BUN 55 (7 - 27 mg/dL) H ALT 373 (10 - 125 U/L) H ALP >2,000 (23 - 212 U/L) H

## ULTRASONOGRAPHIC EXAMINATION OF THE ABDOMEN

### Urinary System

The urinary bladder is full with a normal thickness and smooth appearance of the wall. A scant amount of floating, hyperechogenic sediment.

Normal appearance of the trigone area, proximal urethra, and iliac blood vessels.

Normal appearance and size of the iliac lymph nodes. Ureters not visualized, which can be considered a normal finding.

Normal renal size (left measured 4.0 cm, right measured 4.3 cm), architecture, echogenic appearance, cortico-medullary differentiation, which maintains a 1:3 cortex to medulla ratio, pelvis, and capsule. No infarcts, mineralization or renoliths evident. Normal color flow pattern is evident in both kidneys.

### Adrenal Glands

The adrenal glands are bilaterally small and dorsoventrally flattened but maintained a normal echogenic appearance, position, and appearance of the visible peri-adrenal vasculature. Left adrenal gland measured 0.31 cm and 0.31 cm in width. The right adrenal gland measured 0.25 cm in width.

### Spleen

Normal size and echogenic appearance. Smooth homogenous parenchyma and regular curvilinear capsule. Normal volume of the splenic vasculature without any overt congestion or thrombosis evident. No inflammatory, neoplastic, infarction, or infiltrative changes evident. The spleen measured 1.0 cm in width.

### Liver

The liver is enlarged with rounded edges with a diffuse increased echogenic appearance, decreased portal markings, and regular curvilinear capsule. No nodules or masses evident. Normal appearance of the hepatic and portal vasculature.



## PATIENT

Savi Garret

## SPECIES

Canine

## BREED

Miniature Schnauzer

## SEX

Spayed female

## AGE

12 years

## WEIGHT

6.65 kg

## INTERPRETED BY

Remo Lobetti, BVSc,  
MMedVet (Med),  
PhD, Dipl. ECVIM

## IMAGING PERFORMED BY

Dr. Maria Lara

## HOSPITAL NAME

Allure Veterinary  
Hospital & Urgent Care

## REFERRING VET

Dr. Lara

## INVOICE

71878

## DATE

2/25/26

## ***Gallbladder***

The gallbladder is full containing a small amount of adhered, hyperechogenic sediment. Normal thickness and echogenic appearance of the wall. Normal size and appearance of the cystic and common bile duct.

## ***Gastrointestinal***

Normal appearance of the stomach, duodenum, small intestine, ileo-cecal junction, and colon with no loss of layering, 1:3 muscularis to mucosa ratio, normal wall thickness and peristaltic activity, and no distension of the lumen. A moderate amount of ingesta is present within the stomach compatible with a recent meal. The small intestine measured up to 0.32 cm.

## ***Pancreas***

The visible sections of the pancreas are of normal size and echogenic appearance with a regular capsule. Normal echogenic appearance of the mesentery and fat surrounding the pancreas.

## ***Free Abdomen***

Normal mesenteric lymph nodes.

No ascites evident.

## **ULTRASONOGRAPHIC FINDINGS**

- Bilaterally small adrenal glands
- Hepatopathy
- Gallbladder sediment.

## **INTERPRETATION OF THE FINDINGS & FURTHER RECOMMENDATIONS**

The appearance of the adrenal glands can be ascribed to the long term Prednisolone therapy.

The gallbladder assessment is most likely an incidental finding.

The most likely etiology for the hepatopathy would be secondary to the chronic Prednisolone administration.

In comparison with the previous ultrasound the previously reported enteropathy has resolved.

Diet  
Continue with hypoallergenic/novel protein diet.

Immune-suppressive therapy



## PATIENT

Savi Garret

## SPECIES

Canine

## BREED

Miniature Schnauzer

## SEX

Spayed female

## AGE

12 years

## WEIGHT

6.65 kg

## INTERPRETED BY

Remo Lobetti, BVSc,  
MMedVet (Med),  
PhD, Dipl. ECVIM

## IMAGING PERFORMED BY

Dr. Maria Lara

## HOSPITAL NAME

Allure Veterinary  
Hospital & Urgent Care

## REFERRING VET

Dr. Lara

## INVOICE

71878

## DATE

2/25/26

Prednisolone forms the foundation of therapy in dogs with any chronic enteropathy. As she has been on a high dose for 12 weeks and there has been a good improvement, the dose needs to be tapered down over 6-8 weeks to 2.5 mg every 2-3 days. Budesonide (1 mg SID) can be administered as an alternative to prednisolone as it has high topical anti-inflammatory activity and lower systemic activity because of its high affinity to the steroid receptor and rapid hepatic conversion to metabolites with minimal or no steroid activity.

If there is a relapse as the dose is being tapered and a high dose of prednisolone is needed and/or there are unacceptable adverse side effects then considered adding azathioprine (1-2 mg/kg SID for 2 weeks, followed by alternate-day administration) and/or cyclosporine (5 mg/kg SID).

### Cobalamin

Cobalamin deficiency has been associated with GI tract signs despite appropriate therapy in animals with a chronic enteropathy as mucosal repair is impeded. 25 ug/kg subcutaneously for 6 weeks on a weekly basis, with supplementation continued every 3 weeks for the indefinite future if serum cobalamin levels remain low. Oral supplementation of cobalamin at the same dose is equally effective but must be given daily for 12 weeks before testing and determining the need for ongoing supplementation.

### Probiotics

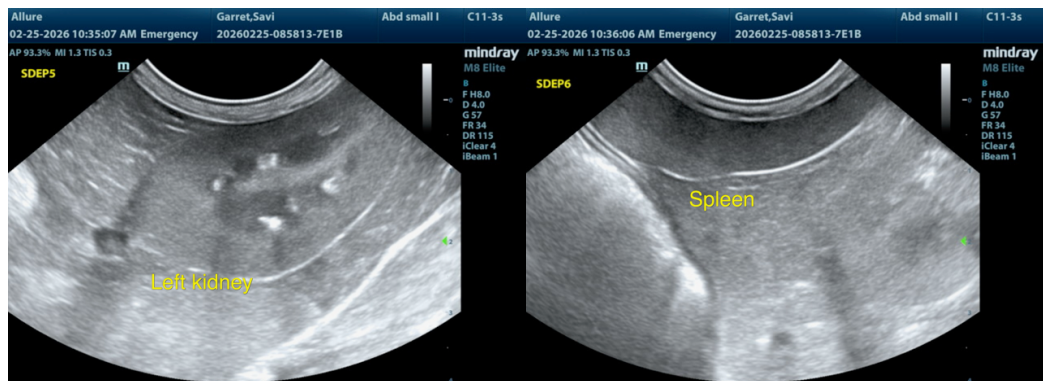
Probiotic administration using either single-strain or multi-strain products can be helpful in the management of a chronic enteropathy.

### Other medication

As there is steroid-induced hepatopathy, continuing with the Ursodiol would be recommended. The Tylan can be discontinued.

### Monitoring

As a guide to improvement, regular monitoring of serum proteins would be advocated.





**PATIENT**

Savi Garret

**SPECIES**

Canine

**BREED**

Miniature Schnauzer

**SEX**

Spayed female

**AGE**

12 years

**WEIGHT**

6.65 kg

**INTERPRETED BY**

Remo Lobetti, BVSc,  
MMedVet (Med),  
PhD, Dipl. ECVIM

**IMAGING PERFORMED BY**

Dr. Maria Lara

**HOSPITAL NAME**

Allure Veterinary  
Hospital & Urgent Care

**REFERRING VET**

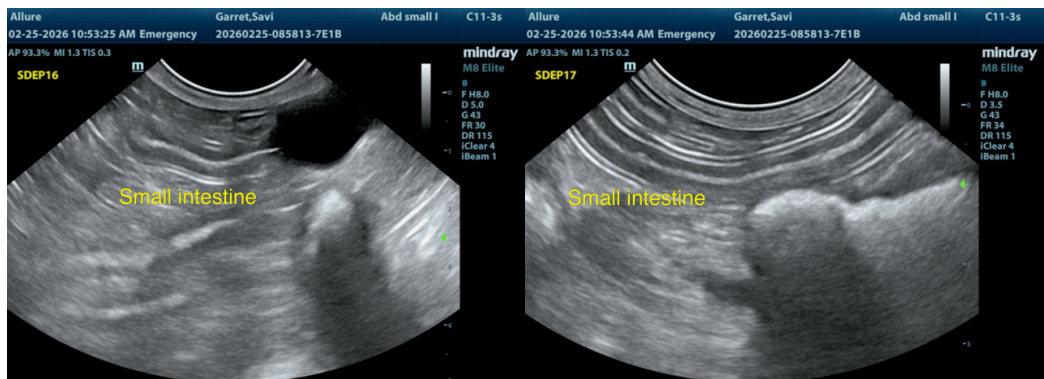
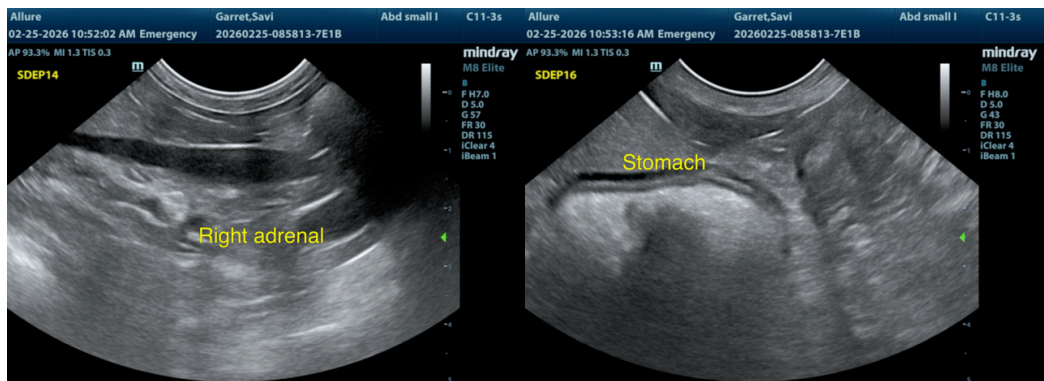
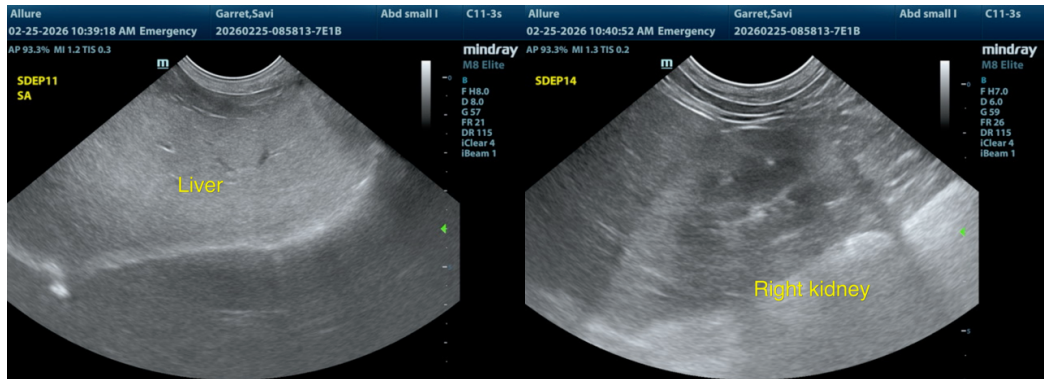
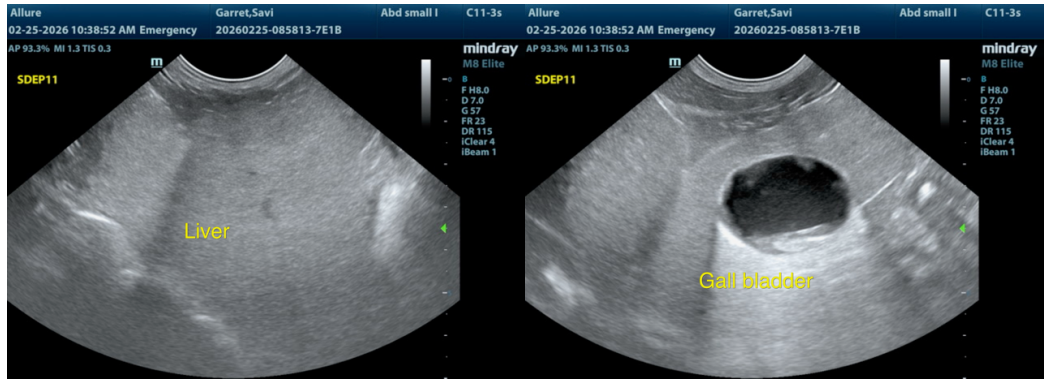
Dr. Lara

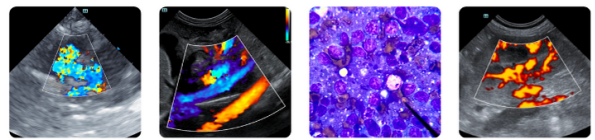
**INVOICE**

71878

**DATE**

2/25/26





## PATIENT

Savi Garret

## SPECIES

Canine

## BREED

Miniature Schnauzer

## SEX

Spayed female

## AGE

12 years

## WEIGHT

6.65 kg

## INTERPRETED BY

Remo Lobetti, BVSc,  
MMedVet (Med),  
PhD, Dipl. ECVIM

## IMAGING PERFORMED BY

Dr. Maria Lara

## HOSPITAL NAME

Allure Veterinary  
Hospital & Urgent Care

## REFERRING VET

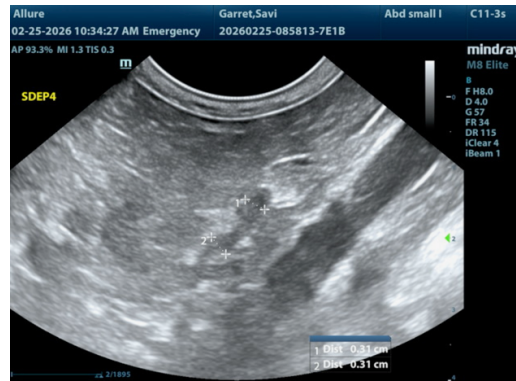
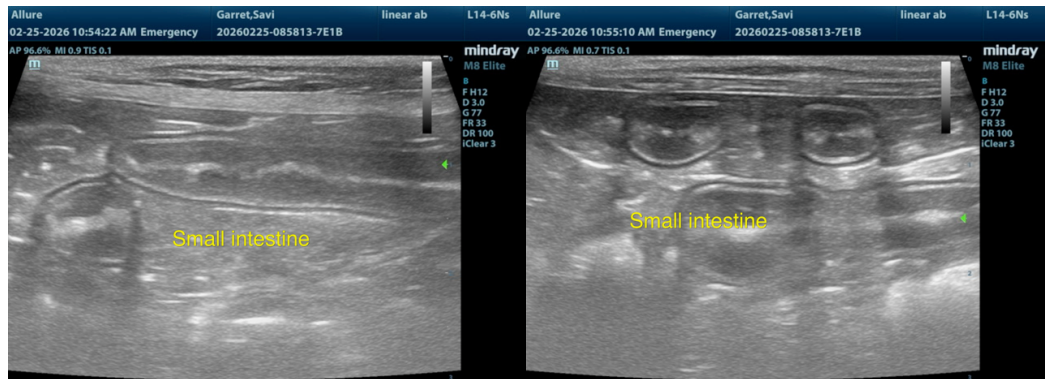
Dr. Lara

## INVOICE

71878

## DATE

2/25/26



The information and recommendations provided are based on the images presented by the referring veterinarian/sonographer. No evaluation can be communicated regarding pathology that was not visible in the image/video clips provided.

Thank you for this referral. If the clinical or image interpretation does not parallel your findings or if I can be of any further assistance please contact me.

Remo Lobetti, BVSc, MMedVet (Med), PhD, Dipl. ECVIM (Internal Medicine)

[info@sonopath.com](mailto:info@sonopath.com)