



PATIENT

Murphy Troutman

SPECIES

Canine

BREED

Saint Bernard

SEX

Neutered male

AGE

5 years

WEIGHT

188.6 lbs

INTERPRETED BY

Remo Lobetti, BVSc,
MMedVet (Med),
PhD, Dipl. ECVIM

IMAGING PERFORMED BY

Dr. Christina Miller

HOSPITAL NAME

Seven Fields VH

REFERRING VET

Dr. Miller

INVOICE

71956

DATE

2/25/26

PRESENTING CLINICAL SIGNS

- Syncopal event on 1/2/2026 suspect vasovagal. Possible abdominal mass noted on radiographs. Overall doing well at home with no further collapsing events.
- Possible abdominal mass on radiographs CBC- WNL Chem- Mild hyperglobulinemia (4.2) T4- WNL Anaplasma pos (historical) EKG WNL BP normal

ULTRASONOGRAPHIC EXAMINATION OF THE ABDOMEN

Urinary System

The urinary bladder is small with a normal thickness and smooth appearance of the wall. Normal anechoic urine with no sediment or uroliths evident.

Normal appearance of the trigone area, proximal urethra, and iliac blood vessels.

Normal appearance and size of the iliac lymph nodes. Ureters not visualized, which can be considered a normal finding.

Normal renal size (left measured 8.9 cm, right measured 8.5 cm), architecture, echogenic appearance, cortico-medullary differentiation, which maintains a 1:3 cortex to medulla ratio, pelvis, and capsule. No infarcts, mineralization or renoliths evident. Normal color flow pattern is evident in both kidneys.

Normal size and appearance of the prostate measuring 5.3 x 5.6 cm in size.

Adrenal Glands

Normal shape, echogenic appearance, size, position, and appearance of the visible peri-adrenal vasculature. Left adrenal gland measured 0.64 cm in width. The right adrenal gland measured 0.5 cm in width.

Spleen

Normal size and echogenic appearance. Smooth homogenous parenchyma and regular curvilinear capsule. Normal volume of the splenic vasculature without any overt congestion or thrombosis evident. No inflammatory, neoplastic, infarction, or infiltrative changes evident. The spleen measured 2.5 cm in width

Liver

Normal size, echogenic appearance, portal markings, and regular curvilinear capsule. No nodules or masses evident. Normal appearance of the hepatic and portal vasculature.



PATIENT

Murphy Troutman

SPECIES

Canine

BREED

Saint Bernard

SEX

Neutered male

AGE

5 years

WEIGHT

188.6 lbs

INTERPRETED BY

Remo Lobetti, BVSc,
MMedVet (Med),
PhD, Dipl. ECVIM

IMAGING PERFORMED BY

Dr. Christina Miller

HOSPITAL NAME

Seven Fields VH

REFERRING VET

Dr. Miller

INVOICE

71956

DATE

2/25/26

Gallbladder

The gallbladder is small containing normal anechoic bile. Normal thickness and echogenic appearance of the wall. Normal size and appearance of the cystic and common bile duct.

Gastrointestinal

Normal appearance of the stomach, duodenum, small intestine, ileo-cecal junction, and colon with no loss of layering, 1:3 muscularis to mucosa ratio, normal wall thickness and peristaltic activity, and no distension of the lumen.

Pancreas

The visible sections of the pancreas are of normal size and echogenic appearance with a regular capsule. Normal echogenic appearance of the mesentery and fat surrounding the pancreas.

Free Abdomen

Normal mesenteric lymph nodes.

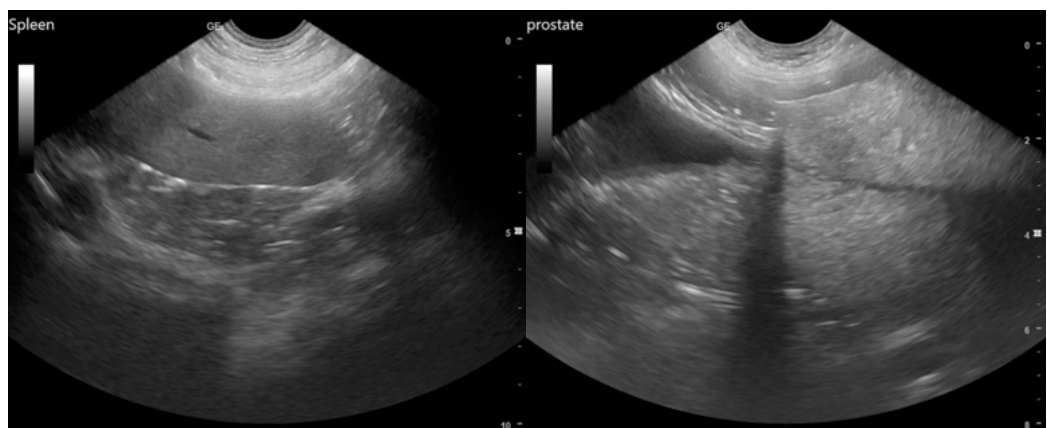
No ascites evident.

ULTRASONOGRAPHIC FINDINGS

- Normal ultrasound examination of the abdomen.

INTERPRETATION OF THE FINDINGS & FURTHER RECOMMENDATIONS

No specific therapy is recommended at this time.





PATIENT

Murphy Troutman

SPECIES

Canine

BREED

Saint Bernard

SEX

Neutered male

AGE

5 years

WEIGHT

188.6 lbs

INTERPRETED BY

Remo Lobetti, BVSc,
MMedVet (Med),
PhD, Dipl. ECVIM

IMAGING PERFORMED BY

Dr. Christina Miller

HOSPITAL NAME

Seven Fields VH

REFERRING VET

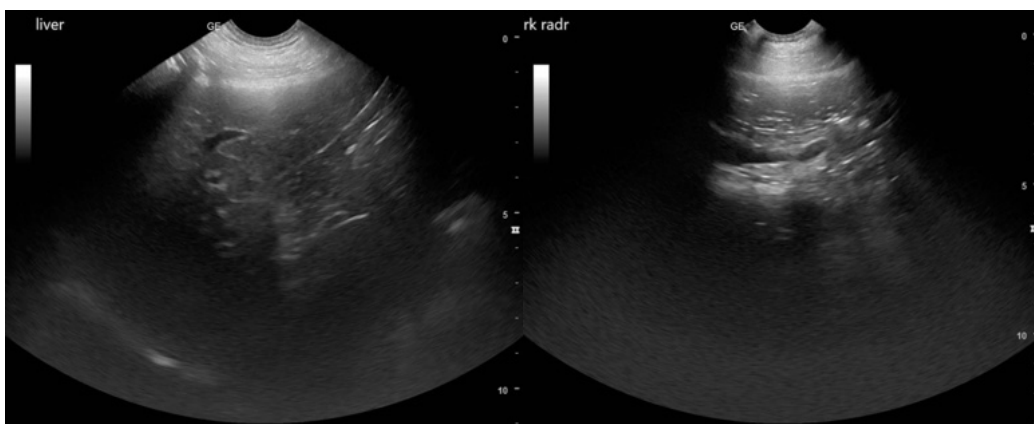
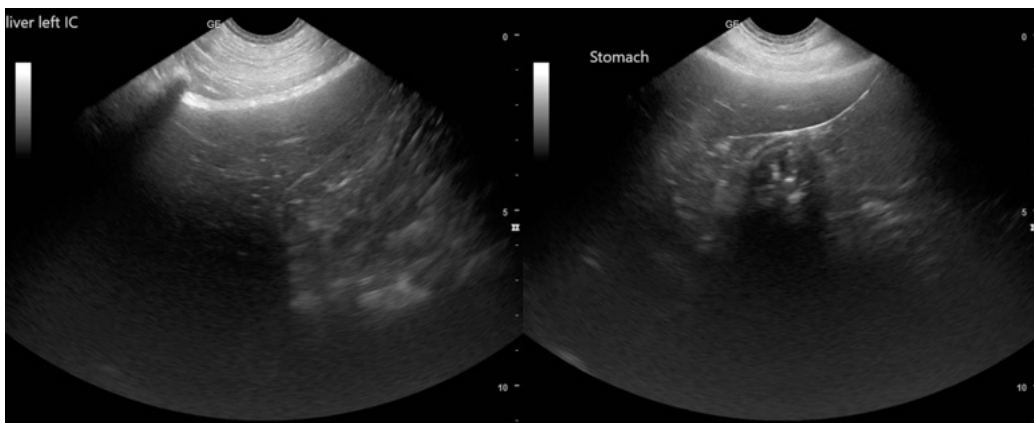
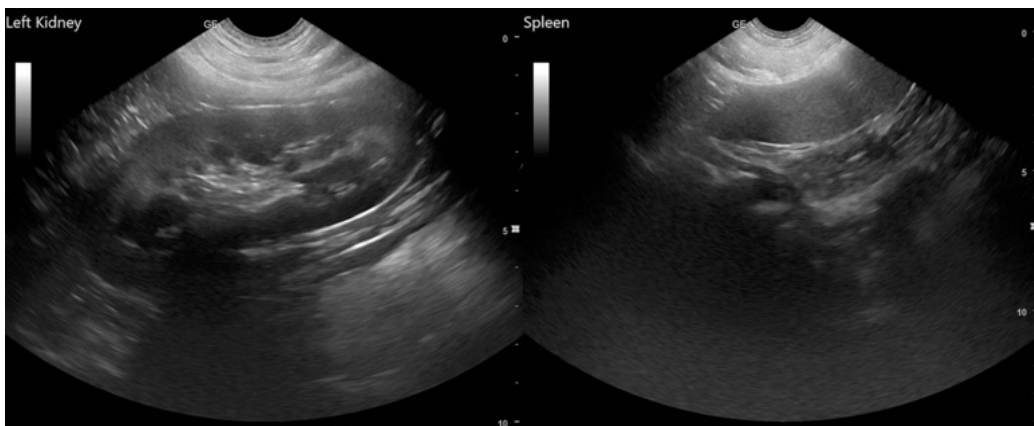
Dr. Miller

INVOICE

71956

DATE

2/25/26





PATIENT

Murphy Troutman

SPECIES

Canine

BREED

Saint Bernard

SEX

Neutered male

AGE

5 years

WEIGHT

188.6 lbs

INTERPRETED BY

Remo Lobetti, BVSc,
MMedVet (Med),
PhD, Dipl. ECVIM

IMAGING PERFORMED BY

Dr. Christina Miller

HOSPITAL NAME

Seven Fields VH

REFERRING VET

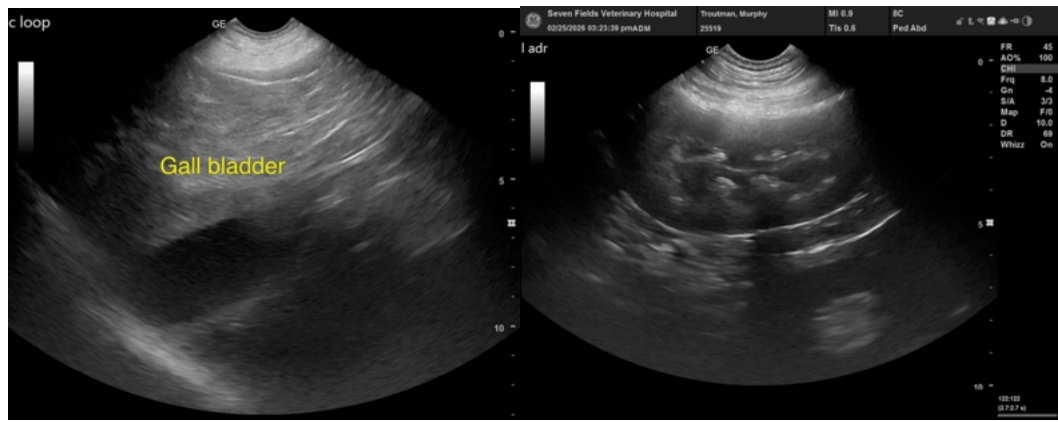
Dr. Miller

INVOICE

71956

DATE

2/25/26



The information and recommendations provided are based on the images presented by the referring veterinarian/sonographer. No evaluation can be communicated regarding pathology that was not visible in the image/video clips provided.

Thank you for this referral. If the clinical or image interpretation does not parallel your findings or if I can be of any further assistance please contact me.

Remo Lobetti, BVSc, MMedVet (Med), PhD, Dipl. ECVIM (Internal Medicine)

info@sonopath.com