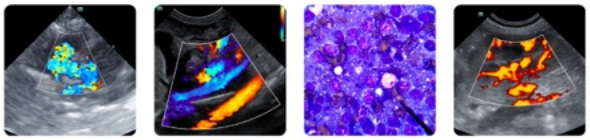

PATIENT

Bella Brader

SPECIES

Canine

BREED

German Shepherd

SEX

Spayed female

AGE

8 years

WEIGHT

116 lbs

INTERPRETED BY

Remo Lobetti, BVSc, MMedVet (Med), PhD, Dipl. ECVIM

IMAGING PERFORMED BY

Dr. Jenni Tudini MRCVS, SDEP Cert

HOSPITAL NAME

Fetch the Vet Mobile VP

REFERRING VET

Dr. Jenni Tudini MRCVS, SDEP Cert

INVOICE

71952

DATE

2/25/26

PRESENTING CLINICAL SIGNS

- Owners have concerns that in the last few months patient has become markedly polyphagic, polydipsic and polyuric. No inappropriate urination noted in home. No C/S/V/D. Water intake measurement results requested and not yet received from client. Following initial bloodwork patient was dispensed Amoxiclav and Denamarin for possible cholangiohepatitis however there has been no improvement clinically or in respect to repeat bloodwork. Recommended abdominal ultrasound and possible further work up for hyperadrenocorticism.
- BCS 9/9 otherwise exam unremarkable Results: 01/28: - CBC: WBC 17.6 (5.8-16.2) - comprising of a mild neutrophilia 14.4 (3-9.74), monocytes 1.54 (0.14-0.73). All other parameters WNL - Biochem: Potassium 3.9 (4-5.4), CL 98 (108-119), ALT 357 (18-121), ALKP 315 (5-160), GGT 15 (0-13) U/a: SG 1.005, no other significant findings T4: 1.9 (1-4) Results: 02/24/26: - Phosphorous 6.4 (2.5-6.1). ALT 327 (prev 357), ALKP 316 (prev 315), GGT 16 (prev 15)

ULTRASONOGRAPHIC EXAMINATION OF THE ABDOMEN

Urinary System

The urinary bladder is small with a normal thickness and smooth appearance of the wall. Normal anechoic urine with no sediment or uroliths evident.

Normal appearance of the trigone area, proximal urethra, and iliac blood vessels.

Normal appearance and size of the iliac lymph nodes. Ureters not visualized, which can be considered a normal finding.

Normal renal size (left measured 7.9 cm, right measured 7.7 cm), architecture, echogenic appearance, cortico-medullary differentiation, which maintains a 1:3 cortex to medulla ratio, pelvis, and capsule. No infarcts, mineralization or renoliths evident. Normal color flow pattern is evident in both kidneys.

Adrenal Glands

Normal shape, echogenic appearance, size, position, and appearance of the visible peri-adrenal vasculature. Left adrenal gland measured 3.36 cm in length x 0.98 cm and 0.91 cm in width. The right adrenal gland measured 2.2 cm in length x 0.84 cm and 0.67 cm in width.

Spleen

Normal size and echogenic appearance. Smooth homogenous parenchyma and regular curvilinear capsule. Normal volume of the splenic vasculature without any overt congestion or thrombosis evident. No inflammatory, neoplastic, infarction, or infiltrative changes evident. The spleen measured 3.7 cm in width.

PATIENT

Bella Brader

SPECIES

Canine

BREED

German Shepherd

SEX

Spayed female

AGE

8 years

WEIGHT

116 lbs

INTERPRETED BY

Remo Lobetti, BVSc, MMedVet (Med), PhD, Dipl. ECVIM

IMAGING PERFORMED BY

Dr. Jenni Tudini MRCVS, SDEP Cert

HOSPITAL NAME

Fetch the Vet Mobile VP

REFERRING VET

Dr. Jenni Tudini MRCVS, SDEP Cert

INVOICE

71952

DATE

2/25/26

Liver

Normal size, echogenic appearance, portal markings, and regular curvilinear capsule. No nodules or masses evident. Normal appearance of the hepatic and portal vasculature.

Gallbladder

The gallbladder is full containing normal anechoic bile. Normal thickness and echogenic appearance of the wall. Normal size and appearance of the cystic and common bile duct.

Gastrointestinal

Normal appearance of the stomach, duodenum, small intestine, ileo-cecal junction, and colon with no loss of layering, 1:3 muscularis to mucosa ratio, normal wall thickness and peristaltic activity, and no distension of the lumen.

Pancreas

The visible sections of the pancreas are of normal size and echogenic appearance with a regular capsule. Normal echogenic appearance of the mesentery and fat surrounding the pancreas.

Free Abdomen

Normal mesenteric lymph nodes.

No ascites evident.

ULTRASONOGRAPHIC FINDINGS

- Normal ultrasound examination of the abdomen.

INTERPRETATION OF THE FINDINGS & FURTHER RECOMMENDATIONS

On this ultrasound there is no obvious etiology for the presenting clinical signs.

Although the adrenal glands appear ultrasonographically normal, with the presenting clinical signs, pituitary dependent Cushing's disease would be an important consideration.

Further assessment would be urine specific gravity and urine cortisol to creatinine ratio and if abnormal then adrenal function testing (ACTH stimulation/LDDST) would then be indicated.

Specific therapy would be dependent on an etiological diagnosis.

SonoPath

FOSTERING THE ART OF VETERINARY MEDICINE™

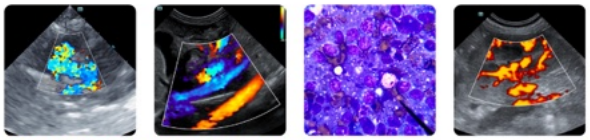

Clinical Sonography & Telecytology

Educational Teleconsultation Services™

SonoPath.com info@sonopath.com 1.800.838.4268

PATIENT

Bella Brader

SPECIES

Canine

BREED

German Shepherd

SEX

Spayed female

AGE

8 years

WEIGHT

116 lbs

INTERPRETED BY

Remo Lobetti, BVSc, MMedVet (Med), PhD, Dipl. ECVIM

IMAGING PERFORMED BY

Dr. Jenni Tudini MRCVS, SDEP Cert

HOSPITAL NAME

Fetch the Vet Mobile VP

REFERRING VET

Dr. Jenni Tudini MRCVS, SDEP Cert

INVOICE

71952

DATE

2/25/26

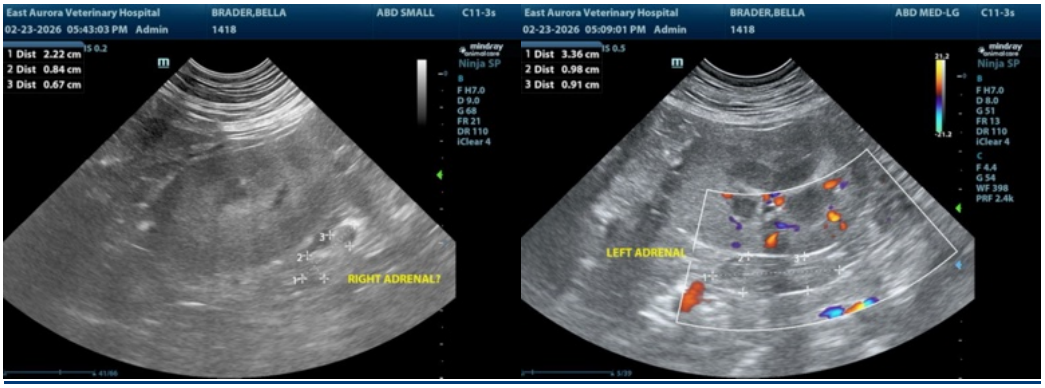

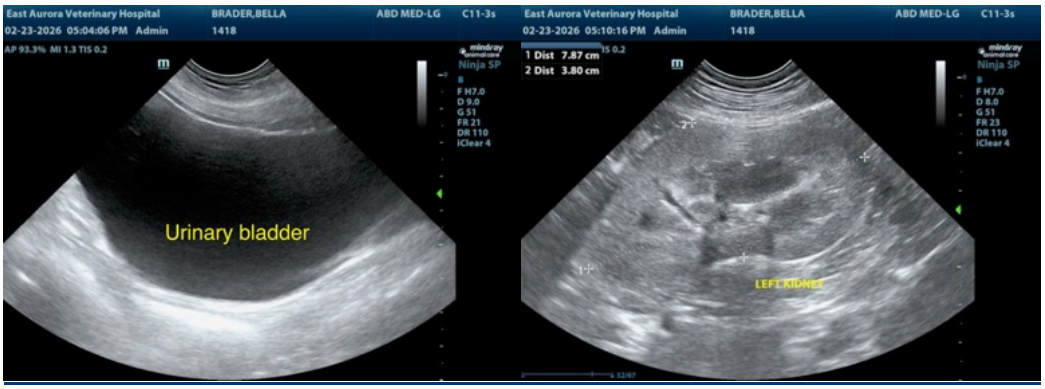

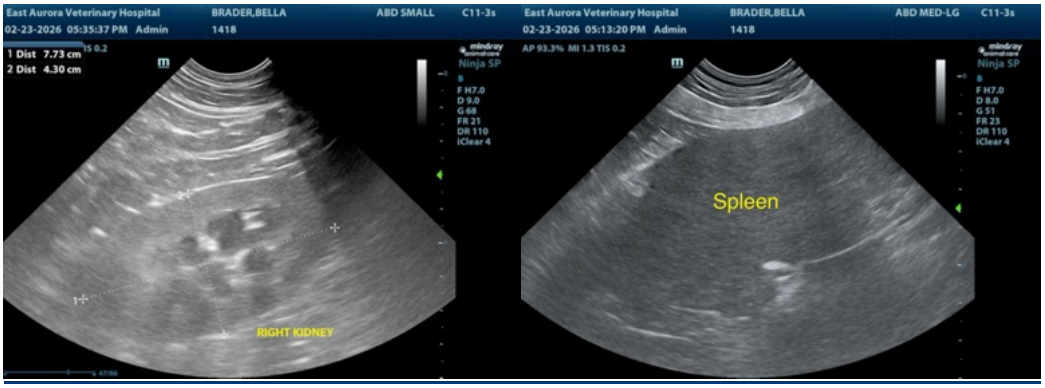

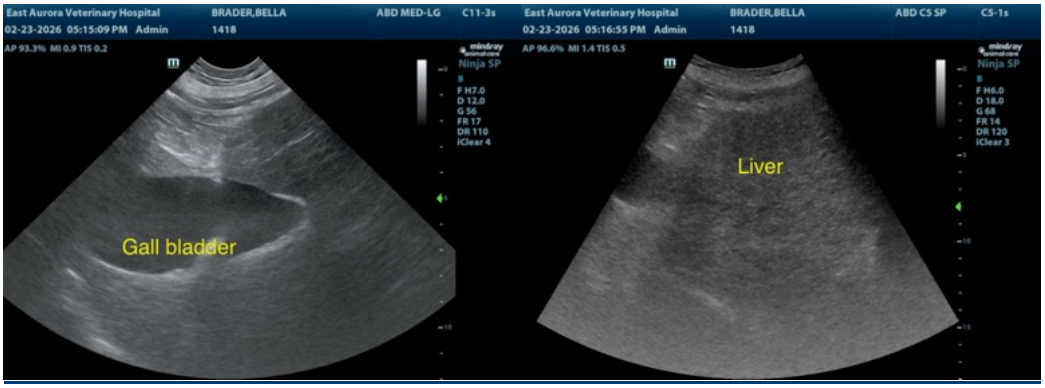

PATIENT

Bella Brader

SPECIES

Canine

BREED

German Shepherd

SEX

Spayed female

AGE

8 years

WEIGHT

116 lbs

INTERPRETED BY

Remo Lobetti, BVSc, MMedVet (Med), PhD, Dipl. ECVIM

IMAGING PERFORMED BY

Dr. Jenni Tudini MRCVS, SDEP Cert

HOSPITAL NAME

Fetch the Vet Mobile VP

REFERRING VET

Dr. Jenni Tudini MRCVS, SDEP Cert

INVOICE

71952

DATE

2/25/26

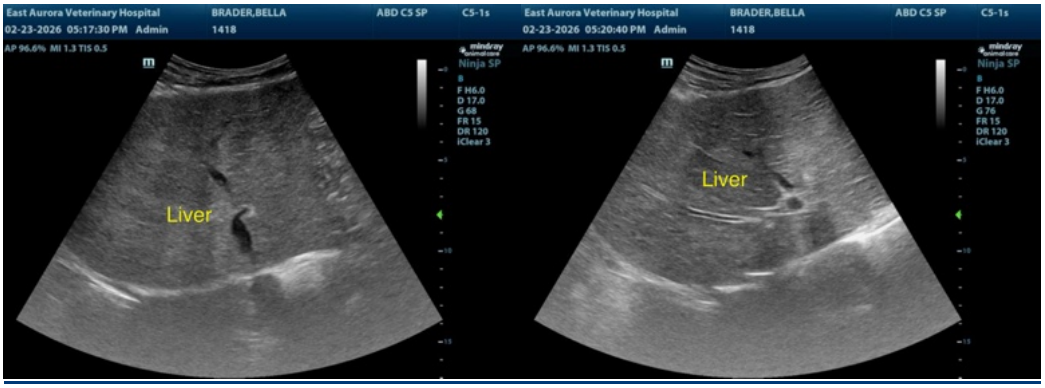

The information and recommendations provided are based on the images presented by the referring veterinarian/sonographer. No evaluation can be communicated regarding pathology that was not visible in the image/video clips provided.

Thank you for this referral. If the clinical or image interpretation does not parallel your findings or if I can be of any further assistance please contact me.

Remo Lobetti, BVSc, MMedVet (Med), PhD, Dipl. ECVIM (Internal Medicine)

info@sonopath.com