



PATIENT

Tigger Perkins

SPECIES

Canine

BREED

Boxer x

SEX

Neutered Male

AGE

13 Years 7 Months

WEIGHT

62 lbs

INTERPRETED BY

Remo Lobetti, BVSc,
 MMedVet (Med),
 PhD, Dipl. ECVIM

IMAGING PERFORMED BY

Kathleen Byrnes

HOSPITAL NAME

Aloha Veterinary
 Hospital

REFERRING VET

Dr. Mori

INVOICE

73122

DATE

2/20/26

PRESENTING CLINICAL SIGNS

P presented for US due to PU/PD elevated liver values and Positive LDDST.

Abnormal PE/Chem/CBC/UA Results: Neut 11.8, Mono 0.9 ALT 457, AST 56, ALKP 1692, GGT 30, Chol 401 usg 1.019, Protein 1+ LDDST 8.3, 4 hr 4.6, 8 hr 6.6 T4 <0.4

ULTRASONOGRAPHIC EXAMINATION OF THE ABDOMEN

Urinary System

Full urinary bladder with a normal thickness and smooth appearance of the wall. Normal anechoic urine with no sediment or uroliths evident.

Normal appearance of the trigone area, proximal urethra, and iliac blood vessels.

Normal appearance and size of the iliac lymph nodes. Ureters not visualized, which can be considered a normal finding.

Normal renal size, architecture, echogenic appearance, cortico-medullary differentiation, which maintains a 1:3 cortex to medulla ratio, pelvis, and capsule. No infarcts, mineralization or renoliths evident. Left kidney measured 7.0 cm. Right kidney measured 6.7 cm.

Reproductive System

Small, hypoechogenic prostate measuring 1.3 cm in width.

Adrenal Glands

Bilaterally enlarged with a slightly rounded shape, but maintaining normal echogenic appearance, position, and appearance of the visible peri-adrenal vasculature. Left measures 3.38 cm in length x 0.85 cm and 1.06 cm in width. Right measures 2.44 cm in length x 0.73 cm and 0.87 cm in width.

Spleen

Normal size (1.5 cm in width) and echogenic appearance. Smooth homogenous parenchyma and regular curvilinear capsule. Normal volume of the splenic vasculature without any overt congestion or thrombosis evident. No inflammatory, neoplastic, infarction, or infiltrative changes evident.

Liver

Normal size, with a diffuse increased echogenic appearance, normal portal markings, and regular curvilinear capsule. A circumscribed hyperechogenic area is noted in the parenchyma of the caudal aspect of the right lobe measuring approximately 3.5 cm x 5.3 cm. No nodules or additional masses evident. Normal appearance of the hepatic and portal vasculature.

Gallbladder

Full containing normal anechoic bile. Normal thickness and echogenic appearance of the wall. Normal size and appearance of the cystic and common bile duct.



PATIENT

Tigger Perkins

SPECIES

Canine

BREED

Boxer x

SEX

Neutered Male

AGE

13 Years 7 Months

WEIGHT

62 lbs

INTERPRETED BY

Remo Lobetti, BVSc,
MMedVet (Med),
PhD, Dipl. ECVIM

IMAGING PERFORMED BY

Kathleen Byrnes

HOSPITAL NAME

Aloha Veterinary
Hospital

REFERRING VET

Dr. Mori

INVOICE

73122

DATE

2/20/26

Gastrointestinal

Normal appearance of the stomach, duodenum, small intestine, ileo-cecal junction, and colon with no loss of layering, 1:3 muscularis to mucosa ratio, normal wall thickness and peristaltic activity, and no distension of the lumen.

Pancreas

Normal size and echogenic appearance. Regular capsule. Normal echogenic appearance of the mesentery and fat surrounding the pancreas. Left pancreas measures 1.0 cm in width, with patchy parenchymal mineralization present.

Free Abdomen

Normal mesenteric lymph nodes.

No ascites evident.

ULTRASONOGRAPHIC FINDINGS

- Bilateral adrenomegaly.
- Hepatopathy.
- Hepatic mass-like lesion.
- Pancreatic mineralization.

INTERPRETATION OF THE FINDINGS & FURTHER RECOMMENDATIONS

The appearance of the adrenal glands is consistent with pituitary dependent Cushing's disease, in line with the positive LDDS test.

The most likely etiology for the hepatopathy would be metabolic secondary to the Cushing's disease, with reactive hyperplasia, early nodular hyperplasia, and vacuolar being differential diagnoses. Hepatitis and infiltrative neoplasia would be highly unlikely differential diagnoses.

Etiologies for the hyperechogenic mass-like effect would be fibrosis and a previous episode of hepatitis, focal hepatitis, and possibly emerging neoplasia.

The pancreatic mineralization can be considered an incidental finding and most likely representing a previous episode of pancreatitis.

Further assessment that could be considered would be FNA cytology of the liver and the hyperechogenic mass-like area. However, a tru-cut or wedge biopsy may be required for a final etiological diagnosis.

Management of the Cushing's disease with Trilostane would be recommended.

Specific therapy would be dependent on an etiological diagnosis.



PATIENT

Tigger Perkins

SPECIES

Canine

BREED

Boxer x

SEX

Neutered Male

AGE

13 Years 7 Months

WEIGHT

62 lbs

INTERPRETED BY

Remo Lobetti, BVSc,
 MMedVet (Med),
 PhD, Dipl. ECVIM

IMAGING PERFORMED BY

Kathleen Byrnes

HOSPITAL NAME

Aloha Veterinary
 Hospital

REFERRING VET

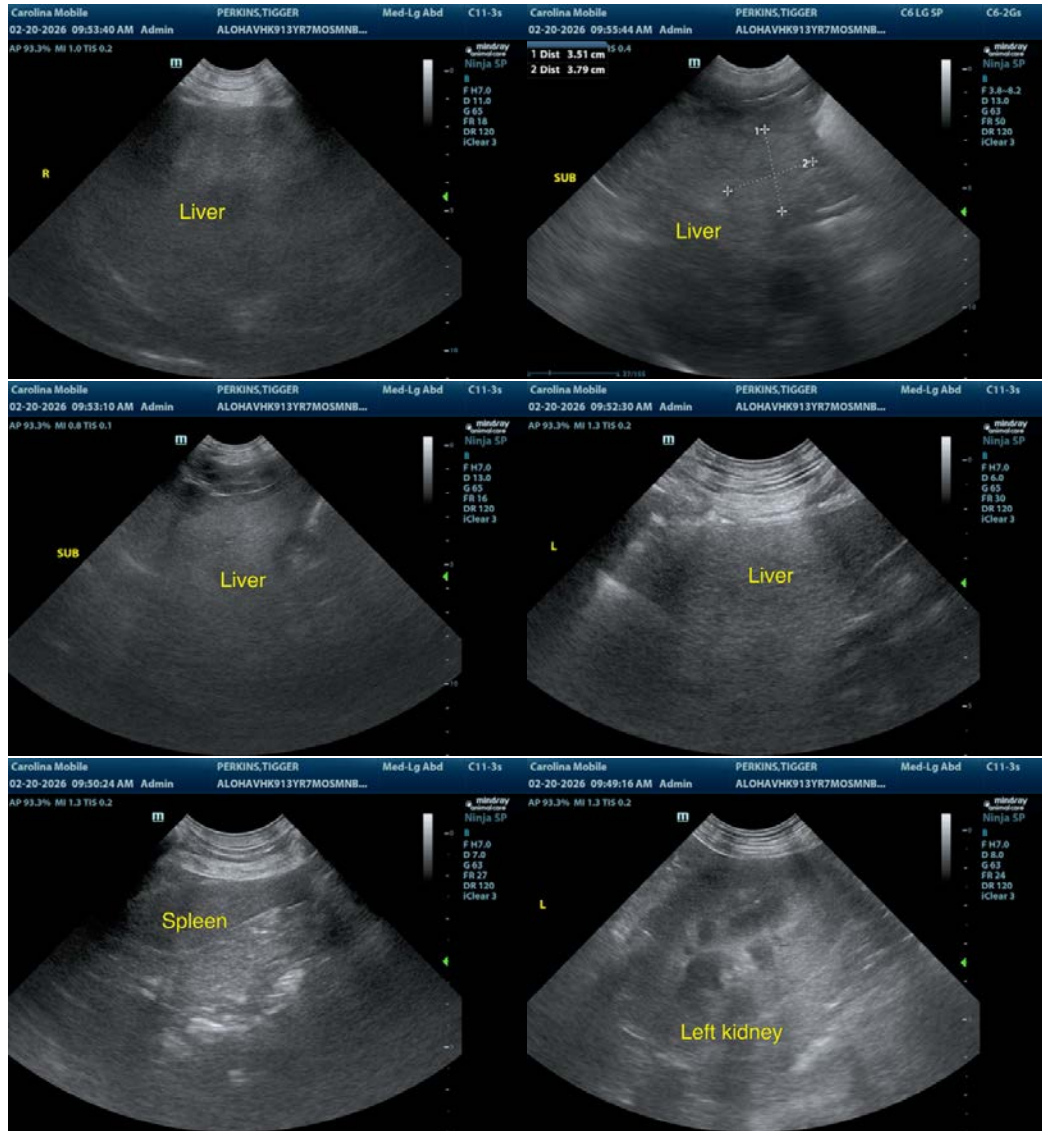
Dr. Mori

INVOICE

73122

DATE

2/20/26





PATIENT

Tigger Perkins

SPECIES

Canine

BREED

Boxer x

SEX

Neutered Male

AGE

13 Years 7 Months

WEIGHT

62 lbs

INTERPRETED BY

Remo Lobetti, BVSc,
 MMedVet (Med),
 PhD, Dipl. ECVIM

IMAGING PERFORMED BY

Kathleen Byrnes

HOSPITAL NAME

Aloha Veterinary
 Hospital

REFERRING VET

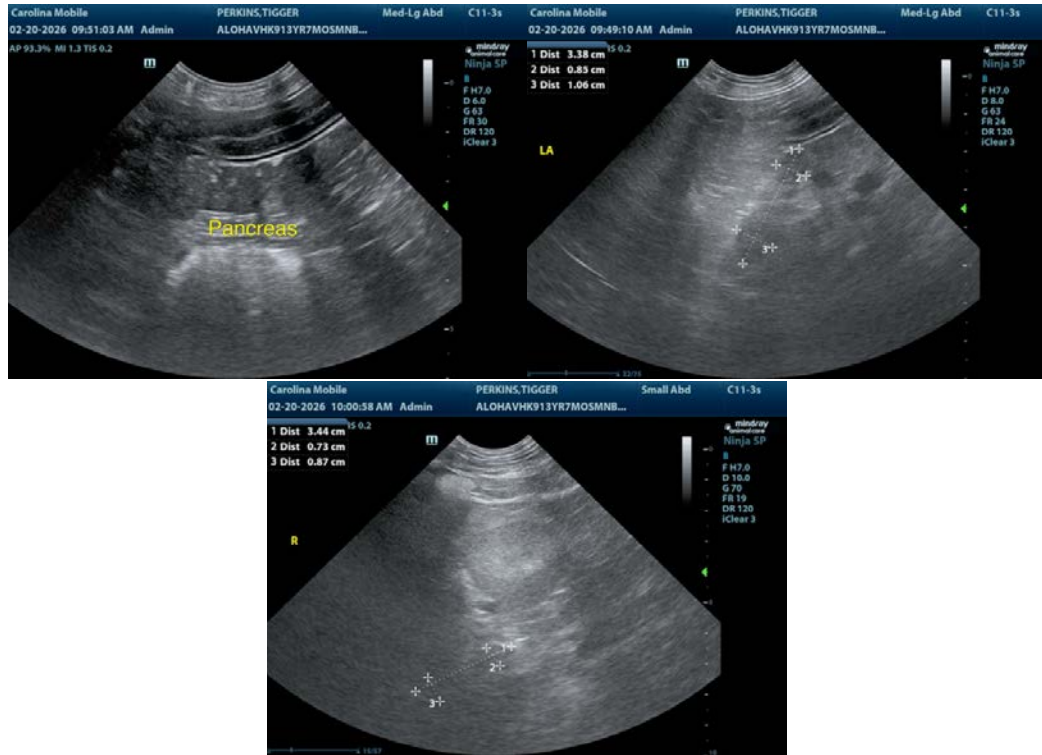
Dr. Mori

INVOICE

73122

DATE

2/20/26



The information and recommendations provided are based on the images presented by the referring veterinarian. No evaluation can be communicated regarding pathology that was not visible in the image/video clips provided.

Thank you for this referral. If the clinical or image interpretation does not parallel your findings or if I can be of any further assistance, please contact me.

Remo Lobetti, BVSc, MMedVet (Med), PhD, Dipl. ECVIM (Internal Medicine)

info@sonopath.com