



## PATIENT

Beretta Day

## SPECIES

Canine

## BREED

Husky Border Collie  
Mix

## SEX

Spayed Female

## AGE

12 Years

## WEIGHT

44 Pounds

## INTERPRETED BY

Remo Lobetti BVSc,  
MMedVet, PhD,  
DECVIM

## IMAGING PERFORMED BY

Julia Bakker, DVM

## HOSPITAL NAME

Orange Blossom VI

## REFERRING VET

Nicole Day, DVM

## INVOICE

35656

## DATE

2/2/26

## PRESENTING CLINICAL SIGNS

- Rechecking gall bladder after previous history of polyps and recent episode of nausea without CPL elevations
- Abnormal PE/Chem/CBC/UA Results: Previous AUS to compare attached

## ULTRASONOGRAPHIC EXAMINATION OF THE ABDOMEN

### *Urinary System*

Small urinary bladder with a normal thickness and smooth appearance of the wall. Normal anechoic urine with no sediment or uroliths evident. Normal appearance of the trigone area, proximal urethra, and iliac blood vessels. Normal appearance and size of the iliac lymph nodes. Ureters not visualized, which can be considered a normal finding.

Normal renal size, architecture, echogenic appearance, cortico-medullary differentiation, which maintains a 1:3 cortex to medulla ratio, pelvis, and capsule. No infarcts, mineralization or renoliths evident. The left kidney measured 5.7 cm. The right kidney measured 6.2 cm.

### *Adrenal Glands*

Normal shape, echogenic appearance, size, position, and appearance of the visible peri-adrenal vasculature. The left adrenal gland measured 2.97 cm in length x 0.81 cm and 0.92 cm in width. The right adrenal gland measured 2.94 cm in length x 0.47 cm in width.

### *Spleen*

Normal size (2.3 cm in width) and echogenic appearance. Smooth homogenous parenchyma and regular curvilinear capsule. Normal volume of the splenic vasculature without any overt congestion or thrombosis evident. No inflammatory, neoplastic, infarction, or infiltrative changes evident. Incidental myelolipomas were present.

### *Liver*

Normal size, echogenic appearance, portal markings, and regular curvilinear capsule. No nodules or masses evident. Normal appearance of the hepatic and portal vasculature.

### *Gallbladder*

Full gallbladder, containing a small amount of both adhered and non-adhered hyperechogenic sediment. Thickened gallbladder wall with a mild polypoid appearance but maintaining a normal echogenic appearance. Normal size and appearance of the cystic and common bile duct.

### *Gastrointestinal*

Normal appearance of the stomach, duodenum, small intestine, ileo-cecal junction, and colon with no loss of layering, 1:3 muscularis to mucosa ratio, normal wall thickness and peristaltic activity, and no distension of the lumen.

### *Pancreas*



**PATIENT**

Beretta Day

**SPECIES**

Canine

**BREED**

Husky Border Collie Mix

**SEX**

Spayed Female

**AGE**

12 Years

**WEIGHT**

44 Pounds

**INTERPRETED BY**

Remo Lobetti BVSc, MMedVet, PhD, DECVIM

**IMAGING PERFORMED BY**

Julia Bakker, DVM

**HOSPITAL NAME**

Orange Blossom VI

**REFERRING VET**

Nicole Day, DVM

**INVOICE**

35656

**DATE**

2/2/26

Visible sections of the pancreas are of normal size and echogenic appearance with a regular capsule. Normal echogenic appearance of the mesentery and fat surrounding the pancreas.

**Free Abdomen**

Normal mesenteric lymph nodes.

No ascites evident.

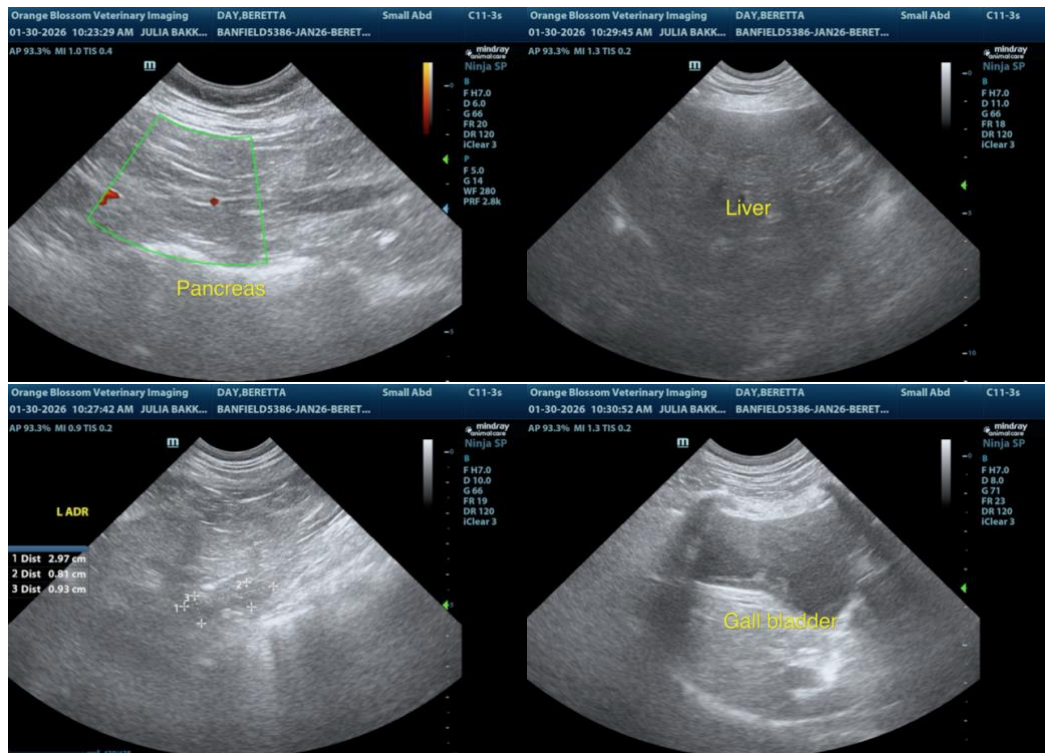
**ULTRASONOGRAPHIC FINDINGS**

- Gallbladder sediment
- Gallbladder wall thickening

**INTERPRETATION OF THE FINDINGS & FURTHER RECOMMENDATIONS**

The appearance of the gallbladder on this ultrasound is similar to that of the previous ultrasound, and thus, can be considered an incidental age-related finding. The gallbladder sediment, likewise, can be considered an incidental finding.

On this ultrasound, the previous reported hepatic nodule is not evident. In essence, a normal ultrasound examination of the abdomen, with no obvious etiology for the episode of nausea.





**PATIENT**

Beretta Day

**SPECIES**

Canine

**BREED**

Husky Border Collie Mix

**SEX**

Spayed Female

**AGE**

12 Years

**WEIGHT**

44 Pounds

**INTERPRETED BY**

Remo Lobetti BVSc,  
MMedVet, PhD,  
DECVIM

**IMAGING PERFORMED BY**

Julia Bakker, DVM

**HOSPITAL NAME**

Orange Blossom VI

**REFERRING VET**

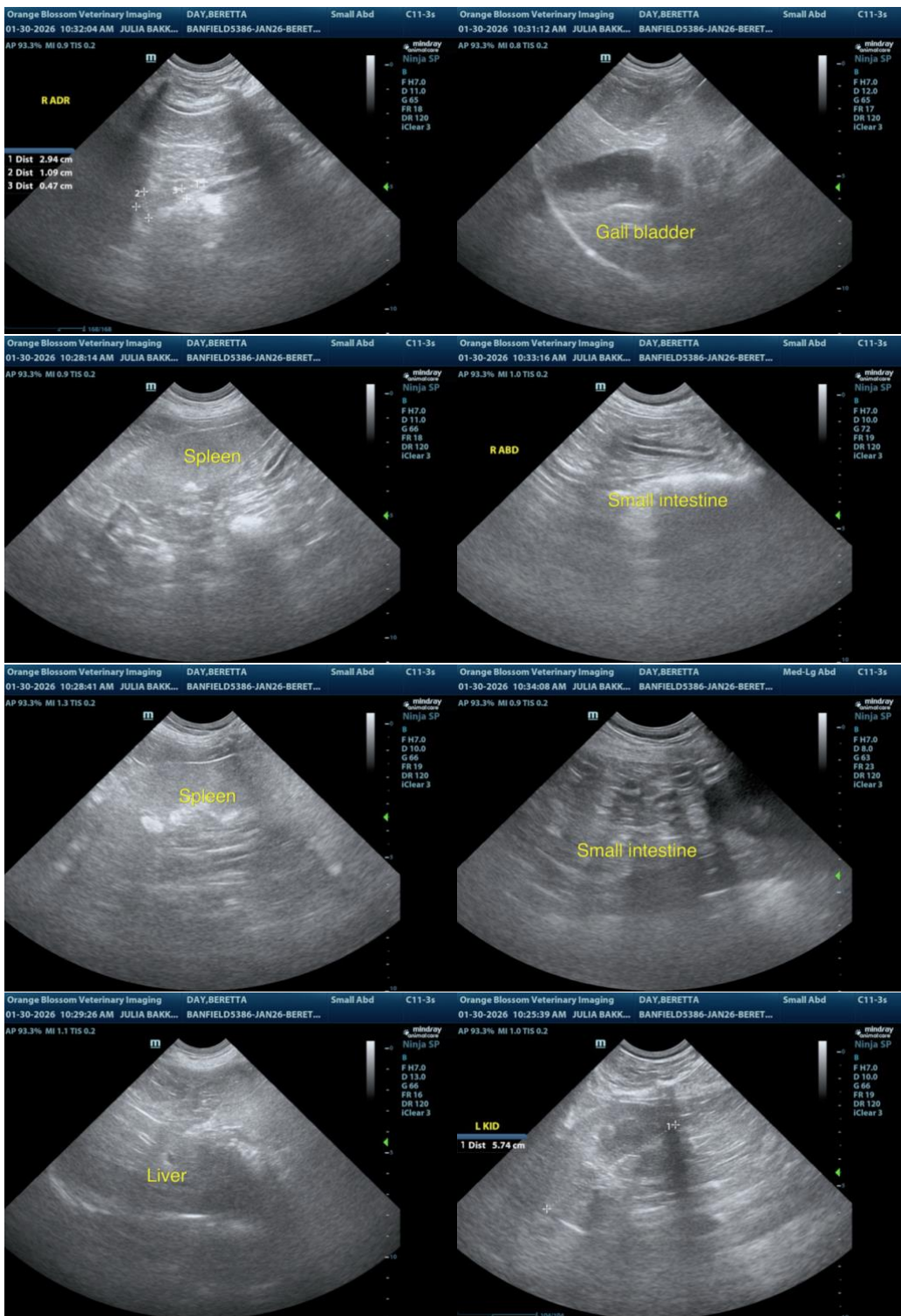
Nicole Day, DVM

**INVOICE**

35656

**DATE**

2/2/26





## PATIENT

Beretta Day

## SPECIES

Canine

## BREED

Husky Border Collie  
Mix

## SEX

Spayed Female

## AGE

12 Years

## WEIGHT

44 Pounds

## INTERPRETED BY

Remo Lobetti BVSc,  
MMedVet, PhD,  
DECVIM

## IMAGING PERFORMED BY

Julia Bakker, DVM

## HOSPITAL NAME

Orange Blossom VI

## REFERRING VET

Nicole Day, DVM

## INVOICE

35656

## DATE

2/2/26

The information and recommendations provided are based on the images presented by the referring veterinarian/sonographer. No evaluation can be communicated regarding pathology that was not visible in the image/video clips provided.

Thank you for this referral. If the clinical or image interpretation does not parallel your findings or if I can be of any further assistance, please contact me.

**Remo Lobetti, BVSc, MMedVet (Med), PhD, Dipl. ECVIM (Internal Medicine)**

[info@sonopath.com](mailto:info@sonopath.com)