



## PATIENT

Pearl Burriss

## SPECIES

Canine

## BREED

French Bulldog

## SEX

Female

## AGE

2 years

## WEIGHT

20 lbs

## INTERPRETED BY

Remo Lobetti, BVSc,  
MMedVet (Med),  
PhD, Dipl. ECVIM

## IMAGING PERFORMED BY

Grace Jayne, CVT

## HOSPITAL NAME

Ark AH

## REFERRING VET

Dr. Downey

## INVOICE

71669

## DATE

2/18/26

## PRESENTING CLINICAL SIGNS

- History of elevated ALT (304)
- Taking "canine hepatic support" supplement

## ULTRASONOGRAPHIC EXAMINATION OF THE ABDOMEN

### *Urinary System*

The urinary bladder is small with a normal thickness and smooth appearance of the wall. Normal anechoic urine with no sediment or uroliths evident.

Normal appearance of the trigone area, proximal urethra, and iliac blood vessels.

Normal appearance and size of the iliac lymph nodes. Ureters not visualized, which can be considered a normal finding.

Normal renal size (left measured 4.0 cm, right measured 4.4 cm), architecture, echogenic appearance, cortico-medullary differentiation, which maintains a 1:3 cortex to medulla ratio, pelvis, and capsule. No infarcts, mineralization or renoliths evident. Normal color flow pattern is evident in both kidneys.

### *Adrenal Glands*

The adrenal glands are not clearly visualized, but appear to be of normal shape, echogenic appearance and size.

### *Spleen*

Normal size and echogenic appearance. Smooth homogenous parenchyma and regular curvilinear capsule. Normal volume of the splenic vasculature without any overt congestion or thrombosis evident. No inflammatory, neoplastic, infarction, or infiltrative changes evident. The spleen measured 1.5 cm in width.

### *Liver*

Normal size, echogenic appearance, portal markings, and regular curvilinear capsule. No nodules or masses evident. Normal appearance of the hepatic and portal vasculature.

### *Gallbladder*

The gallbladder is full containing normal anechoic bile. Normal thickness and echogenic appearance of the wall. Normal size and appearance of the cystic and common bile duct.



## PATIENT

Pearl Burriss

## SPECIES

Canine

## BREED

French Bulldog

## SEX

Female

## AGE

2 years

## WEIGHT

20 lbs

## INTERPRETED BY

Remo Lobetti, BVSc,  
MMedVet (Med),  
PhD, Dipl. ECVIM

## IMAGING PERFORMED BY

Grace Jayne, CVT

## HOSPITAL NAME

Ark AH

## REFERRING VET

Dr. Downey

## INVOICE

71669

## DATE

2/18/26

## *Gastrointestinal*

Normal appearance of the stomach, duodenum, small intestine, ileo-cecal junction, and colon with no loss of layering, 1:3 muscularis to mucosa ratio, normal wall thickness and peristaltic activity, and no distension of the lumen.

## *Pancreas*

The visible sections of the pancreas are of normal size and echogenic appearance with a regular capsule. Normal echogenic appearance of the mesentery and fat surrounding the pancreas.

## *Free Abdomen*

Normal mesenteric lymph nodes.

No ascites evident.

## ULTRASONOGRAPHIC FINDINGS

- Normal ultrasound examination of the abdomen.

## INTERPRETATION OF THE FINDINGS & FURTHER RECOMMENDATIONS

On this ultrasound there is no obvious etiology for the elevated ALT activity.

Although the liver appears ultrasonographically normal, with the elevated ALT an underlying hepatopathy such as reactive hyperplasia, vacuolar and metabolic should still be considered with primary portal vein hyperplasia, a less likely differential diagnosis.

Further assessment would be pre and post prandial bile acids and FNA cytology of the liver.

A tru cut or wedge biopsy of the liver may be required for a final etiological diagnosis.

Specific therapy would be dependent on an etiological diagnosis. Symptomatic management that can be considered would be the use of Ursodiol with regular monitoring of liver enzyme activity.



**PATIENT**

Pearl Burris

**SPECIES**

Canine

**BREED**

French Bulldog

**SEX**

Female

**AGE**

2 years

**WEIGHT**

20 lbs

**INTERPRETED BY**

Remo Lobetti, BVSc,  
MMedVet (Med),  
PhD, Dipl. ECVIM

**IMAGING PERFORMED BY**

Grace Jayne, CVT

**HOSPITAL NAME**

Ark AH

**REFERRING VET**

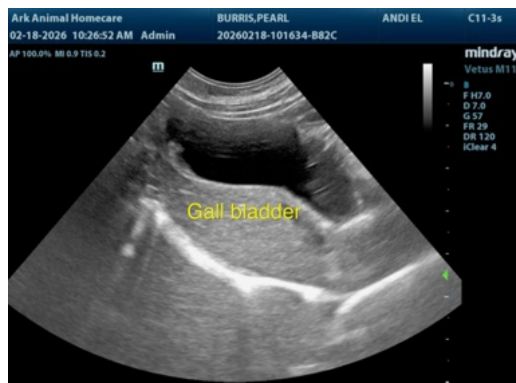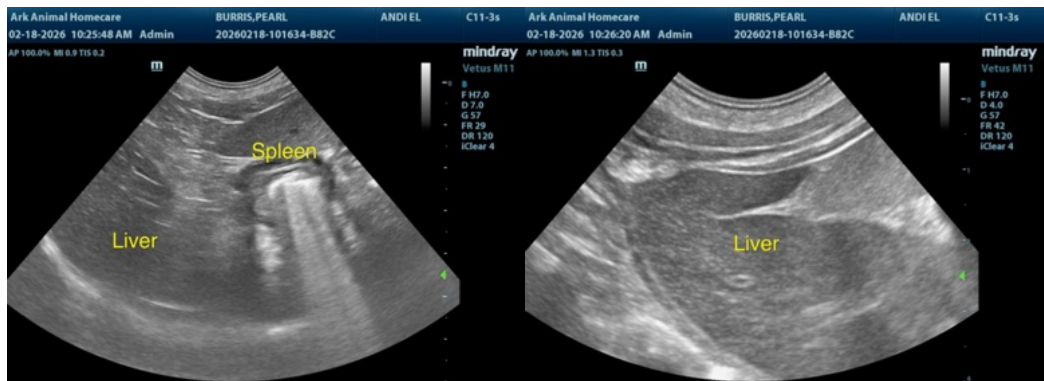
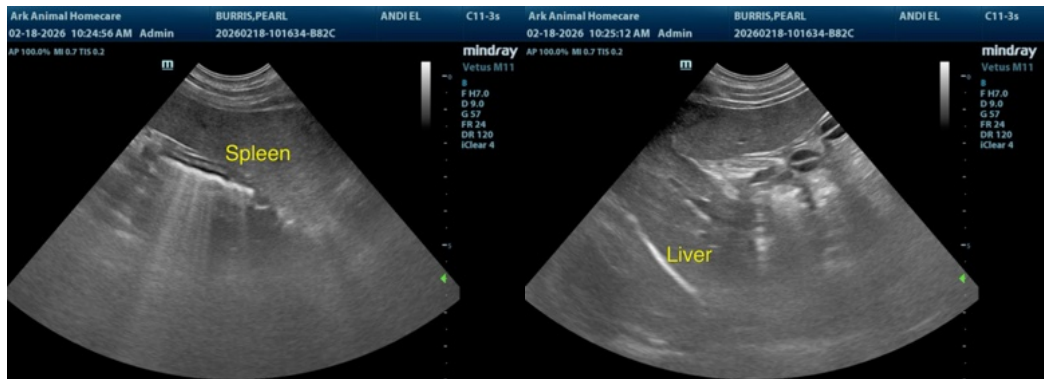Dr. Downey

**INVOICE**

71669

**DATE**

2/18/26



The information and recommendations provided are based on the images presented by the referring veterinarian/sonographer. No evaluation can be communicated regarding pathology that was not visible in the image/video clips provided.

Thank you for this referral. If the clinical or image interpretation does not parallel your findings or if I can be of any further assistance please contact me.

Remo Lobetti, BVSc, MMedVet (Med), PhD, Dipl. ECVIM (Internal Medicine)

[info@sonopath.com](mailto:info@sonopath.com)