



PATIENT

Lady Emig

SPECIES

Canine

BREED

Jack Russell Terrier

SEX

Spayed female

AGE

11 years

WEIGHT

16.5 lbs

INTERPRETED BY

Remo Lobetti, BVSc,
MMedVet (Med),
PhD, Dipl. ECVIM

IMAGING PERFORMED BY

Dr. Tiffany Brady

HOSPITAL NAME

Shiloh VH

REFERRING VET

Dr. Craig

INVOICE

71670

DATE

2/18/26

PRESENTING CLINICAL SIGNS

- P discovered to have significant proteinuria, low albumin and increased ALP and BUN on pre-anesthetic bloodwork for dental prophylaxis.
- Ultrasound to assess for underlying disease
- Urine culture is pending
- 4 Dx negative
- CBC/Chem/UA/T4 performed on 1/20 UP:C 7.0 (increased from 2.7 in October 2025) USG 1.019, inactive sediment with some Ca Ox crystals ALP 135 BUN 35 Chol 505 T4 <0.5

ULTRASONOGRAPHIC EXAMINATION OF THE ABDOMEN

Urinary System

The urinary bladder is small with a normal thickness and smooth appearance of the wall. Normal anechoic urine with no sediment or uroliths evident.

Normal appearance of the trigone area, proximal urethra, and iliac blood vessels.

Normal appearance and size of the iliac lymph nodes. Ureters not visualized, which can be considered a normal finding.

Normal renal size (left measured 5.0 cm, right measured 4.9 cm), architecture, echogenic appearance, cortico-medullary differentiation, which maintains a 1:3 cortex to medulla ratio, pelvis, and capsule. No infarcts, mineralization or renoliths evident. Normal color flow pattern is evident in both kidneys.

Adrenal Glands

Normal shape, echogenic appearance, size, position, and appearance of the visible peri-adrenal vasculature. Left adrenal gland measured 0.44 cm and 0.4 cm in width. The right adrenal gland measured 0.42 cm in width.

Spleen

Normal size and echogenic appearance. Smooth homogenous parenchyma and regular curvilinear capsule. Normal volume of the splenic vasculature without any overt congestion or thrombosis evident. No inflammatory, neoplastic, infarction, or infiltrative changes evident. The spleen measured 2.0 cm in width.

Liver

Normal size, echogenic appearance, portal markings, and regular curvilinear capsule. Focal, non-vascularized, hyperechogenic, parenchymal nodule in the left lobe measuring 1.5 x 1.8 cm in size. No additional nodules or masses evident. Normal appearance of the hepatic and portal vasculature.



PATIENT

Lady Emig

SPECIES

Canine

BREED

Jack Russell Terrier

SEX

Spayed female

AGE

11 years

WEIGHT

16.5 lbs

INTERPRETED BY

Remo Lobetti, BVSc,
MMedVet (Med),
PhD, Dipl. ECVIM

IMAGING PERFORMED BY

Dr. Tiffany Brady

HOSPITAL NAME

Shiloh VH

REFERRING VET

Dr. Craig

INVOICE

71670

DATE

2/18/26

Gallbladder

The gallbladder is full containing a moderate amount of non-adhered, hyperechogenic sediment. Normal thickness and echogenic appearance of the wall. Normal size and appearance of the cystic and common bile duct.

Gastrointestinal

Normal appearance of the stomach, duodenum, small intestine, ileo-cecal junction, and colon with no loss of layering, 1:3 muscularis to mucosa ratio, normal wall thickness and peristaltic activity, and no distension of the lumen.

Pancreas

The visible sections of the pancreas are of normal size and echogenic appearance with a regular capsule. Normal echogenic appearance of the mesentery and fat surrounding the pancreas.

Free Abdomen

Normal mesenteric lymph nodes.

No ascites evident.

ULTRASONOGRAPHIC FINDINGS

- Hepatic nodule.
- Gallbladder sediment.

INTERPRETATION OF THE FINDINGS & FURTHER RECOMMENDATIONS

The likely etiology for the hepatic nodule would be incidental nodular hyperplasia or an organized hematoma or granuloma.

The gallbladder sediment can be considered an incidental finding.

Further assessment of the proteinuria would be blood pressure.

Management of the proteinuria would either be an ace inhibitor or receptor blocker and Omega 3 fatty acid supplementation.



PATIENT

Lady Emig

SPECIES

Canine

BREED

Jack Russell Terrier

SEX

Spayed female

AGE

11 years

WEIGHT

16.5 lbs

INTERPRETED BY

Remo Lobetti, BVSc,
MMedVet (Med),
PhD, Dipl. ECVIM

IMAGING PERFORMED BY

Dr. Tiffany Brady

HOSPITAL NAME

Shiloh VH

REFERRING VET

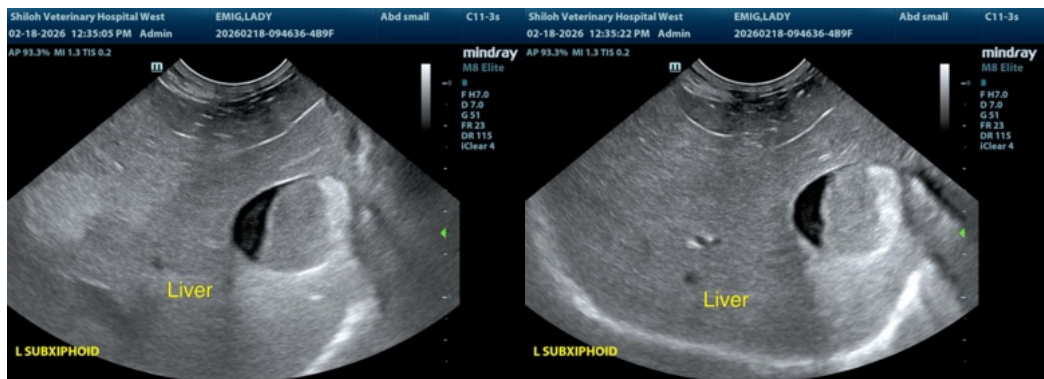
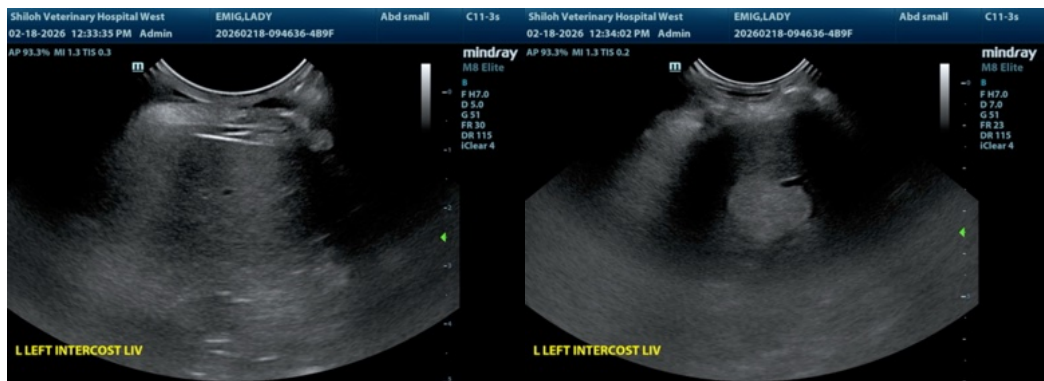
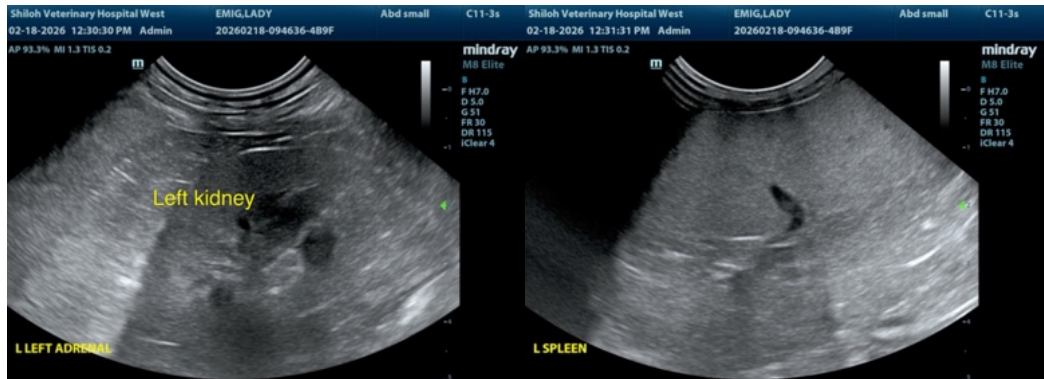
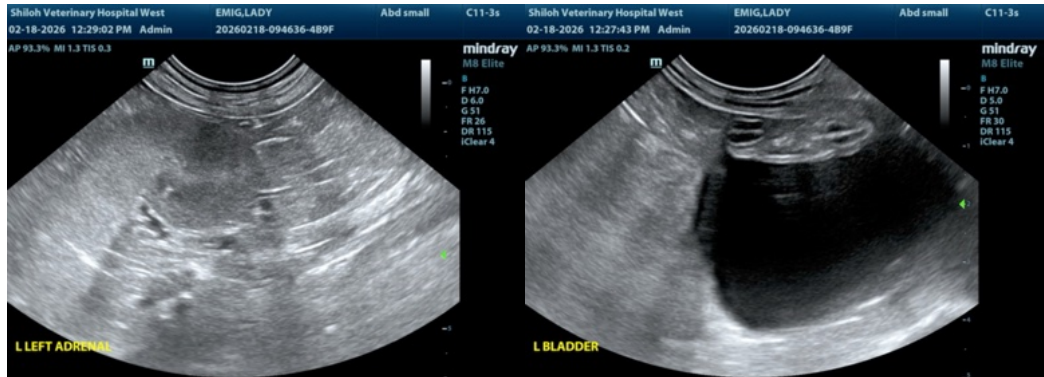
Dr. Craig

INVOICE

71670

DATE

2/18/26





PATIENT

Lady Emig

SPECIES

Canine

BREED

Jack Russell Terrier

SEX

Spayed female

AGE

11 years

WEIGHT

16.5 lbs

INTERPRETED BY

Remo Lobetti, BVSc,
MMedVet (Med),
PhD, Dipl. ECVIM

IMAGING PERFORMED BY

Dr. Tiffany Brady

HOSPITAL NAME

Shiloh VH

REFERRING VET

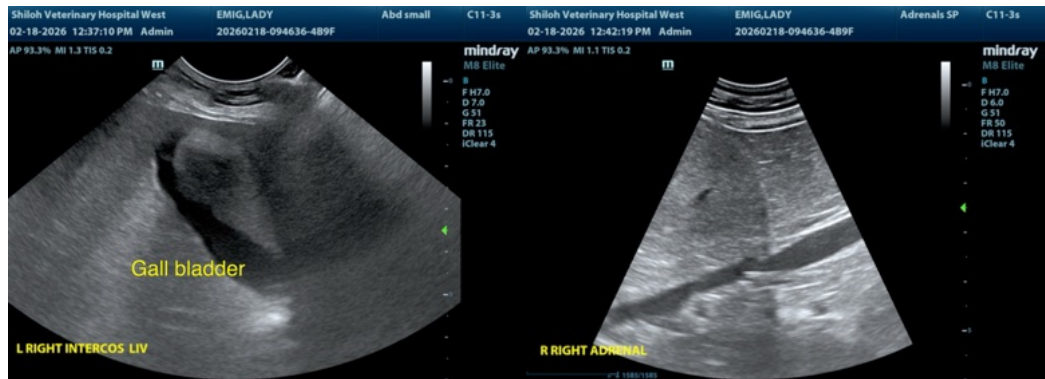Dr. Craig

INVOICE

71670

DATE

2/18/26



The information and recommendations provided are based on the images presented by the referring veterinarian/sonographer. No evaluation can be communicated regarding pathology that was not visible in the image/video clips provided.

Thank you for this referral. If the clinical or image interpretation does not parallel your findings or if I can be of any further assistance please contact me.

Remo Lobetti, BVSc, MMedVet (Med), PhD, Dipl. ECVIM (Internal Medicine)

info@sonopath.com