



PATIENT

Onyx Smith

SPECIES

Canine

BREED

Labrador Retriever Mix

SEX

Neutered male

AGE

10 years

WEIGHT

89.2 lbs

INTERPRETED BY

Remo Lobetti, BVSc,
MMedVet (Med),
PhD, Dipl. ECVIM

IMAGING PERFORMED BY

Dr. Brittney Beigel

HOSPITAL NAME

Bayside Animal
Medical Center

REFERRING VET

Dr. Buchanan

INVOICE

71581

DATE

2/16/26

PRESENTING CLINICAL SIGNS

- Hx of soft stool with frank blood after every bowel movement. Rectal exam WNL. Improvement of stool consistency on HP diet, but still seeing frank blood
- R/o IBD vs neoplasia vs other.
- P was fasted for US scan
- No sedation needed

ULTRASONOGRAPHIC EXAMINATION OF THE ABDOMEN

Urinary System

The urinary bladder is small with a normal thickness and smooth appearance of the wall. Normal anechoic urine with no sediment or uroliths evident.

Normal appearance of the trigone area, proximal urethra, and iliac blood vessels.

Normal appearance and size of the iliac lymph nodes. Ureters not visualized, which can be considered a normal finding.

Normal renal size (left measured 6.7 cm, right measured 7.0 cm), architecture, echogenic appearance, cortico-medullary differentiation, which maintains a 1:3 cortex to medulla ratio, pelvis, and capsule. No infarcts, mineralization or renoliths evident.

The prostate is small and measured 1.2 cm in width.

Adrenal Glands

The left adrenal gland is normal in shape, echogenic appearance, size, position, and appearance of the visible peri-adrenal vasculature. Left adrenal gland measured 0.52 cm and 0.65 cm in width. The right adrenal gland was not clearly visualized, but appears to be of normal shape, echogenic appearance and size.

Spleen

Normal size and echogenic appearance. Smooth homogenous parenchyma and regular curvilinear capsule. Normal volume of the splenic vasculature without any overt congestion or thrombosis evident. No inflammatory, neoplastic, infarction, or infiltrative changes evident. The spleen measured 2.3 cm in width.

Liver

Normal size, echogenic appearance, portal markings, and regular curvilinear capsule. No nodules or masses evident. Normal appearance of the hepatic and portal vasculature.



PATIENT

Onyx Smith

SPECIES

Canine

BREED

Labrador Retriever Mix

SEX

Neutered male

AGE

10 years

WEIGHT

89.2 lbs

INTERPRETED BY

Remo Lobetti, BVSc,
MMedVet (Med),
PhD, Dipl. ECVIM

IMAGING PERFORMED BY

Dr. Brittney Beigel

HOSPITAL NAME

Bayside Animal
Medical Center

REFERRING VET

Dr. Buchanan

INVOICE

71581

DATE

2/16/26

Gallbladder

The gallbladder is full containing normal anechoic bile. Normal thickness and echogenic appearance of the wall. Normal size and appearance of the cystic and common bile duct.

Gastrointestinal

Normal appearance of the stomach, duodenum, small intestine, ileo-cecal junction, and colon with no loss of layering, 1:3 muscularis to mucosa ratio, normal wall thickness and peristaltic activity, and no distension of the lumen. The small intestine measured 0.41 cm.

Pancreas

The visible sections of the pancreas are of normal size and echogenic appearance with a regular capsule. Normal echogenic appearance of the mesentery and fat surrounding the pancreas.

Free Abdomen

Normal mesenteric lymph nodes.

No ascites evident.

ULTRASONOGRAPHIC FINDINGS

- Normal ultrasound examination of the abdomen.

INTERPRETATION OF THE FINDINGS & FURTHER RECOMMENDATIONS

On this ultrasound there is no obvious etiology for the presenting clinical signs.

A colonic polyp or emerging neoplasia would be an important differential diagnosis.

Further assessment would be colonoscopy with biopsies.

Specific therapy would be dependent on an etiological diagnosis.



PATIENT

Onyx Smith

SPECIES

Canine

BREED

Labrador Retriever Mix

SEX

Neutered male

AGE

10 years

WEIGHT

89.2 lbs

INTERPRETED BY

Remo Lobetti, BVSc,
MMedVet (Med),
PhD, Dipl. ECVIM

IMAGING PERFORMED BY

Dr. Brittney Beigel

HOSPITAL NAME

Bayside Animal
Medical Center

REFERRING VET

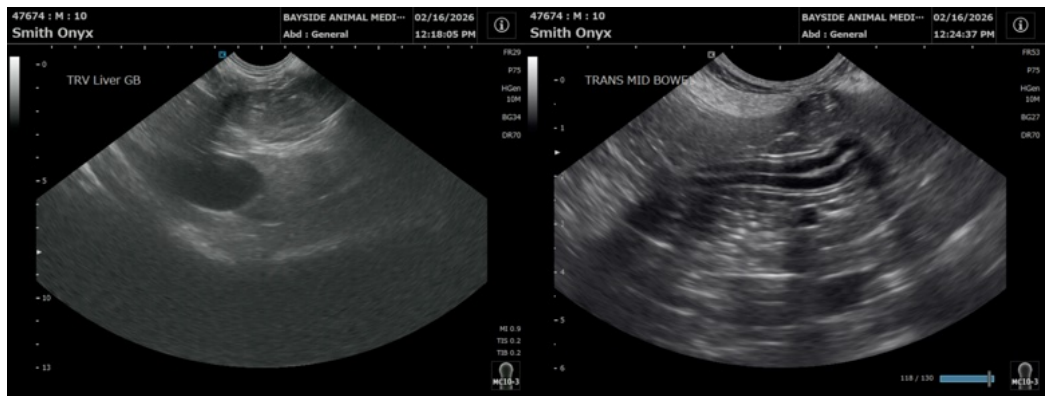
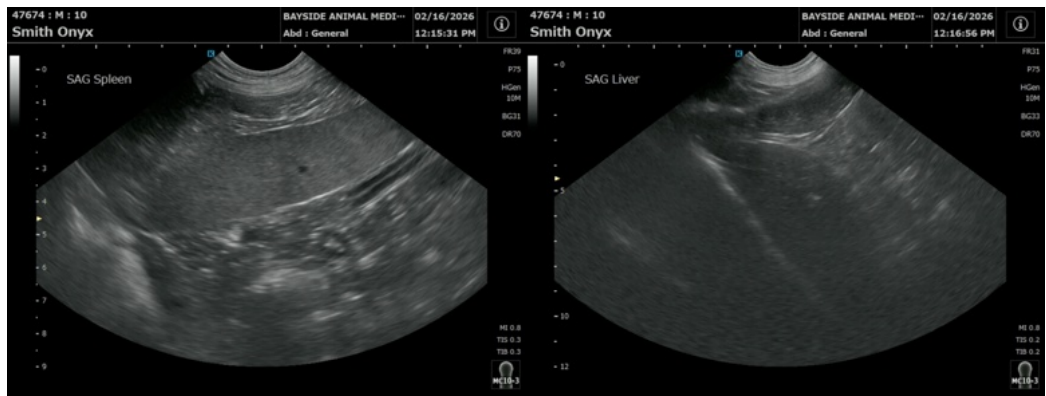
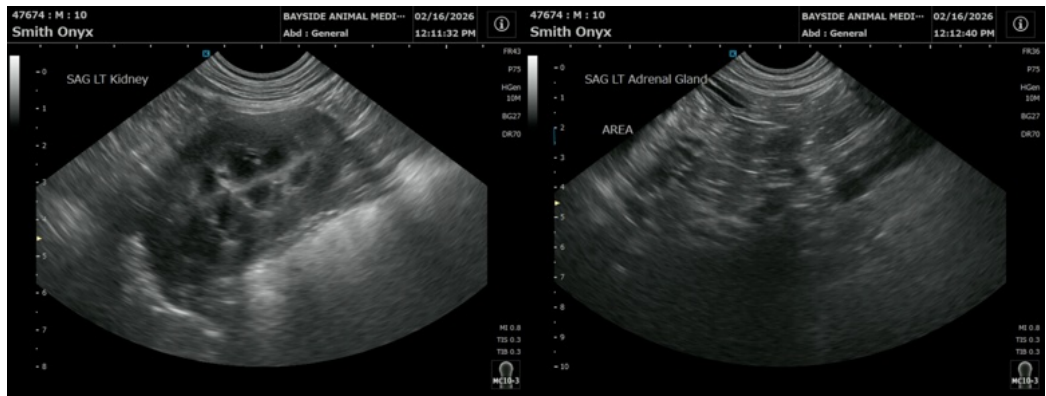
Dr. Buchanan

INVOICE

71581

DATE

2/16/26





PATIENT

Onyx Smith

SPECIES

Canine

BREED

Labrador Retriever Mix

SEX

Neutered male

AGE

10 years

WEIGHT

89.2 lbs

INTERPRETED BY

Remo Lobetti, BVSc,
MMedVet (Med),
PhD, Dipl. ECVIM

IMAGING PERFORMED BY

Dr. Brittney Beigel

HOSPITAL NAME

Bayside Animal
Medical Center

REFERRING VET

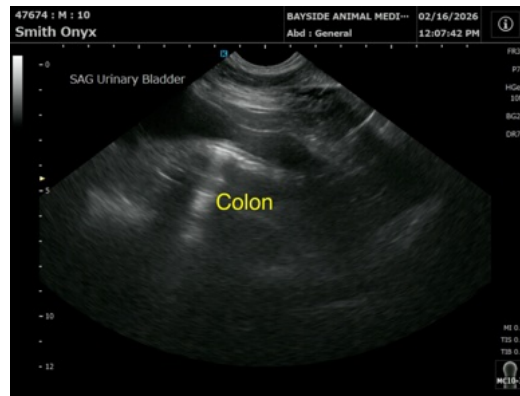
Dr. Buchanan

INVOICE

71581

DATE

2/16/26



The information and recommendations provided are based on the images presented by the referring veterinarian/sonographer. No evaluation can be communicated regarding pathology that was not visible in the image/video clips provided.

Thank you for this referral. If the clinical or image interpretation does not parallel your findings or if I can be of any further assistance please contact me.

Remo Lobetti, BVSc, MMedVet (Med), PhD, Dipl. ECVIM (Internal Medicine)

info@sonopath.com