



## PATIENT

Daisy Miller

## SPECIES

Canine

## BREED

Mix

## SEX

Spayed female

## AGE

12 years

## WEIGHT

22.8 lbs

## INTERPRETED BY

Remo Lobetti, BVSc,  
MMedVet (Med),  
PhD, Dipl. ECVIM

## IMAGING PERFORMED BY

Melissa Rosen

## HOSPITAL NAME

South Bellmore  
Veterinary Group

## REFERRING VET

Dr. Franko

## INVOICE

71601

## DATE

2/16/26

## PRESENTING CLINICAL SIGNS

- Vomiting started yesterday morning/afternoon. Eating very little, no diarrhea. No change in diet but gave 3 milk bones instead of 1 on Saturday
- Dental disease, SQ lipomatous growth left flank ~2cm, hx several years seizures- infrequent and not on any meds, low chronic murmur- no recent echo ALT 256 ALP554 GGT 13 QPL 815 glob 5.9/ TP 9.7

## ULTRASONOGRAPHIC EXAMINATION OF THE ABDOMEN

### *Urinary System*

The urinary bladder is small with a normal thickness and smooth appearance of the wall. Normal anechoic urine with no sediment or uroliths evident.

Normal appearance of the trigone area, proximal urethra, and iliac blood vessels.

Normal appearance and size of the iliac lymph nodes. Ureters not visualized, which can be considered a normal finding.

Normal renal size (left measured 4.5 cm, right measured 4.4 cm), architecture, echogenic appearance, cortico-medullary differentiation, which maintains a 1:3 cortex to medulla ratio, pelvis, and capsule. No infarcts, mineralization or renoliths evident. Normal color flow pattern is evident in both kidneys.

### *Adrenal Glands*

Normal shape, echogenic appearance, size, position, and appearance of the visible peri-adrenal vasculature. Left adrenal gland measured 0.43 cm and 0.53 cm in width. The right adrenal gland measured 0.69 cm and 0.63 cm in width.

### *Spleen*

Normal size and echogenic appearance. Smooth homogenous parenchyma and regular curvilinear capsule. Normal volume of the splenic vasculature without any overt congestion or thrombosis evident. No inflammatory, neoplastic, infarction, or infiltrative changes evident. The spleen measured 1.4 cm in width.

### *Liver*

Normal size, echogenic appearance, portal markings, and regular curvilinear capsule. No nodules or masses evident. Normal appearance of the hepatic and portal vasculature.

### *Gallbladder*

The gallbladder is small containing normal anechoic bile. Normal thickness and echogenic appearance of the wall. Normal size and appearance of the cystic and common bile duct.



## PATIENT

Daisy Miller

## SPECIES

Canine

## BREED

Mix

## SEX

Spayed female

## AGE

12 years

## WEIGHT

22.8 lbs

## INTERPRETED BY

Remo Lobetti, BVSc,  
MMedVet (Med),  
PhD, Dipl. ECVIM

## IMAGING PERFORMED BY

Melissa Rosen

## HOSPITAL NAME

South Bellmore  
Veterinary Group

## REFERRING VET

Dr. Franko

## INVOICE

71601

## DATE

2/16/26

## Gastrointestinal

Normal appearance of the stomach, duodenum, small intestine, ileo-cecal junction, and colon with no loss of layering, 1:3 muscularis to mucosa ratio, normal wall thickness and peristaltic activity, and no distension of the lumen.

## Pancreas

Normal size (left pancreas measured 0.8 cm in width) with a hypoechogenic and coarse appearance and an irregular capsule. Mild increase in the echogenic appearance of the mesentery and fat surrounding the pancreas.

## Free Abdomen

Normal mesenteric lymph nodes.

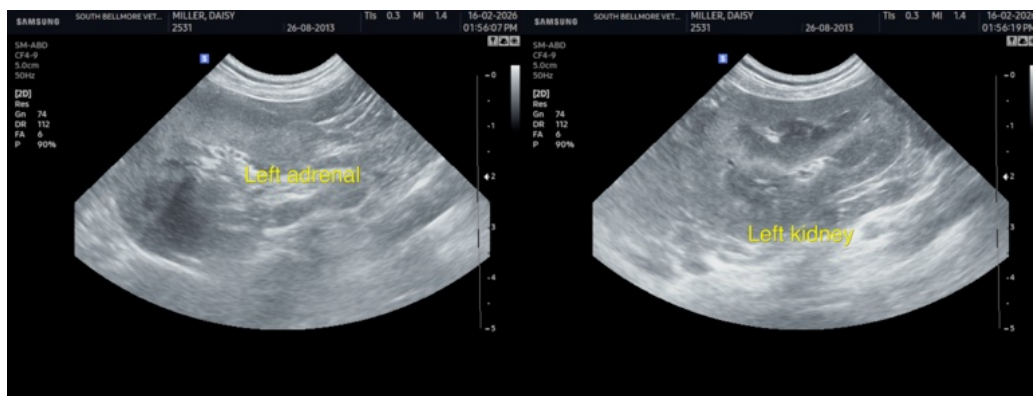
No ascites evident.

## ULTRASONOGRAPHIC FINDINGS

- Pancreatitis.

## INTERPRETATION OF THE FINDINGS & FURTHER RECOMMENDATIONS

Management of the pancreatitis would be fluid therapy, antiemetics, analgesics and feeding small frequent meals of a low fat intestinal diet.





### PATIENT

Daisy Miller

### SPECIES

Canine

### BREED

Mix

### SEX

Spayed female

### AGE

12 years

### WEIGHT

22.8 lbs

### INTERPRETED BY

Remo Lobetti, BVSc,  
MMedVet (Med),  
PhD, Dipl. ECVIM

### IMAGING PERFORMED BY

Melissa Rosen

### HOSPITAL NAME

South Bellmore  
Veterinary Group

### REFERRING VET

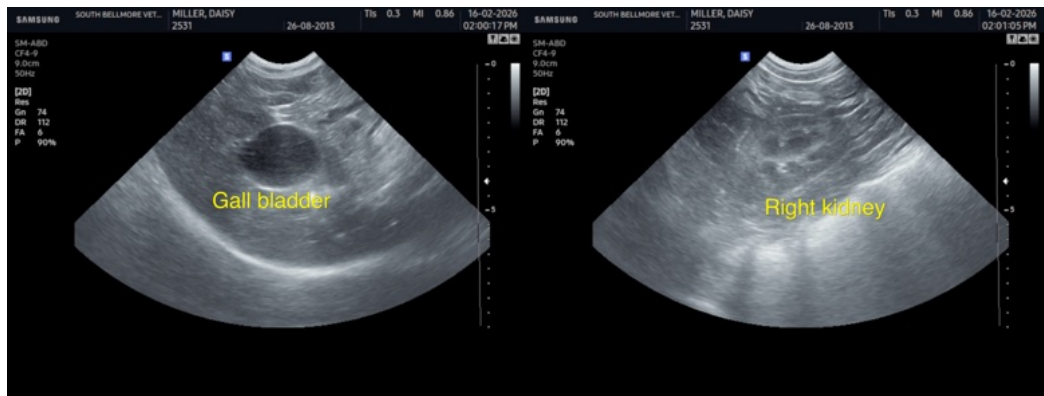
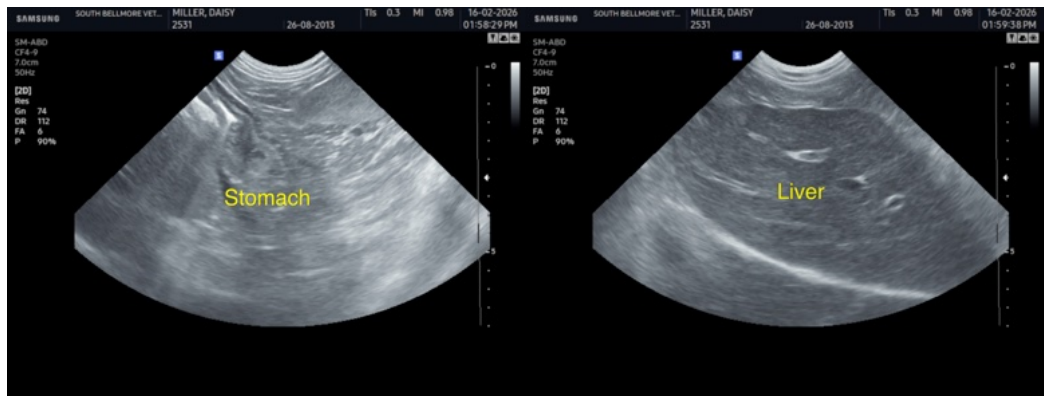
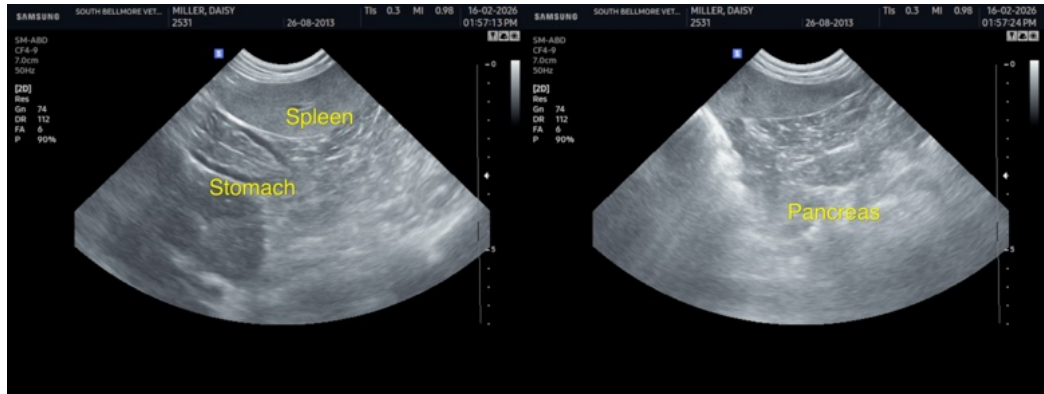
Dr. Franko

### INVOICE

71601

### DATE

2/16/26





## PATIENT

Daisy Miller

## SPECIES

Canine

## BREED

Mix

## SEX

Spayed female

## AGE

12 years

## WEIGHT

22.8 lbs

## INTERPRETED BY

Remo Lobetti, BVSc,  
MMedVet (Med),  
PhD, Dipl. ECVIM

## IMAGING PERFORMED BY

Melissa Rosen

## HOSPITAL NAME

South Bellmore  
Veterinary Group

## REFERRING VET

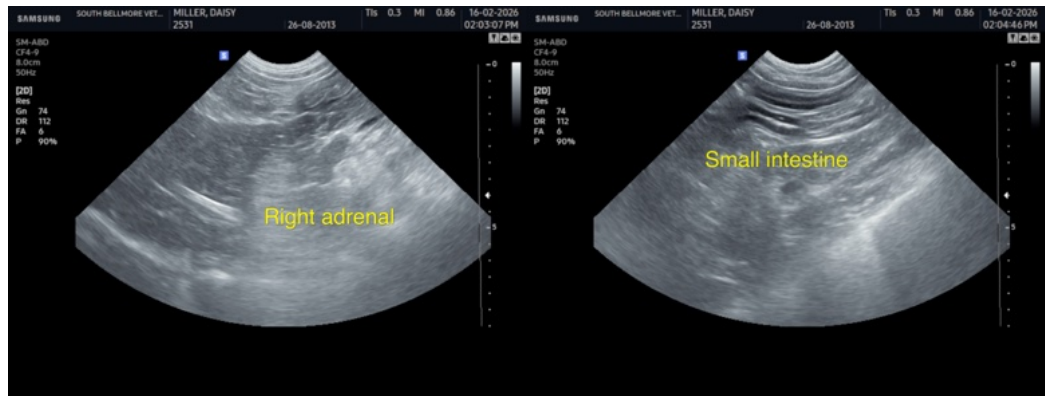
Dr. Franko

## INVOICE

71601

## DATE

2/16/26



The information and recommendations provided are based on the images presented by the referring veterinarian/sonographer. No evaluation can be communicated regarding pathology that was not visible in the image/video clips provided.

Thank you for this referral. If the clinical or image interpretation does not parallel your findings or if I can be of any further assistance please contact me.

Remo Lobetti, BVSc, MMedVet (Med), PhD, Dipl. ECVIM (Internal Medicine)

[info@sonopath.com](mailto:info@sonopath.com)