

PATIENT

Teddy Murphy

SPECIES

Canine

BREED

Mix

SEX

Neutered male

AGE

6 years

WEIGHT

29.6 lbs

INTERPRETED BY

Remo Lobetti, BVSc,
MMedVet (Med), PhD,
Dipl. ECVIM (Internal
Medicine)

IMAGING PERFORMED BY

Denise Bruno, LVT,
RDMS

HOSPITAL NAME

Kenilworth AH

REFERRING VET

Dr. Mansour

INVOICE

71527

DATE

2/12/26

PRESENTING CLINICAL SIGNS

- Globulin, ALT + AST elevated. Evaluate abdomen for neoplasia. Labs attached.

ULTRASONOGRAPHIC EXAMINATION OF THE ABDOMEN

Urinary System

The urinary bladder is small, almost empty urinary bladder with a normal thickness and smooth appearance of the wall. Normal anechoic urine with no sediment or uroliths evident.

Normal appearance of the trigone area, proximal urethra, and iliac blood vessels.

Normal appearance and size of the iliac lymph nodes. Ureters not visualized, which can be considered a normal finding.

Normal renal size (left measured 4.8 cm, right measured 4.9 cm), architecture, echogenic appearance, cortico-medullary differentiation, which maintains a 1:3 cortex to medulla ratio, pelvis, and capsule. No infarcts, mineralization or renoliths evident. Normal color flow pattern is evident in both kidneys.

The prostate is small and hypoechogenic measuring 1.0 cm in length.

Adrenal Glands

Normal shape, echogenic appearance, size, position, and appearance of the visible peri-adrenal vasculature. The left adrenal gland measured 2.26 cm in length x 0.71 cm and 0.42 cm in width. The right adrenal gland measured 2.57 cm in length x 0.51 cm and 0.56 cm in width.

Spleen

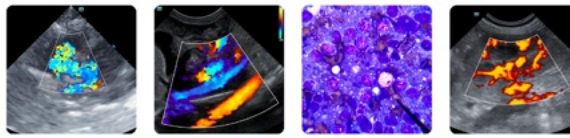
Normal size and echogenic appearance. Smooth homogenous parenchyma and regular curvilinear capsule. Normal volume of the splenic vasculature without any overt congestion or thrombosis evident. No inflammatory, neoplastic, infarction, or infiltrative changes evident. The spleen measured 1.2 cm in width.

Liver

Normal size, echogenic appearance, prominent portal markings, and regular curvilinear capsule. No nodules or masses evident. Normal appearance of the hepatic and portal vasculature.

Gallbladder

The gallbladder is full containing a moderate amount of non-adhered hyperechogenic sediment. Normal thickness and echogenic appearance of the wall. Normal size and appearance of the cystic and common bile duct.



PATIENT

Teddy Murphy

SPECIES

Canine

BREED

Mix

SEX

Neutered male

AGE

6 years

WEIGHT

29.6 lbs

INTERPRETED BY

Remo Lobetti, BVSc,
MMedVet (Med), PhD,
Dipl. ECVIM (Internal
Medicine)

**IMAGING
PERFORMED BY**

Denise Bruno, LVT,
RDMS

HOSPITAL NAME

Kenilworth AH

REFERRING VET

Dr. Mansour

INVOICE

71527

DATE

2/12/26

Gastrointestinal

Normal appearance of the stomach, duodenum, small intestine, ileo-cecal junction, and colon with no loss of layering, 1:3 muscularis to mucosa ratio, normal wall thickness and peristaltic activity, and no distension of the lumen. The small intestine measured up to 0.35 cm.

Pancreas

The visible sections of the pancreas are of normal size and echogenic appearance with a regular capsule. Normal echogenic appearance of the mesentery and fat surrounding the pancreas.

Free Abdomen

Normal mesenteric lymph nodes.

No ascites evident.

ULTRASONOGRAPHIC FINDINGS

- Hepatopathy.
- Gallbladder sediment.

INTERPRETATION OF THE FINDINGS & FURTHER RECOMMENDATIONS

Etiologies for the hepatopathy would be reactive hyperplasia, vacuolar, metabolic and cholangitis.

Although the gallbladder sediment is most likely an incidental finding, monitoring for the development of a mucocele would be recommended.

Further assessment would be FNA cytology of the liver. However, a tru cut or wedge biopsy may be required for a final etiological diagnosis.

Specific therapy would be dependent on an etiological diagnosis.

Symptomatic management that could be considered for both the hepatopathy and the gallbladder sediment would be the use of Ursodiol with regular monitoring of liver enzyme activity.



PATIENT

Teddy Murphy

SPECIES

Canine

BREED

Mix

SEX

Neutered male

AGE

6 years

WEIGHT

29.6 lbs

INTERPRETED BY

Remo Lobetti, BVSc,
 MMedVet (Med), PhD,
 Dipl. ECVIM (Internal
 Medicine)

IMAGING PERFORMED BY

Denise Bruno, LVT,
 RDMS

HOSPITAL NAME

Kenilworth AH

REFERRING VET

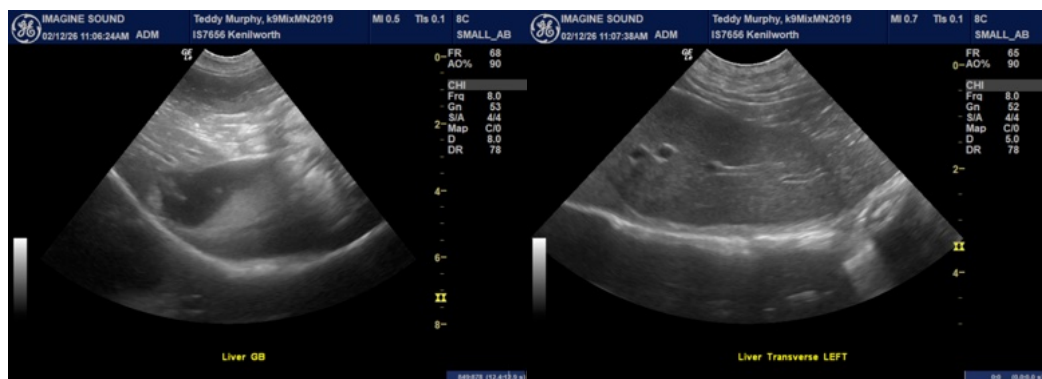
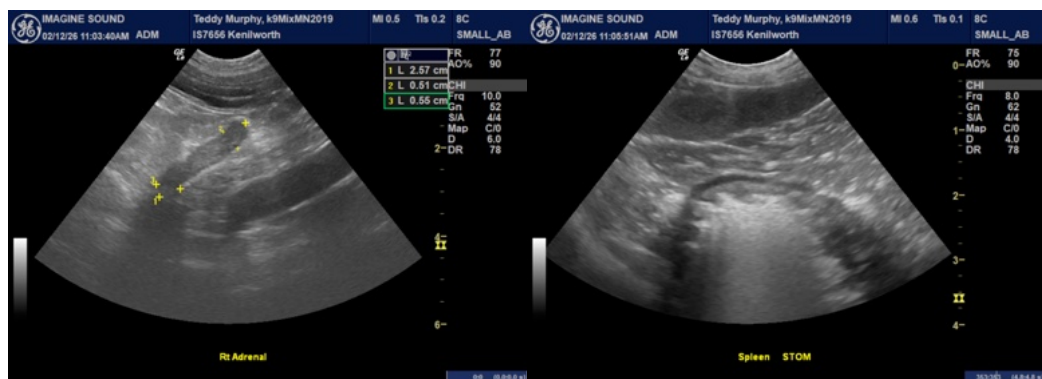
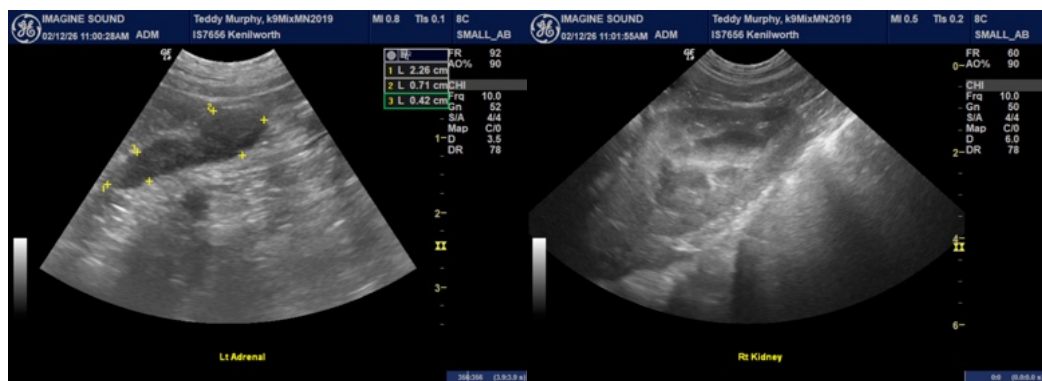
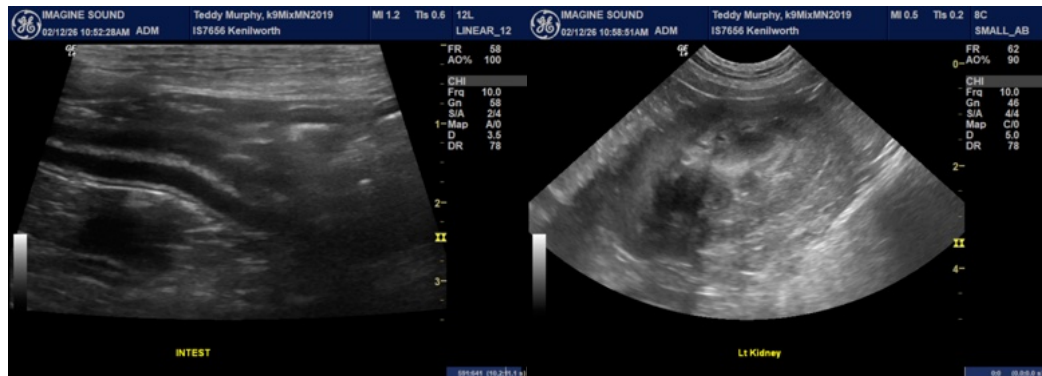
Dr. Mansour

INVOICE

71527

DATE

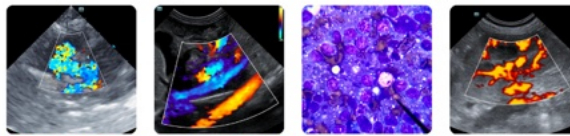
2/12/26



Imaging
performed by



dbimagesound@gmail.com
917-647-4318



Clinical Sonography & Telecytology
Educational Teleconsultation Services™

SonoPath

FOSTERING THE ART OF VETERINARY MEDICINE™

SonoPath.com info@sonopath.com 1.800.838.4268

PATIENT

Teddy Murphy

SPECIES

Canine

BREED

Mix

SEX

Neutered male

AGE

6 years

WEIGHT

29.6 lbs

INTERPRETED BY

Remo Lobetti, BVSc,
MMedVet (Med), PhD,
Dipl. ECVIM (Internal
Medicine)

IMAGING PERFORMED BY

Denise Bruno, LVT,
RDMS

HOSPITAL NAME

Kenilworth AH

REFERRING VET

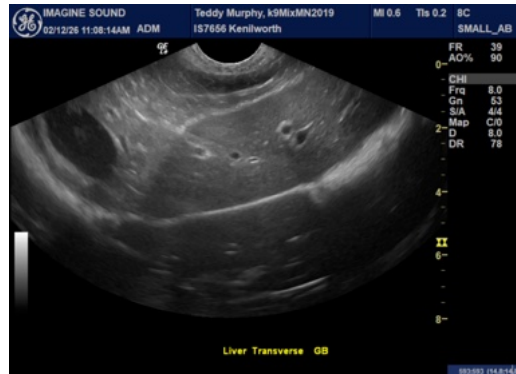
Dr. Mansour

INVOICE

71527

DATE

2/12/26



The information and recommendations provided are based on the images presented by the referring veterinarian/sonographer. No evaluation can be communicated regarding pathology that was not visible in the image/video clips provided.

Thank you for this referral. If the clinical or image interpretation does not parallel your findings or if I can be of any further assistance please contact me.

Remo Lobetti, BVSc, MMedVet (Med), PhD, Dipl. ECVIM (Internal Medicine)

info@sonopath.com