



PATIENT

Sebastian Asarisi

SPECIES

Canine

BREED

German Shepherd

SEX

Neutered male

AGE

7 years

WEIGHT

72 lbs

INTERPRETED BY

Remo Lobetti, BVSc,
MMedVet (Med),
PhD, Dipl. ECVIM

IMAGING PERFORMED BY

Dr. Julia Wiederholt

HOSPITAL NAME

Dreaming Summit AH

REFERRING VET

Dr. Julia Wiederholt

INVOICE

71525

DATE

2/12/26

PRESENTING CLINICAL SIGNS

- Clinically acting normal at home with no abnormalities noted on recent exam. Annual labwork run to recheck Valley Fever (currently on fluconazole for treatment). New azotemia identified on said labs.
- SDMA 20 (normal 14), creatinine 4.0 (normal 1.5), BUN 67 (normal 31), globulin 4.3 (normal 4.0), USG 1.012, occasional waxy casts

ULTRASONOGRAPHIC EXAMINATION OF THE ABDOMEN

Urinary System

The urinary bladder is small with a normal thickness and smooth appearance of the wall. Normal anechoic urine with no sediment or uroliths evident.

Normal appearance of the trigone area, proximal urethra, and iliac blood vessels.

Normal appearance and size of the iliac lymph nodes. Ureters not visualized, which can be considered a normal finding.

Normal left renal size (left measured 7.6 cm), architecture, echogenic appearance, cortico-medullary differentiation, which maintains a 1:3 cortex to medulla ratio, pelvis, and capsule. No infarcts, mineralization or renoliths evident. The left kidney had a normal color flow pattern.

The right kidney was poorly visualized.

The prostate is small and hypoechogenic.

Adrenal Glands

The left adrenal gland is normal in shape, echogenic appearance, size, position, and appearance of the visible peri-adrenal vasculature. Left adrenal gland measured 0.44 cm and 0.42 cm in width. The right adrenal gland was not visualized.

Spleen

Normal size and echogenic appearance. Smooth homogenous parenchyma and regular curvilinear capsule. Normal volume of the splenic vasculature without any overt congestion or thrombosis evident. No inflammatory, neoplastic, infarction, or infiltrative changes evident. The spleen measured 2.3 cm in width.

Liver

Normal size, echogenic appearance, portal markings, and regular curvilinear capsule. No nodules or masses evident. Normal appearance of the hepatic and portal vasculature.



PATIENT

Sebastian Asarisi

SPECIES

Canine

BREED

German Shepherd

SEX

Neutered male

AGE

7 years

WEIGHT

72 lbs

INTERPRETED BY

Remo Lobetti, BVSc,
MMedVet (Med),
PhD, Dipl. ECVIM

IMAGING PERFORMED BY

Dr. Julia Wiederholt

HOSPITAL NAME

Dreaming Summit AH

REFERRING VET

Dr. Julia Wiederholt

INVOICE

71525

DATE

2/12/26

Gallbladder

The gallbladder is full containing a small amount of non-adhered, hyperechogenic sediment. Normal thickness and echogenic appearance of the wall. Normal size and appearance of the cystic and common bile duct.

Gastrointestinal

Normal appearance of the stomach, duodenum, small intestine, ileo-cecal junction, and colon with no loss of layering, 1:3 muscularis to mucosa ratio, normal wall thickness and peristaltic activity, and no distension of the lumen.

Pancreas

The visible sections of the pancreas are of normal size and echogenic appearance with a regular capsule. Normal echogenic appearance of the mesentery and fat surrounding the pancreas.

Free Abdomen

Normal mesenteric lymph nodes.

No ascites evident.

ULTRASONOGRAPHIC FINDINGS

Gallbladder sediment.

INTERPRETATION OF THE FINDINGS & FURTHER RECOMMENDATIONS

In essence a normal ultrasound examination of the abdomen as the gallbladder sediment can be considered an incidental finding.

Although the left kidney appears ultrasonographically normal, this does not rule out renal disease.

Further assessment would be UPC, possibly urine culture, urine cystatin B and blood pressure.

Specific therapy would be dependent on an etiological diagnosis.



PATIENT

Sebastian Asarisi

SPECIES

Canine

BREED

German Shepherd

SEX

Neutered male

AGE

7 years

WEIGHT

72 lbs

INTERPRETED BY

Remo Lobetti, BVSc,
MMedVet (Med),
PhD, Dipl. ECVIM

IMAGING PERFORMED BY

Dr. Julia Wiederholt

HOSPITAL NAME

Dreaming Summit AH

REFERRING VET

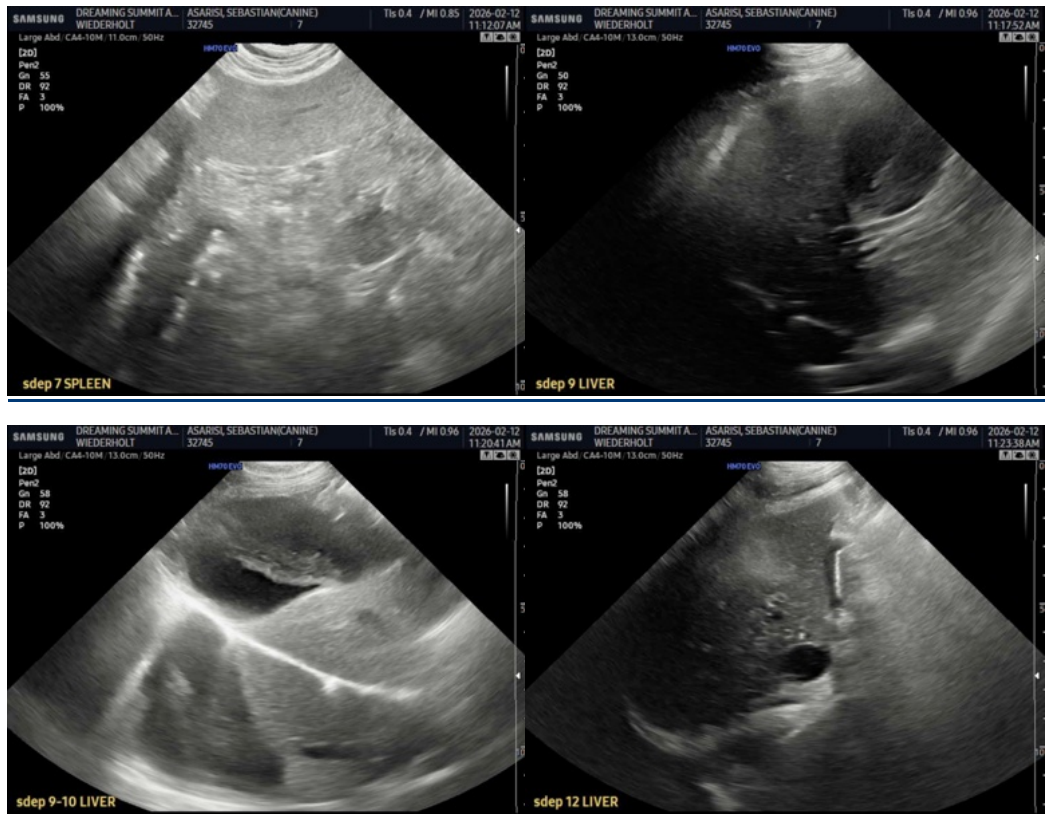
Dr. Julia Wiederholt

INVOICE

71525

DATE

2/12/26



The information and recommendations provided are based on the images presented by the referring veterinarian/sonographer. No evaluation can be communicated regarding pathology that was not visible in the image/video clips provided.

Thank you for this referral. If the clinical or image interpretation does not parallel your findings or if I can be of any further assistance please contact me.

Remo Lobetti, BVSc, MMedVet (Med), PhD, Dipl. ECVIM (Internal Medicine)

info@sonopath.com