



PATIENT

Lily Grace Nelson

SPECIES

Canine

BREED

Golden Retriever

SEX

Female

AGE

1 year

WEIGHT

50 lbs

INTERPRETED BY

Remo Lobetti, BVSc,
MMedVet (Med),
PhD, Dipl. ECVIM

IMAGING PERFORMED BY

Grace Jayne CVT

HOSPITAL NAME

Ark Animal Homecare

REFERRING VET

Dr. Cronin

INVOICE

71519

DATE

2/12/26

PRESENTING CLINICAL SIGNS

- Continued bloody vaginal discharge for the last few weeks, but this has slowed down. Owner has been keeping her clean and wiping her, a few blood spots were seen over the weekend and today no blood has been noted. Unsure of exactly when heat cycle started but may have been going on up to about 6 weeks at this point. She is eating/drinking normally and acting fine otherwise.
- Swollen vulva with scant straw-colored vaginal discharge vaginal cytology: Intermediate cells with ++neutrophils with both intra and extracellular rods and cocci bacteria - both healthy and dogs with reproductive related infection can have presence of bacteria in this case the bacterial population is mixed and somewhat increased from what I would normally expect

ULTRASONOGRAPHIC EXAMINATION OF THE ABDOMEN

Urinary System

The urinary bladder is small with a normal thickness and smooth appearance of the wall. Normal anechoic urine with no sediment or uroliths evident.

Normal appearance of the trigone area, proximal urethra, and iliac blood vessels.

Normal appearance and size of the iliac lymph nodes. Ureters not visualized, which can be considered a normal finding.

Normal renal size (left measured 6.0 cm, right measured 6.2 cm), architecture, echogenic appearance, cortico-medullary differentiation, which maintains a 1:3 cortex to medulla ratio, pelvis, and capsule. No infarcts, mineralization or renoliths evident. Normal color flow pattern is evident in both kidneys.

The visible right ovary measured 1.2 x 2.6 cm in size with few, cystic structures present. The right ovary, uterine body and uterine horns were not visualized.

Adrenal Glands

The left adrenal gland is normal in shape, echogenic appearance, size, position, and appearance of the visible peri-adrenal vasculature. Left adrenal gland measured 0.4 cm in width. The right adrenal gland was poorly visualized, but appears to be of normal shape, echogenic appearance and size.

Spleen

Normal size and echogenic appearance. Smooth homogenous parenchyma and regular curvilinear capsule. Normal volume of the splenic vasculature without any overt congestion or thrombosis evident. No inflammatory, neoplastic, infarction, or infiltrative changes evident. The spleen measures 2.5 cm in width.



PATIENT

Lily Grace Nelson

SPECIES

Canine

BREED

Golden Retriever

SEX

Female

AGE

1 year

WEIGHT

50 lbs

INTERPRETED BY

Remo Lobetti, BVSc,
MMedVet (Med),
PhD, Dipl. ECVIM

IMAGING PERFORMED BY

Grace Jayne CVT

HOSPITAL NAME

Ark Animal Homecare

REFERRING VET

Dr. Cronin

INVOICE

71519

DATE

2/12/26

Liver

Normal size, echogenic appearance, portal markings, and regular curvilinear capsule. No nodules or masses evident. Normal appearance of the hepatic and portal vasculature.

Gallbladder

The gallbladder is full containing normal anechoic bile. Normal thickness and echogenic appearance of the wall. Normal size and appearance of the cystic and common bile duct.

Gastrointestinal

Normal appearance of the stomach, duodenum, small intestine, ileo-cecal junction, and colon with no loss of layering, 1:3 muscularis to mucosa ratio, normal wall thickness and peristaltic activity, and no distension of the lumen.

Pancreas

The visible sections of the pancreas are of normal size and echogenic appearance with a regular capsule. Normal echogenic appearance of the mesentery and fat surrounding the pancreas.

Free Abdomen

Normal mesenteric lymph nodes.

No ascites evident.

ULTRASONOGRAPHIC FINDINGS

- Cystic left ovary.

INTERPRETATION OF THE FINDINGS & FURTHER RECOMMENDATIONS

The appearance of the left ovary could account for the presenting clinical signs.

Consultation with the reproductive specialist would be recommended.



PATIENT

Lily Grace Nelson

SPECIES

Canine

BREED

Golden Retriever

SEX

Female

AGE

1 year

WEIGHT

50 lbs

INTERPRETED BY

Remo Lobetti, BVSc,
MMedVet (Med),
PhD, Dipl. ECVIM

IMAGING PERFORMED BY

Grace Jayne CVT

HOSPITAL NAME

Ark Animal Homecare

REFERRING VET

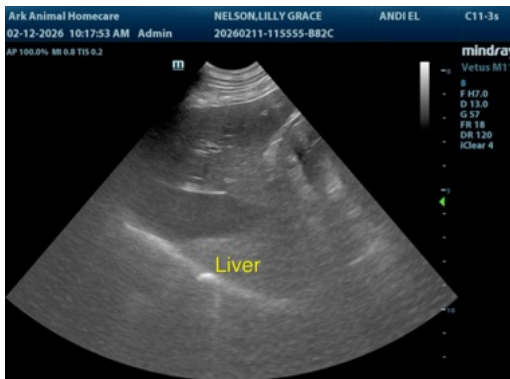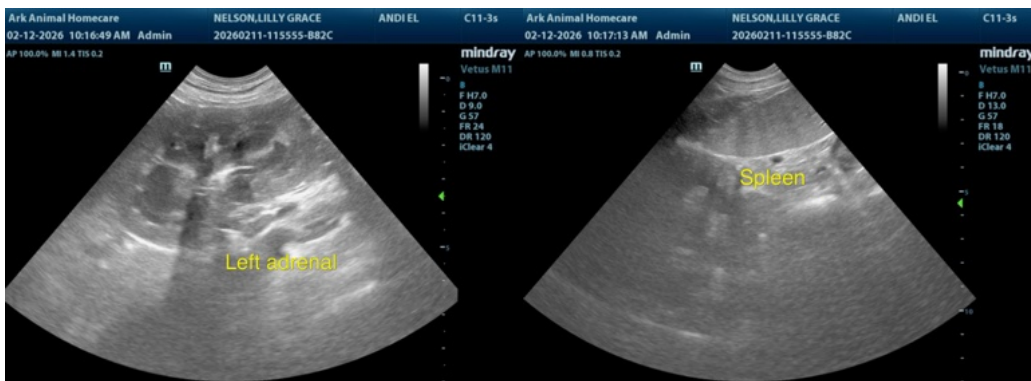
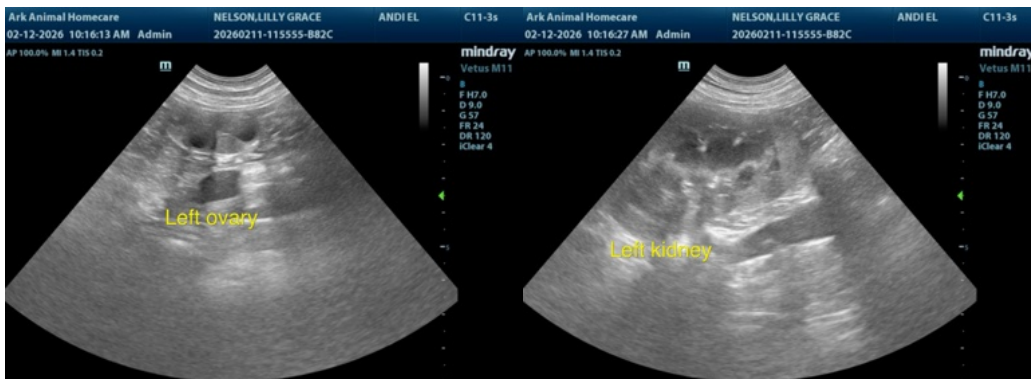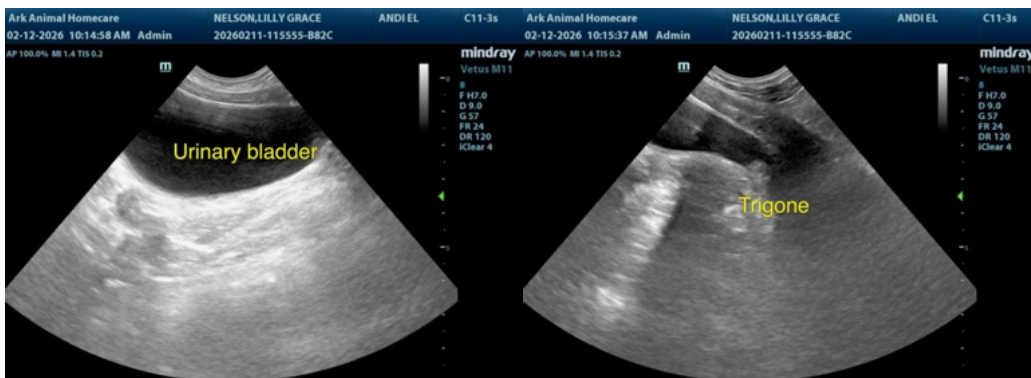
Dr. Cronin

INVOICE

71519

DATE

2/12/26





PATIENT

Lily Grace Nelson

SPECIES

Canine

BREED

Golden Retriever

SEX

Female

AGE

1 year

WEIGHT

50 lbs

INTERPRETED BY

Remo Lobetti, BVSc,
MMedVet (Med),
PhD, Dipl. ECVIM

IMAGING PERFORMED BY

Grace Jayne CVT

HOSPITAL NAME

Ark Animal Homecare

REFERRING VET

Dr. Cronin

INVOICE

71519

DATE

2/12/26

The information and recommendations provided are based on the images presented by the referring veterinarian/sonographer. No evaluation can be communicated regarding pathology that was not visible in the image/video clips provided.

Thank you for this referral. If the clinical or image interpretation does not parallel your findings or if I can be of any further assistance please contact me.

Remo Lobetti, BVSc, MMedVet (Med), PhD, Dipl. ECVIM (Internal Medicine)

info@sonopath.com