



PATIENT

Jenny Coelho Kerhoff

SPECIES

Canine

BREED

Small Mix

SEX

Spayed female

AGE

10 years

WEIGHT

17 lbs

INTERPRETED BY

Remo Lobetti, BVSc,
MMedVet (Med),
PhD, Dipl. ECVIM

IMAGING PERFORMED BY

Dr. Casper

HOSPITAL NAME

Hometown AH Florida

REFERRING VET

Dr. Casper

INVOICE

71430

DATE

2/10/26

PRESENTING CLINICAL SIGNS

- Hx of controlled diabetes on 6 units insulin Q12. Last fructosamine 322. Controlled KCS OU
- On parasite prevention.
- No c/s/v/d
- CBC- mild leukopenia (5.2), mild eosinopenia (0.099) Chem- mild hypochloremia (104), mild inc ALP (434), mod hypercholesterolemia (551) UA - SG 1012, otherwise nsf. Urine culture - NEG TT4- 2.2

ULTRASONOGRAPHIC EXAMINATION OF THE ABDOMEN

Urinary System

The urinary bladder is full with a normal thickness and smooth appearance of the wall. Normal anechoic urine with no sediment or uroliths evident.

Normal appearance of the trigone area, proximal urethra, and iliac blood vessels.

Normal appearance and size of the iliac lymph nodes. Ureters not visualized, which can be considered a normal finding.

Normal renal size (left measured 5.0 cm, right measured 4.2 cm), architecture, echogenic appearance, cortico-medullary differentiation, which maintains a 1:3 cortex to medulla ratio, pelvis, and capsule. No infarcts, mineralization or renoliths evident.

Adrenal Glands

Normal shape, echogenic appearance, size, position, and appearance of the visible peri-adrenal vasculature. Left adrenal gland measured 0.49 cm and 0.52 cm in width. The right adrenal gland measured 0.46 cm and 0.64 cm in width.

Spleen

Normal size and echogenic appearance. Smooth homogenous parenchyma and regular curvilinear capsule. Normal volume of the splenic vasculature without any overt congestion or thrombosis evident. Incidental myelolipoma is present. No inflammatory, neoplastic, infarction, or infiltrative changes evident. The spleen measured 1.2 cm in width.

Liver

Normal size, echogenic appearance, portal markings, and regular curvilinear capsule. No nodules or masses evident. Normal appearance of the hepatic and portal vasculature.



PATIENT

Jenny Coelho Kerhoff

SPECIES

Canine

BREED

Small Mix

SEX

Spayed female

AGE

10 years

WEIGHT

17 lbs

INTERPRETED BY

Remo Lobetti, BVSc,
MMedVet (Med),
PhD, Dipl. ECVIM

IMAGING PERFORMED BY

Dr. Casper

HOSPITAL NAME

Hometown AH Florida

REFERRING VET

Dr. Casper

INVOICE

71430

DATE

2/10/26

Gallbladder

The gallbladder is full containing a small amount of non-adhered, hyperechogenic sediment. Normal thickness and echogenic appearance of the wall. Normal size and appearance of the cystic and common bile duct.

Gastrointestinal

Normal appearance of the stomach, duodenum, small intestine, ileo-cecal junction, and colon with no loss of layering, 1:3 muscularis to mucosa ratio, normal wall thickness and peristaltic activity, and no distension of the lumen. Fecal material is present within the colon.

Pancreas

The visible sections of the pancreas are of normal size and echogenic appearance with a regular capsule. Normal echogenic appearance of the mesentery and fat surrounding the pancreas.

Free Abdomen

Normal mesenteric lymph nodes.

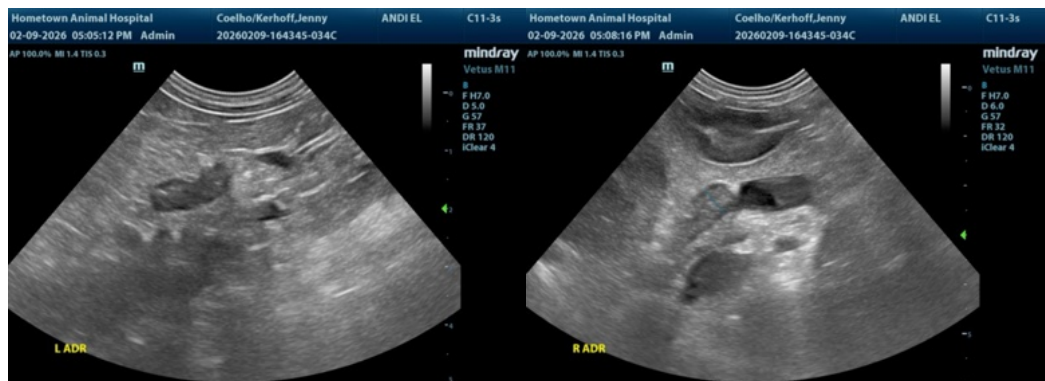No ascites evident.

ULTRASONOGRAPHIC FINDINGS

- Gallbladder sediment.

INTERPRETATION OF THE FINDINGS & FURTHER RECOMMENDATIONS

In essence a normal ultrasound examination of the abdomen as the gallbladder sediment can be considered an incidental finding.





PATIENT

Jenny Coelho Kerhoff

SPECIES

Canine

BREED

Small Mix

SEX

Spayed female

AGE

10 years

WEIGHT

17 lbs

INTERPRETED BY

Remo Lobetti, BVSc,
MMedVet (Med),
PhD, Dipl. ECVIM

IMAGING PERFORMED BY

Dr. Casper

HOSPITAL NAME

Hometown AH Florida

REFERRING VET

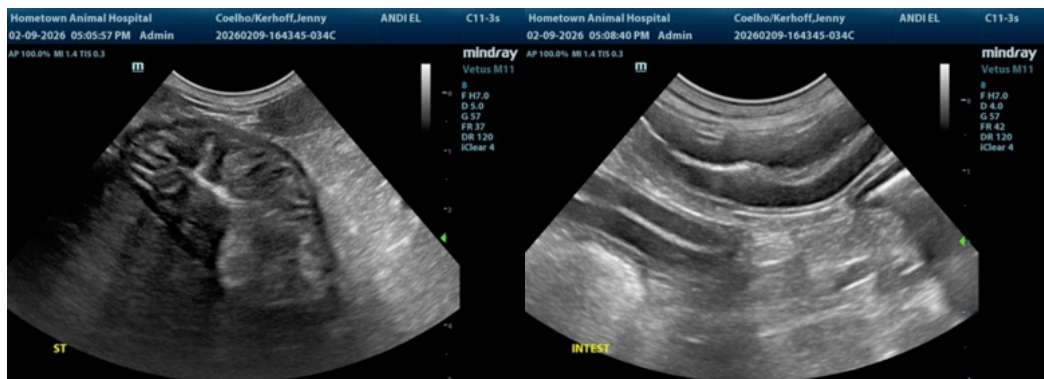
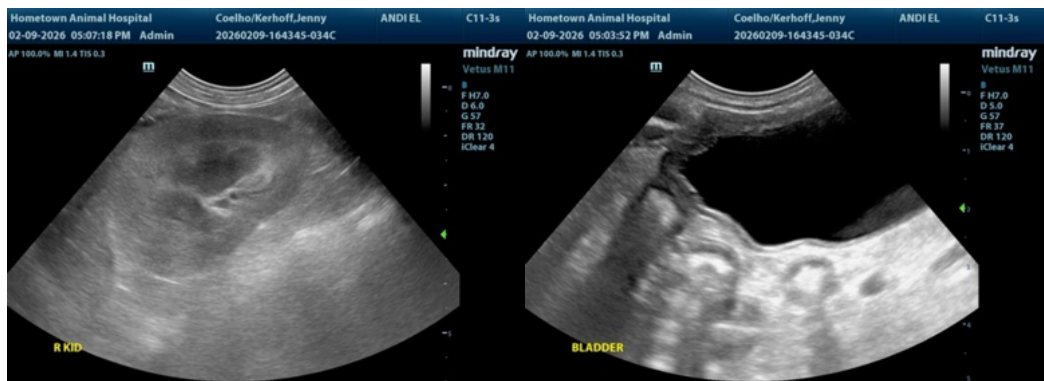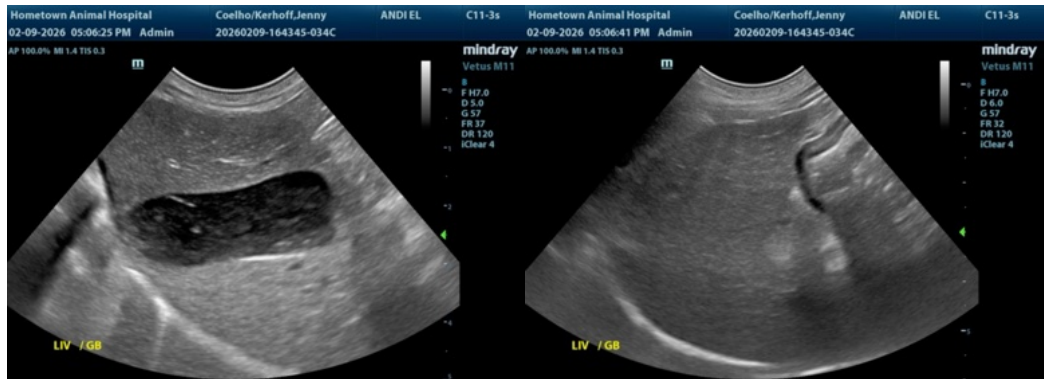
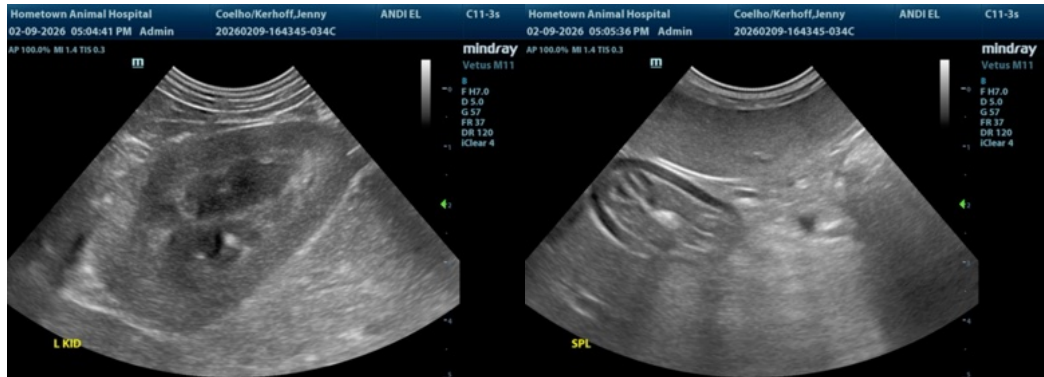
Dr. Casper

INVOICE

71430

DATE

2/10/26





PATIENT

Jenny Coelho Kerhoff

SPECIES

Canine

BREED

Small Mix

SEX

Spayed female

AGE

10 years

WEIGHT

17 lbs

INTERPRETED BY

Remo Lobetti, BVSc,
MMedVet (Med),
PhD, Dipl. ECVIM

IMAGING PERFORMED BY

Dr. Casper

HOSPITAL NAME

Hometown AH Florida

REFERRING VET

Dr. Casper

INVOICE

71430

DATE

2/10/26

The information and recommendations provided are based on the images presented by the referring veterinarian/sonographer. No evaluation can be communicated regarding pathology that was not visible in the image/video clips provided.

Thank you for this referral. If the clinical or image interpretation does not parallel your findings or if I can be of any further assistance please contact me.

Remo Lobetti, BVSc, MMedVet (Med), PhD, Dipl. ECVIM (Internal Medicine)

info@sonopath.com