



PATIENT

Griffey Politika

SPECIES

Canine

BREED

Northwest Farm
Terrier

SEX

Neutered male

AGE

9 years

WEIGHT

68.3 lbs

INTERPRETED BY

Remo Lobetti, BVSc,
MMedVet (Med),
PhD, Dipl. ECVIM

IMAGING PERFORMED BY

Dr. Wagner

HOSPITAL NAME

Angeles Clinic for
Animals

REFERRING VET

Dr. Wagner

INVOICE

71457

DATE

2/10/26

PRESENTING CLINICAL SIGNS

- pet is clinically well but has had UP:C around 2 for about 1 year. Not currently treated. Has atopy, doing well currently with apoquel. Littermate recently passed away of kidney disease (not my patient so unclear history) as well as hx of PLN in other pets in this line of dogs.
- Eats z/d diet for possible food allergy
- CBC --Mild eosinopenia 79 --mild thrombocytosis 470k Chem --BUN 15, Creat 0.8 --ALP 496 --Chol 515 UA - USG 1.009, 2+ protein, benign sediment UP:C 2.1 T4 1.6 4Dx neg for all

ULTRASONOGRAPHIC EXAMINATION OF THE ABDOMEN

Urinary System

The urinary bladder is full with a normal thickness and smooth appearance of the wall. A scant amount of floating, hyperechogenic sediment.

Normal appearance of the trigone area, proximal urethra, and iliac blood vessels.

Normal appearance and size of the iliac lymph nodes. Ureters not visualized, which can be considered a normal finding.

Normal renal size (left measured 6.0 cm, right measured 6.5 cm), architecture, echogenic appearance, cortico-medullary differentiation, which maintains a 1:3 cortex to medulla ratio, pelvis, and capsule. No infarcts, mineralization or renoliths evident.

The prostate is small and hypoechogenic.

Adrenal Glands

The left adrenal gland is normal in shape, echogenic appearance, size, position, and appearance of the visible peri-adrenal vasculature. Left adrenal gland measured 0.57 cm in width. The right adrenal gland was not clearly visualized, but appears to be of normal shape, echogenic appearance and size.

Spleen

Normal size and echogenic appearance. Smooth homogenous parenchyma and regular curvilinear capsule. Normal volume of the splenic vasculature without any overt congestion or thrombosis evident. No inflammatory, neoplastic, infarction, or infiltrative changes evident. The spleen measured 2.8 cm in width.

Liver

Normal size, echogenic appearance, portal markings, and regular curvilinear capsule. No nodules or masses evident. Normal appearance of the hepatic and portal vasculature.



PATIENT

Griffey Politika

SPECIES

Canine

BREED

Northwest Farm
Terrier

SEX

Neutered male

AGE

9 years

WEIGHT

68.3 lbs

INTERPRETED BY

Remo Lobetti, BVSc,
MMedVet (Med),
PhD, Dipl. ECVIM

IMAGING PERFORMED BY

Dr. Wagner

HOSPITAL NAME

Angeles Clinic for
Animals

REFERRING VET

Dr. Wagner

INVOICE

71457

DATE

2/10/26

Gallbladder

The gallbladder is small containing normal anechoic bile. Normal thickness and echogenic appearance of the wall. Normal size and appearance of the cystic and common bile duct.

Gastrointestinal

Normal appearance of the stomach, duodenum, small intestine, ileo-cecal junction, and colon with no loss of layering, 1:3 muscularis to mucosa ratio, normal wall thickness and peristaltic activity, and no distension of the lumen.

Pancreas

The visible sections of the pancreas are of normal size and echogenic appearance with a regular capsule. Normal echogenic appearance of the mesentery and fat surrounding the pancreas.

Free Abdomen

Normal mesenteric lymph nodes.

No ascites evident.

ULTRASONOGRAPHIC FINDINGS

- Normal ultrasound examination of the abdomen

INTERPRETATION OF THE FINDINGS & FURTHER RECOMMENDATIONS

Further assessment of the proteinuria would be blood pressure and ideally a renal biopsy especially as this appears to be a familial nephropathy.

Management of the proteinuria would either be an ace inhibitor or receptor blocker and omega 3 fatty acid supplementation.



PATIENT

Griffey Politika

SPECIES

Canine

BREED

Northwest Farm Terrier

SEX

Neutered male

AGE

9 years

WEIGHT

68.3 lbs

INTERPRETED BY

Remo Lobetti, BVSc, MMedVet (Med), PhD, Dipl. ECVIM

IMAGING PERFORMED BY

Dr. Wagner

HOSPITAL NAME

Angeles Clinic for Animals

REFERRING VET

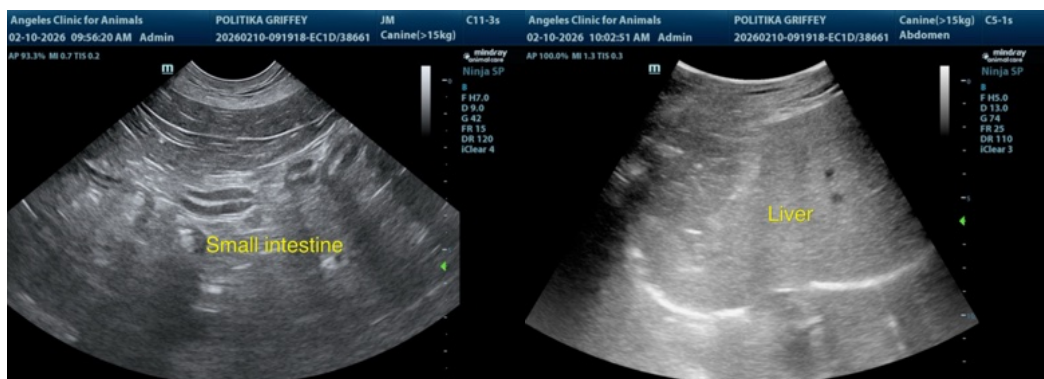
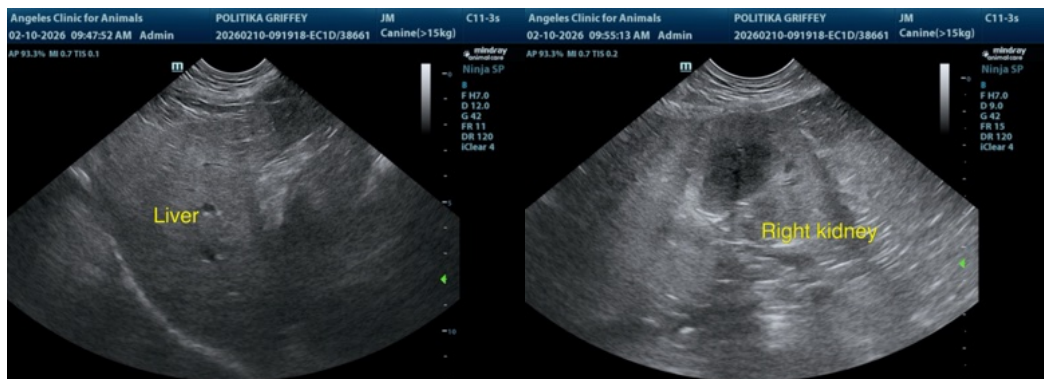
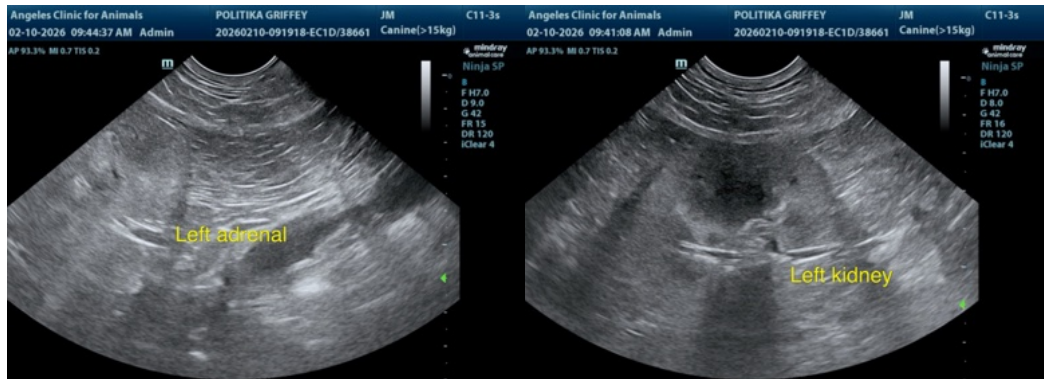
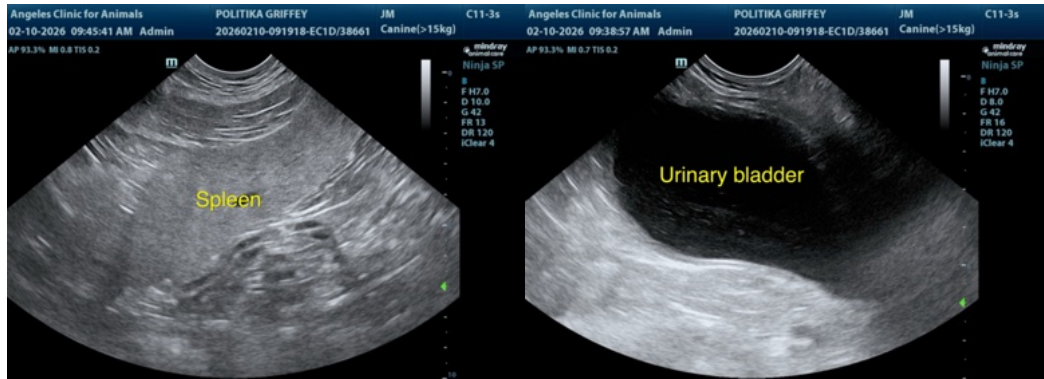
Dr. Wagner

INVOICE

71457

DATE

2/10/26





PATIENT

Griffey Politika

SPECIES

Canine

BREED

Northwest Farm
Terrier

SEX

Neutered male

AGE

9 years

WEIGHT

68.3 lbs

INTERPRETED BY

Remo Lobetti, BVSc,
MMedVet (Med),
PhD, Dipl. ECVIM

IMAGING PERFORMED BY

Dr. Wagner

HOSPITAL NAME

Angeles Clinic for
Animals

REFERRING VET

Dr. Wagner

INVOICE

71457

DATE

2/10/26

The information and recommendations provided are based on the images presented by the referring veterinarian/sonographer. No evaluation can be communicated regarding pathology that was not visible in the image/video clips provided.

Thank you for this referral. If the clinical or image interpretation does not parallel your findings or if I can be of any further assistance please contact me.

Remo Lobetti, BVSc, MMedVet (Med), PhD, Dipl. ECVIM (Internal Medicine)

info@sonopath.com