



PATIENT

Birdy Walker

SPECIES

Canine

BREED

Labrador Retriever Mix

SEX

Spayed female

AGE

10 years

WEIGHT

32.5 lbs

INTERPRETED BY

Remo Lobetti, BVSc,
MMedVet (Med),
PhD, Dipl. ECVIM

IMAGING PERFORMED BY

Dr. Gillian Striano
Kaplan

HOSPITAL NAME

Ramsey VH

REFERRING VET

Dr. Gillian Striano
Kaplan

INVOICE

71428

DATE

2/10/26

PRESENTING CLINICAL SIGNS

- Pet lost 2.5# since 10/2025, eating RER
- Mild leukopenia; persistent from previous labs WBC 3.9 (prev 4.1) Neutrophils 2.59 (prev 2.575) Lymphocytes 0.842 (prev 0.152) Monocytes 0.101 (prev 0.152) Maldigestion and CBC 2/path review pending **STAFF PET**

ULTRASONOGRAPHIC EXAMINATION OF THE ABDOMEN

Urinary System

The urinary bladder is small with a normal thickness and smooth appearance of the wall. Normal anechoic urine with no sediment or uroliths evident.

Normal appearance of the trigone area, proximal urethra, and iliac blood vessels.

Normal appearance and size of the iliac lymph nodes. Ureters not visualized, which can be considered a normal finding.

Normal renal size (left measured 4.7 cm, right measured 5.5 cm), architecture, echogenic appearance, cortico-medullary differentiation, which maintains a 1:3 cortex to medulla ratio, pelvis, and capsule. No infarcts, mineralization or renoliths evident.

Adrenal Glands

The left adrenal gland is normal in shape, echogenic appearance, size, position, and appearance of the visible peri-adrenal vasculature. Left adrenal gland measured 2.27 cm in length x 0.63 cm and 0.58 cm in width. The right adrenal gland was not clearly visualized, but appears to be of normal shape, echogenic appearance and size.

Spleen

Normal size and echogenic appearance. Smooth homogenous parenchyma and regular curvilinear capsule. Normal volume of the splenic vasculature without any overt congestion or thrombosis evident. No inflammatory, neoplastic, infarction, or infiltrative changes evident. The spleen measured 1.9 cm in width.

Liver

Normal size, echogenic appearance, portal markings, and regular curvilinear capsule. No nodules or masses evident. Normal appearance of the hepatic and portal vasculature.



PATIENT

Birdy Walker

SPECIES

Canine

BREED

Labrador Retriever Mix

SEX

Spayed female

AGE

10 years

WEIGHT

32.5 lbs

INTERPRETED BY

Remo Lobetti, BVSc,
MMedVet (Med),
PhD, Dipl. ECVIM

IMAGING PERFORMED BY

Dr. Gillian Striano
Kaplan

HOSPITAL NAME

Ramsey VH

REFERRING VET

Dr. Gillian Striano
Kaplan

INVOICE

71428

DATE

2/10/26

Gallbladder

The gallbladder is small containing normal anechoic bile. Normal thickness and echogenic appearance of the wall. Normal size and appearance of the cystic and common bile duct.

Gastrointestinal

Normal appearance of the stomach, duodenum, small intestine, ileo-cecal junction, and colon with no loss of layering, 1:3 muscularis to mucosa ratio, normal wall thickness and peristaltic activity, and no distension of the lumen.

Pancreas

The visible sections of the pancreas are of normal size and echogenic appearance with a regular capsule. Normal echogenic appearance of the mesentery and fat surrounding the pancreas.

Free Abdomen

Normal mesenteric lymph nodes.

No ascites evident.

ULTRASONOGRAPHIC FINDINGS

- Normal ultrasound examination of the abdomen.

INTERPRETATION OF THE FINDINGS & FURTHER RECOMMENDATIONS

On this ultrasound there is no obvious etiology for the persistent weight loss or the leukopenia.

Although the GI tract appears ultrasonographically normal, with the weight loss an underlying enteropathy such as parasitic enteritis, dietary hypersensitivity and inflammatory bowel disease should still be considered.

Intrathoracic pathology would be a less likely differential diagnosis.

Further assessment would be based on the pending results, but could include survey thoracic radiographs, fecal analysis and endoscopy of the upper GI tract with biopsies.

Specific therapy would be dependent on an etiological diagnosis.



PATIENT

Birdy Walker

SPECIES

Canine

BREED

Labrador Retriever Mix

SEX

Spayed female

AGE

10 years

WEIGHT

32.5 lbs

INTERPRETED BY

Remo Lobetti, BVSc,
MMedVet (Med),
PhD, Dipl. ECVIM

IMAGING PERFORMED BY

Dr. Gillian Striano
Kaplan

HOSPITAL NAME

Ramsey VH

REFERRING VET

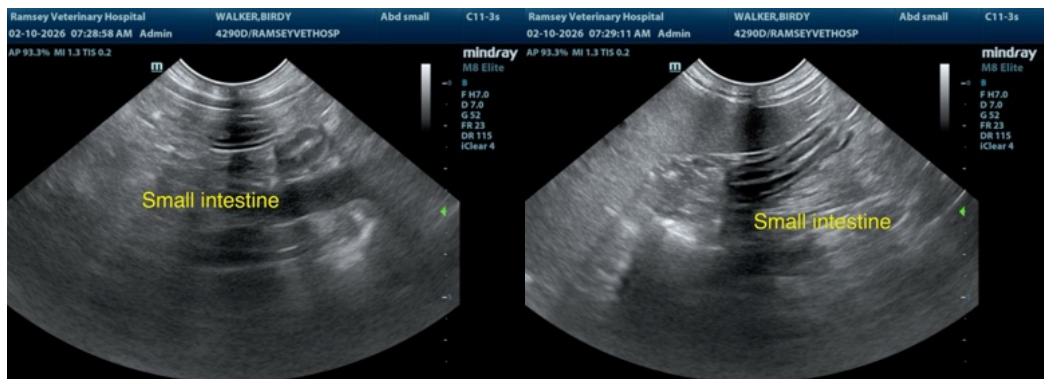
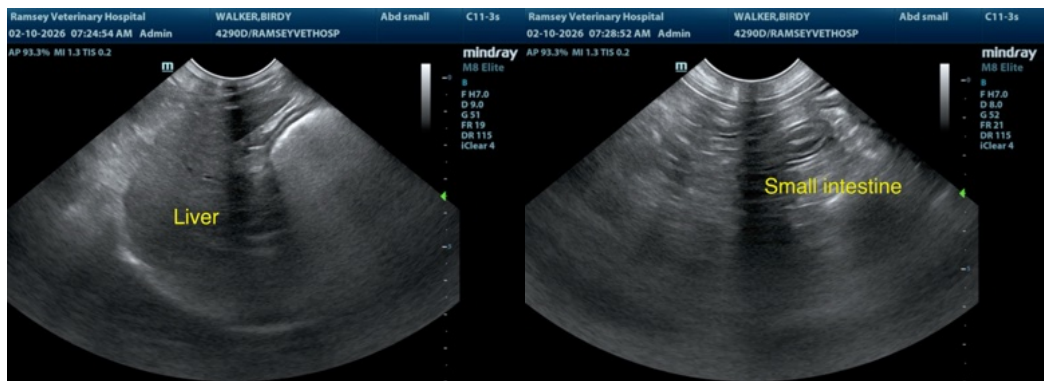
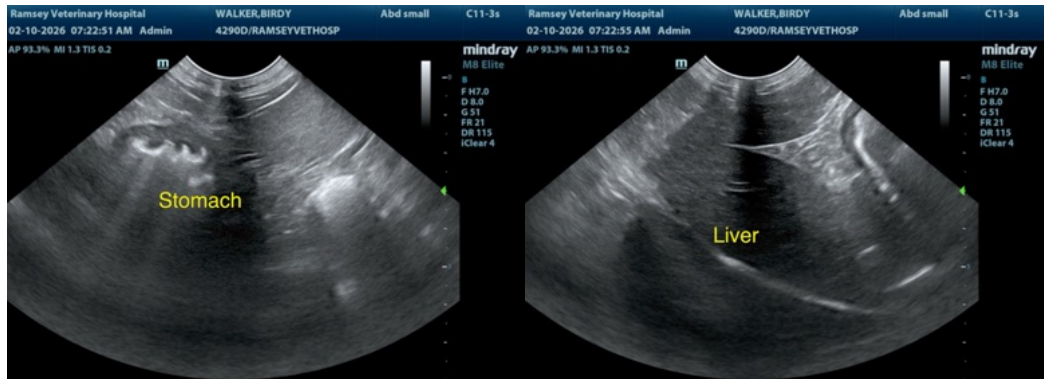
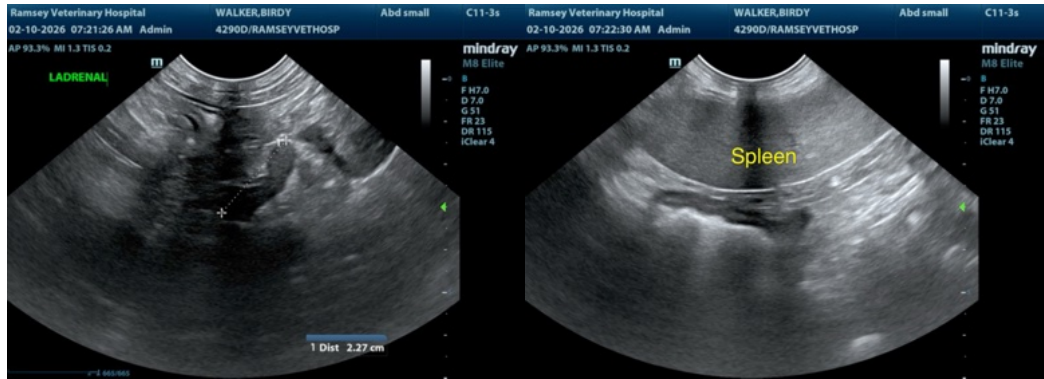
Dr. Gillian Striano
Kaplan

INVOICE

71428

DATE

2/10/26





PATIENT

Birdy Walker

SPECIES

Canine

BREED

Labrador Retriever Mix

SEX

Spayed female

AGE

10 years

WEIGHT

32.5 lbs

INTERPRETED BY

Remo Lobetti, BVSc,
MMedVet (Med),
PhD, Dipl. ECVIM

IMAGING PERFORMED BY

Dr. Gillian Striano
Kaplan

HOSPITAL NAME

Ramsey VH

REFERRING VET

Dr. Gillian Striano
Kaplan

INVOICE

71428

DATE

2/10/26

The information and recommendations provided are based on the images presented by the referring veterinarian/sonographer. No evaluation can be communicated regarding pathology that was not visible in the image/video clips provided.

Thank you for this referral. If the clinical or image interpretation does not parallel your findings or if I can be of any further assistance please contact me.

Remo Lobetti, BVSc, MMedVet (Med), PhD, Dipl. ECVIM (Internal Medicine)

info@sonopath.com