



PATIENT

Millie Lyon

SPECIES

Canine

BREED

Cavalier Poodle Mix

SEX

Spayed female

AGE

8 years

WEIGHT

19.4 lbs

INTERPRETED BY

Remo Lobetti, BVSc,
MMedVet (Med),
PhD, Dipl. ECVIM

IMAGING PERFORMED BY

Dr. Wagner

HOSPITAL NAME

Angeles Clinic for
Animals

REFERRING VET

Dr. Wagner

INVOICE

69473

DATE

12/9/25

PRESENTING CLINICAL SIGNS

History: Hx intermittent vomiting, low-normal albumin which responded to novel protein low fat diet. Recent ALT elevation Mildly increased thirst, urination per owner
Abnormal PE/Chem/CBC/UA Results: CBC - NSF Chem - ALT 205 10/31, 287 Dec 2; ALP normal (64), albumin 2.6, AST 67 UA - USG 1.052, 2+ protein, benign sediment

ULTRASONOGRAPHIC EXAMINATION OF THE ABDOMEN

Urinary System

The urinary bladder is full with a normal thickness and smooth appearance of the wall. Normal anechoic urine with no sediment or uroliths evident.

Normal appearance of the trigone area, proximal urethra, and iliac blood vessels.

Normal appearance and size of the iliac lymph nodes. Ureters not visualized, which can be considered a normal finding.

Normal renal size (left measured 4.3 cm, right measured 4.7 cm), architecture, echogenic appearance, cortico-medullary differentiation, which maintains a 1:3 cortex to medulla ratio, pelvis, and capsule. No infarcts, mineralization or renoliths evident. Normal color flow pattern is evident in both kidneys.

Adrenal Glands

Normal shape, echogenic appearance, size, position, and appearance of the visible peri-adrenal vasculature. Left adrenal gland measured 0.36 cm in width. The right adrenal gland measured 0.42 cm in width.

Spleen

Normal size and echogenic appearance. Smooth homogenous parenchyma and regular curvilinear capsule. Normal volume of the splenic vasculature without any overt congestion or thrombosis evident. No inflammatory, neoplastic, infarction, or infiltrative changes evident. The spleen measured 2.7 cm in width.

Liver

Normal size, echogenic appearance, portal markings, and regular curvilinear capsule. No nodules or masses evident. Normal appearance of the hepatic and portal vasculature.

Gallbladder

The gallbladder is full containing normal anechoic bile. Normal thickness and echogenic appearance of the wall. Normal size and appearance of the cystic and common bile duct.



PATIENT

Millie Lyon

SPECIES

Canine

BREED

Cavalier Poodle Mix

SEX

Spayed female

AGE

8 years

WEIGHT

19.4 lbs

INTERPRETED BY

Remo Lobetti, BVSc,
MMedVet (Med),
PhD, Dipl. ECVIM

IMAGING PERFORMED BY

Dr. Wagner

HOSPITAL NAME

Angeles Clinic for
Animals

REFERRING VET

Dr. Wagner

INVOICE

69473

DATE

12/9/25

Gastrointestinal

Normal appearance of the stomach, duodenum, small intestine, ileo-cecal junction, and colon with no loss of layering, 1:3 muscularis to mucosa ratio, normal wall thickness and peristaltic activity, and no distension of the lumen.

Pancreas

The visible sections of the pancreas are of normal size and echogenic appearance with a regular capsule. Normal echogenic appearance of the mesentery and fat surrounding the pancreas.

Free Abdomen

Normal mesenteric lymph nodes.

No ascites evident.

ULTRASONOGRAPHIC FINDINGS

- Normal ultrasound examination.

INTERPRETATION OF THE FINDINGS & FURTHER RECOMMENDATIONS

On this ultrasound there is no obvious etiology for the elevated ALT activity.

Although the liver appears ultrasonographically normal with the elevated ALT activity an underlying hepatopathy such as reactive hyperplasia, vacuolar and metabolic should still be considered.

Hepatitis and infiltrative neoplasia would be highly unlikely differential diagnosis.

Further assessment would be FNA cytology of the liver. However, a tru cut or wedge biopsy of the liver may be required for a final etiological diagnosis. UPC would also be recommended.

Specific therapy would be dependent on an etiological diagnosis. Symptomatic management that can be considered for the hepatopathy would be the use of Ursodiol with regular monitoring of liver enzyme activity.



PATIENT

Millie Lyon

SPECIES

Canine

BREED

Cavalier Poodle Mix

SEX

Spayed female

AGE

8 years

WEIGHT

19.4 lbs

INTERPRETED BY

Remo Lobetti, BVSc,
MMedVet (Med),
PhD, Dipl. ECVIM

IMAGING PERFORMED BY

Dr. Wagner

HOSPITAL NAME

Angeles Clinic for
Animals

REFERRING VET

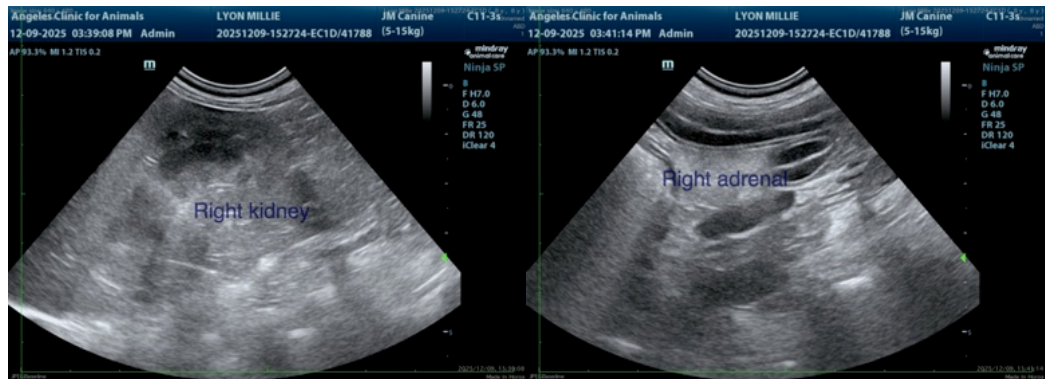
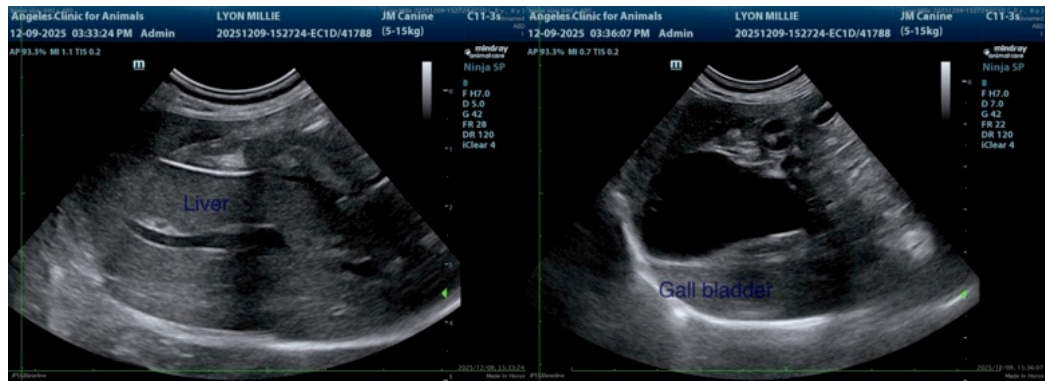
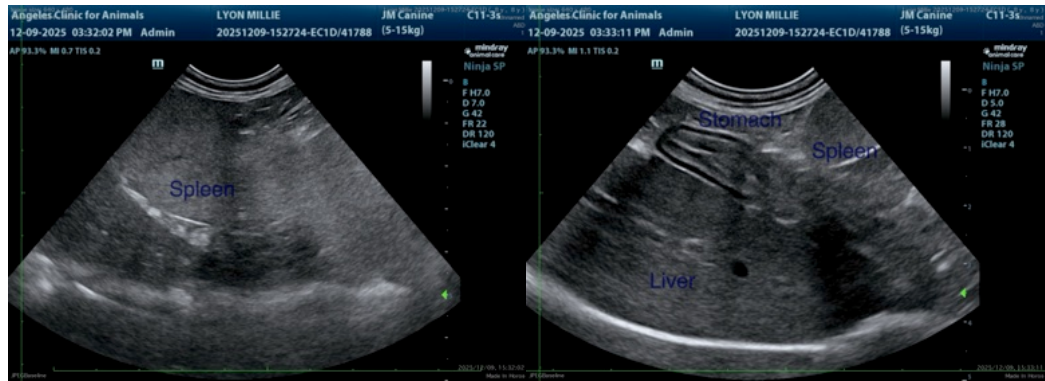
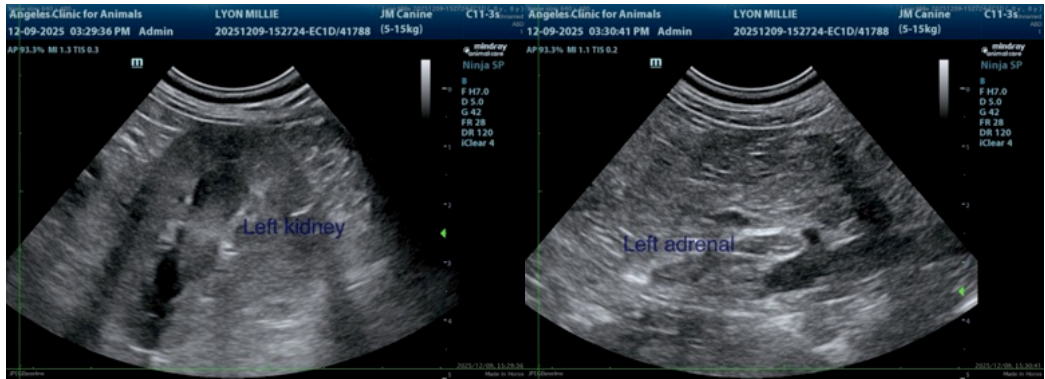
Dr. Wagner

INVOICE

69473

DATE

12/9/25





PATIENT

Millie Lyon

SPECIES

Canine

BREED

Cavalier Poodle Mix

SEX

Spayed female

AGE

8 years

WEIGHT

19.4 lbs

INTERPRETED BY

Remo Lobetti, BVSc,
MMedVet (Med),
PhD, Dipl. ECVIM

IMAGING PERFORMED BY

Dr. Wagner

HOSPITAL NAME

Angeles Clinic for
Animals

REFERRING VET

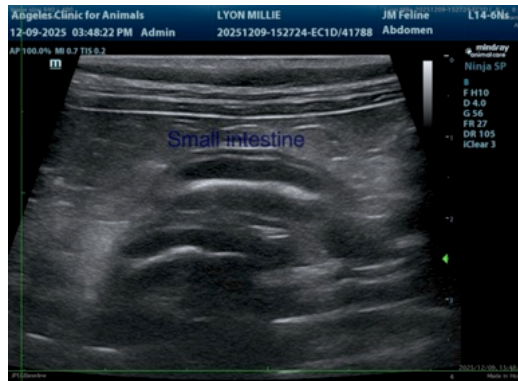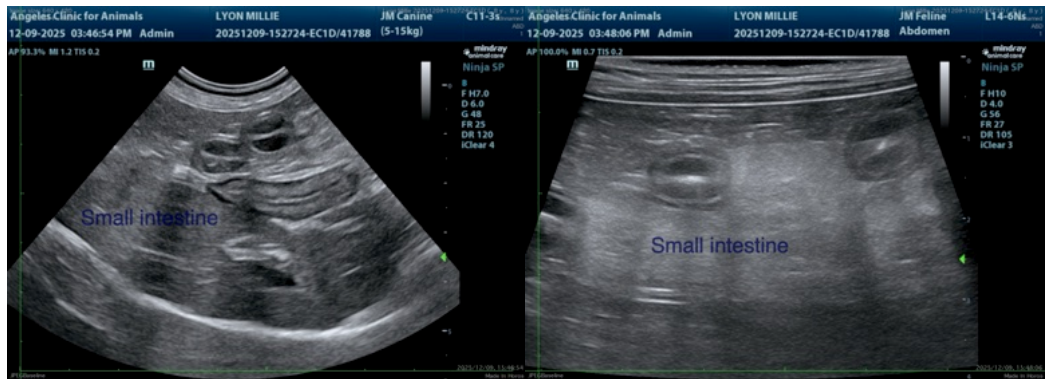
Dr. Wagner

INVOICE

69473

DATE

12/9/25



The information and recommendations provided are based on the images presented by the referring veterinarian/sonographer. No evaluation can be communicated regarding pathology that was not visible in the image/video clips provided.

Thank you for this referral. If the clinical or image interpretation does not parallel your findings or if I can be of any further assistance please contact me.

Remo Lobetti, BVSc, MMedVet (Med), PhD, Dipl. ECVIM (Internal Medicine)

info@sonopath.com