



PATIENT

Kotah Jones

SPECIES

Canine

BREED

German Shepherd

SEX

Spayed female

AGE

10 years

WEIGHT

63 lbs

INTERPRETED BY

Remo Lobetti, BVSc,
MMedVet (Med),
PhD, Dipl. ECVIM

IMAGING PERFORMED BY

Dr. Amy Isaac

HOSPITAL NAME

Valley West & Elk
Valley VH

REFERRING VET

Dr. Isaac

INVOICE

69394

DATE

12/8/25

PRESENTING CLINICAL SIGNS

History of 10 pound weight loss with normal appetite. Bloodwork normal. No vomiting/diarrhea. No coughing/sneezing. CBC/Chem/UA/T4 all NSF. Chest and abdominal radiographs do not show any obvious lesions.

ULTRASONOGRAPHIC EXAMINATION OF THE ABDOMEN

Urinary System

The urinary bladder is full with a normal thickness and smooth appearance of the wall. Normal anechoic urine with no sediment or uroliths evident.

Normal appearance of the trigone area, proximal urethra, and iliac blood vessels.

Normal appearance and size of the iliac lymph nodes. Ureters not visualized, which can be considered a normal finding.

Normal renal size (left measured 6.4 cm, right measured 6.0 cm), architecture, echogenic appearance, cortico-medullary differentiation, which maintains a 1:3 cortex to medulla ratio, pelvis, and capsule. No infarcts, mineralization or renoliths evident.

Adrenal Glands

The left adrenal gland is normal in shape, echogenic appearance, size, position, and appearance of the visible peri-adrenal vasculature. Left adrenal gland measured 0.45 cm and 0.5 cm in width. The right adrenal gland was not clearly visualized, but appears to be of normal shape, echogenic appearance and size.

Spleen

Normal size and echogenic appearance. Smooth homogenous parenchyma and regular curvilinear capsule. Normal volume of the splenic vasculature without any overt congestion or thrombosis evident. No inflammatory, neoplastic, infarction, or infiltrative changes evident. The spleen measured 2.4 cm in width.

Liver

Normal size, echogenic appearance, portal markings, and regular curvilinear capsule. No nodules or masses evident. Normal appearance of the hepatic and portal vasculature.

Gallbladder

The gallbladder is full containing normal anechoic bile. Normal thickness and echogenic appearance of the wall. Normal size and appearance of the cystic and common bile duct.



PATIENT

Kotah Jones

SPECIES

Canine

BREED

German Shepherd

SEX

Spayed female

AGE

10 years

WEIGHT

63 lbs

INTERPRETED BY

Remo Lobetti, BVSc,
MMedVet (Med),
PhD, Dipl. ECVIM

IMAGING PERFORMED BY

Dr. Amy Isaac

HOSPITAL NAME

Valley West & Elk
Valley VH

REFERRING VET

Dr. Isaac

INVOICE

69394

DATE

12/8/25

Gastrointestinal

Normal appearance of the stomach, duodenum, small intestine, ileo-cecal junction, and colon with no loss of layering, 1:3 muscularis to mucosa ratio, normal wall thickness and peristaltic activity, and no distension of the lumen.

Pancreas

The visible sections of the pancreas are of normal size and echogenic appearance with a regular capsule. Normal echogenic appearance of the mesentery and fat surrounding the pancreas.

Free Abdomen

Normal mesenteric lymph nodes.

No ascites evident.

ULTRASONOGRAPHIC FINDINGS

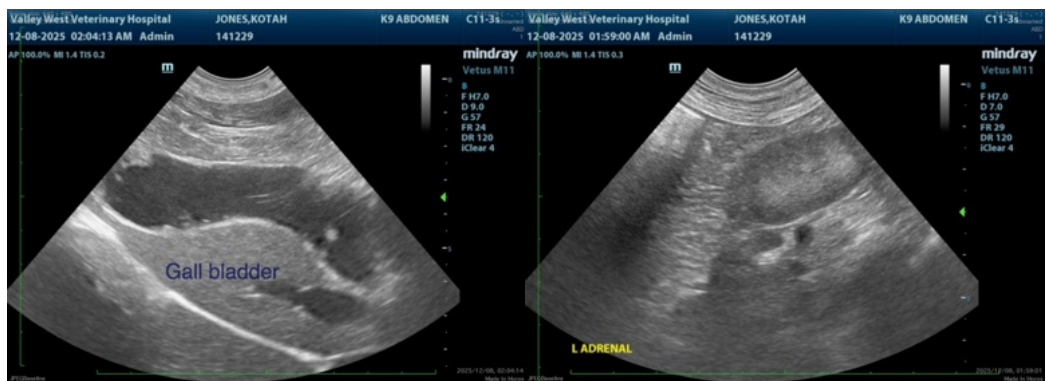- Normal ultrasound examination.

INTERPRETATION OF THE FINDINGS & FURTHER RECOMMENDATIONS

On this ultrasound there is no obvious etiology for the weight loss. Although the GI tract appears ultrasonographically normal and with normal blood work, an underlying enteropathy such as parasitic enteritis and inflammatory bowel disease should still be considered.

Further assessment would be fecal analysis, cobalamin and folate assay and endoscopy of the upper GI tract with biopsies.

Specific therapy would be dependent on an etiological diagnosis.





PATIENT

Kotah Jones

SPECIES

Canine

BREED

German Shepherd

SEX

Spayed female

AGE

10 years

WEIGHT

63 lbs

INTERPRETED BY

Remo Lobetti, BVSc,
MMedVet (Med),
PhD, Dipl. ECVIM

IMAGING PERFORMED BY

Dr. Amy Isaac

HOSPITAL NAME

Valley West & Elk
Valley VH

REFERRING VET

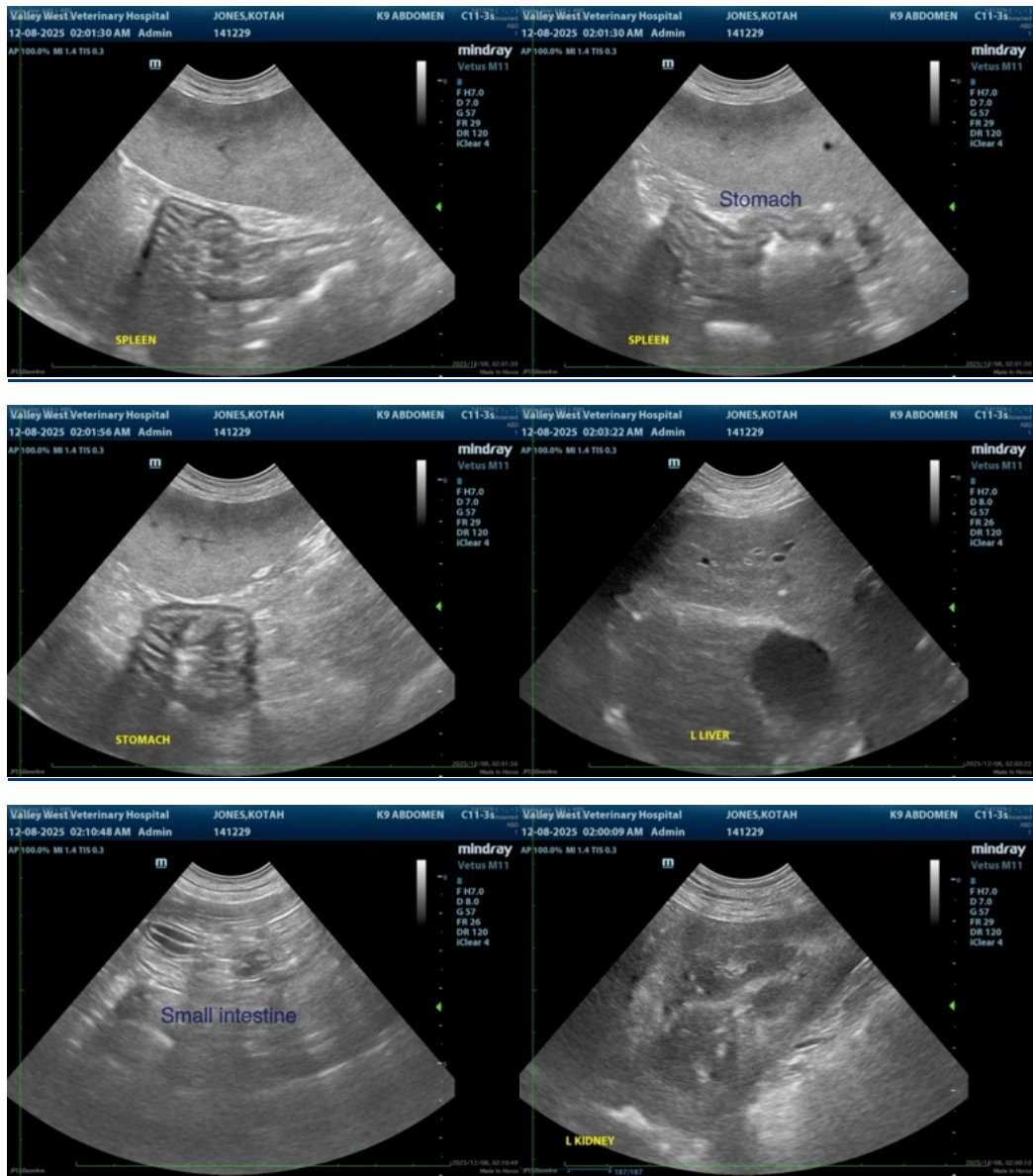
Dr. Isaac

INVOICE

69394

DATE

12/8/25



The information and recommendations provided are based on the images presented by the referring veterinarian/sonographer. No evaluation can be communicated regarding pathology that was not visible in the image/video clips provided.

Thank you for this referral. If the clinical or image interpretation does not parallel your findings or if I can be of any further assistance please contact me.

Remo Lobetti, BVSc, MMedVet (Med), PhD, Dipl. ECVIM (Internal Medicine)

info@sonopath.com