

PATIENT

Torrah Kulp

SPECIES

Canine

BREED

Leonberger

SEX

Spayed Female

AGE

2016

WEIGHT

90

INTERPRETED BY

Remo Lobetti, BVSc,
MMedVet (Med),
PhD, Dipl. ECVIM

**IMAGING
PERFORMED BY**

Rebekah Jakum, CVT,
ARDMS/RVT

HOSPITAL NAME

Telford Veterinary
Hospital

REFERRING VET

Dr. Loeffler

INVOICE

72365

DATE

12/5/25

PRESENTING CLINICAL SIGNS

Lethargy, mobility concerns, febrile, spinal discomfort Medication: Rejensa, methocarbamol, carprofen

ULTRASONOGRAPHIC EXAMINATION OF THE ABDOMEN

Urinary System

Small urinary bladder with a normal thickness and smooth appearance of the wall. Normal anechoic urine with no sediment or uroliths evident.

Normal appearance of the trigone area, proximal urethra, and iliac blood vessels.

Normal appearance and size of the iliac lymph nodes. Ureters not visualized, which can be considered a normal finding.

Normal renal size, architecture, echogenic appearance, cortico-medullary differentiation, which maintains a 1:3 cortex to medulla ratio, pelvis, and capsule. No infarcts, mineralization or renoliths evident. Left measures 7.0 cm. Right measures 7.2 cm.

Adrenal Glands

Normal shape, echogenic appearance, size, position, and appearance of the visible peri-adrenal vasculature. Left measures 3.1 cm in length x 0.58 cm and 0.46 cm in width. Right measures 3.18 cm in length x 0.50 cm and 0.40 cm in width.

Spleen

Normal size (2.1 cm in width) and echogenic appearance. Smooth homogenous parenchyma and regular curvilinear capsule. Normal volume of the splenic vasculature without any overt congestion or thrombosis evident. No inflammatory, neoplastic, infarction, or infiltrative changes evident.

Liver

Normal size, echogenic appearance, portal markings, and regular curvilinear capsule. No nodules or masses evident. Normal appearance of the hepatic and portal vasculature.

Gallbladder

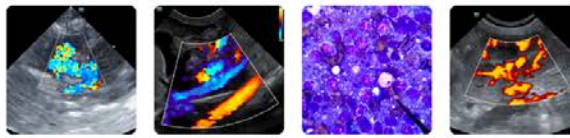
Small containing normal anechoic bile. Normal thickness and echogenic appearance of the wall. Normal size and appearance of the cystic and common bile duct.

Gastrointestinal

Normal appearance of the stomach, duodenum, small intestine, ileo-cecal junction, and colon with no loss of layering, 1:3 muscularis to mucosa ratio, normal wall thickness and peristaltic activity, and no distension of the lumen.

Pancreas

Visible sections present normal size and echogenic appearance. Regular capsule. Normal echogenic appearance of the mesentery and fat surrounding the pancreas.



PATIENT

Torrah Kulp

SPECIES

Canine

BREED

Leonberger

SEX

Spayed Female

AGE

2016

WEIGHT

90

INTERPRETED BY

Remo Lobetti, BVSc,
 MMedVet (Med),
 PhD, Dipl. ECVIM

IMAGING PERFORMED BY

Rebekah Jakum, CVT,
 ARDMS/RVT

HOSPITAL NAME

Telford Veterinary
 Hospital

REFERRING VET

Dr. Loeffler

Free Abdomen

Normal mesenteric lymph nodes.

No ascites evident.

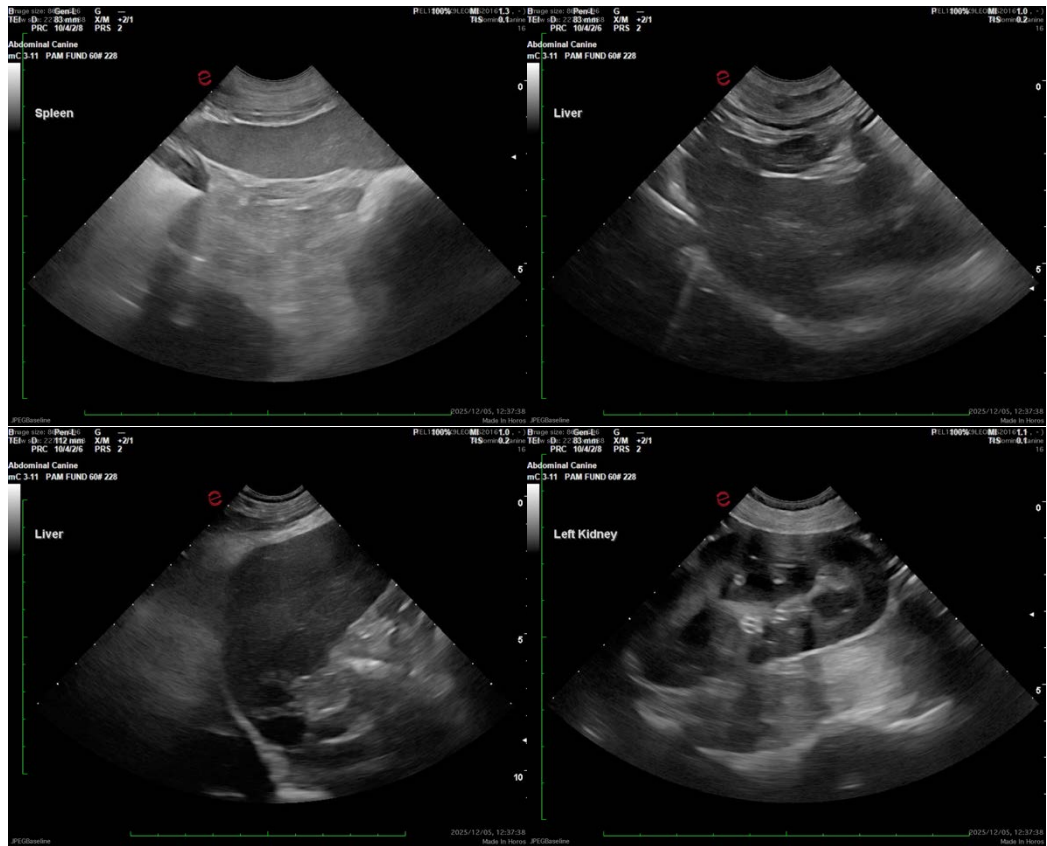
ULTRASONOGRAPHIC FINDINGS

- Normal ultrasound examination of the abdomen.

INTERPRETATION OF THE FINDINGS & FURTHER RECOMMENDATIONS

On this ultrasound there is no obvious etiology for the presenting clinical signs.

Specific therapy would be dependent on an etiological diagnosis.

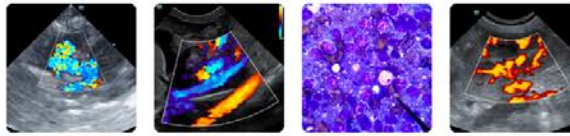


INVOICE

72365

DATE

12/5/25



PATIENT

Torrah Kulp

SPECIES

Canine

BREED

Leonberger

SEX

Spayed Female

AGE

2016

WEIGHT

90

INTERPRETED BY

Remo Lobetti, BVSc,
 MMedVet (Med),
 PhD, Dipl. ECVIM

IMAGING PERFORMED BY

Rebekah Jakum, CVT,
 ARDMS/RVT

HOSPITAL NAME

Telford Veterinary
 Hospital

REFERRING VET

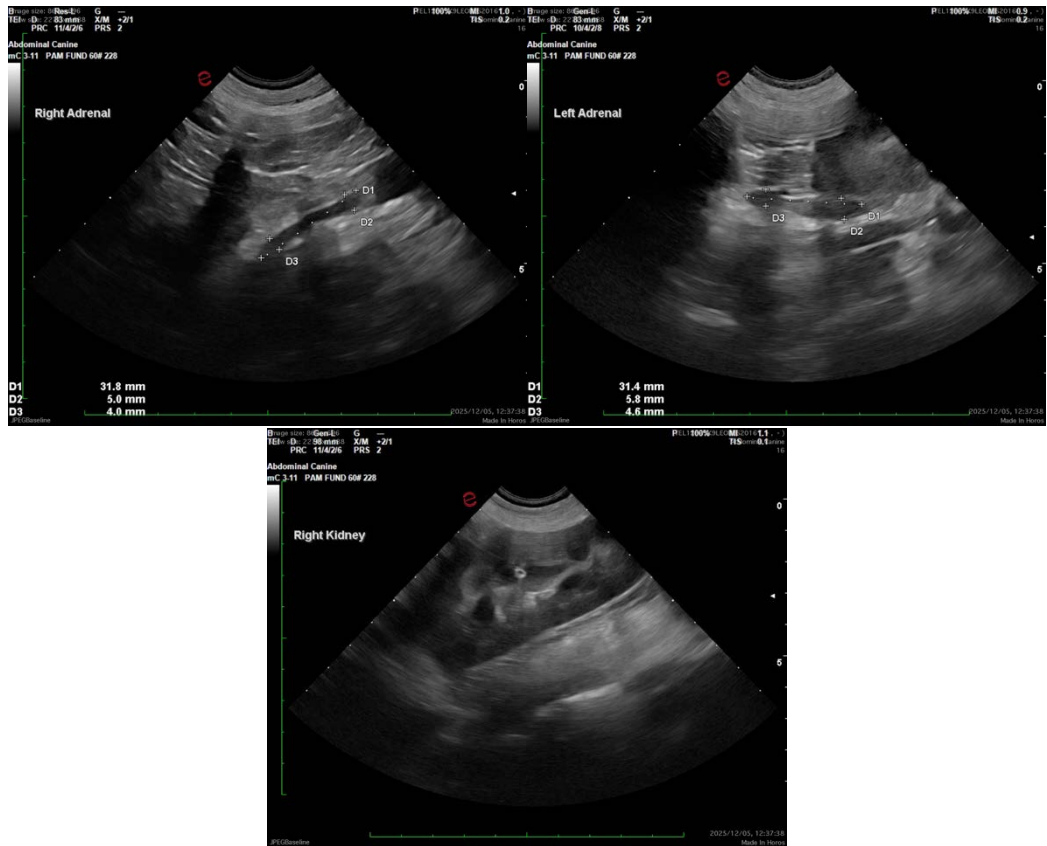
Dr. Loeffler

INVOICE

72365

DATE

12/5/25



The information and recommendations provided are based on the images presented by the referring veterinarian. No evaluation can be communicated regarding pathology that was not visible in the image/video clips provided.

Thank you for this referral. If the clinical or image interpretation does not parallel your findings or if I can be of any further assistance, please contact me.

Remo Lobetti, BVSc, MMedVet (Med), PhD, Dipl. ECVIM (Internal Medicine)

info@sonopath.com