



## PATIENT

Lucy Noel

## SPECIES

Canine

## BREED

Pug

## SEX

Spayed female

## AGE

10 years

## WEIGHT

7.4 kg

## INTERPRETED BY

Remo Lobetti, BVSc,  
MMedVet (Med),  
PhD, Dipl. ECVIM

## IMAGING PERFORMED BY

Dr. Louise Corbeil

## HOSPITAL NAME

Cochrane AC

## REFERRING VET

Dr. Corbeil

## INVOICE

69313

## DATE

12/4/25

## PRESENTING CLINICAL SIGNS

History: Lucy is a 10yo FS pug presented for abd ultrasound for mild elevations ALT and AST. Normal ALP and clinically normal otherwise. Hx anal gland abscess in November, also dental disease. BOAS/sterterous breathing. No heart murmur/no known cardiac disease.  
Abnormal PE/Chem/CBC/UA Results: Bloodwork 06-16-2025 ALT 234 U/L rr 10 125 Recheck bloodwork 10-01-2025 ALT 587 U/L rr 10- 125 AST 190 U/L rr 0-50

## ULTRASONOGRAPHIC EXAMINATION OF THE ABDOMEN

### *Urinary System*

The urinary bladder is full with a normal thickness and smooth appearance of the wall. A small amount of floating, hyperechogenic sediment.

Normal appearance of the trigone area, proximal urethra, and iliac blood vessels.

Normal appearance and size of the iliac lymph nodes. Ureters not visualized, which can be considered a normal finding.

Normal renal size (left measured 3.9 cm, right measured 4.0 cm), architecture, echogenic appearance, cortico-medullary differentiation, which maintains a 1:3 cortex to medulla ratio, pelvis, and capsule. No infarcts, mineralization or renoliths evident. Normal color flow pattern is evident in both kidneys.

### *Adrenal Glands*

Normal shape, echogenic appearance, size, position, and appearance of the visible peri-adrenal vasculature. Left adrenal gland measured 0.39 cm in width. The right adrenal gland measured 0.4 cm in width.

### *Spleen*

Normal size and echogenic appearance. Smooth homogenous parenchyma and regular curvilinear capsule. Normal volume of the splenic vasculature without any overt congestion or thrombosis evident. No inflammatory, neoplastic, infarction, or infiltrative changes evident. The spleen measured 1.2 cm in width.

### *Liver*

Normal size with an increased echogenic and coarse appearance of the right lobe with normal portal markings, and regular curvilinear capsule. The rest of the lobes have a normal echogenic appearance. No nodules or masses evident. Normal appearance of the hepatic and portal vasculature.



## PATIENT

Lucy Noel

## SPECIES

Canine

## BREED

Pug

## SEX

Spayed female

## AGE

10 years

## WEIGHT

7.4 kg

## INTERPRETED BY

Remo Lobetti, BVSc,  
MMedVet (Med),  
PhD, Dipl. ECVIM

## IMAGING PERFORMED BY

Dr. Louise Corbeil

## HOSPITAL NAME

Cochrane AC

## REFERRING VET

Dr. Corbeil

## INVOICE

69313

## DATE

12/4/25

## ***Gallbladder***

The gallbladder is small, almost empty containing normal anechoic bile. Normal thickness and echogenic appearance of the wall. Normal size and appearance of the cystic and common bile duct.

## ***Gastrointestinal***

Normal appearance of the stomach, duodenum, small intestine, ileo-cecal junction, and colon with no loss of layering, 1:3 muscularis to mucosa ratio, normal wall thickness and peristaltic activity, and no distension of the lumen. Gas and small amount of fluid is present in the stomach.

## ***Pancreas***

The visible sections of the pancreas are of normal size and echogenic appearance with a regular capsule. Normal echogenic appearance of the mesentery and fat surrounding the pancreas.

## ***Free Abdomen***

Normal mesenteric lymph nodes.

No ascites evident.

## **ULTRASONOGRAPHIC FINDINGS**

- Focal hepatopathy.
- Urinary bladder sediment.

## **INTERPRETATION OF THE FINDINGS & FURTHER RECOMMENDATIONS**

The most likely etiology for the focal hepatopathy would be reactive hyperplasia, vacuolar or metabolic with hepatitis and infiltrative neoplasia highly unlikely differential diagnosis.

The most likely etiology for the urinary bladder sediment would be incidental debris, with crystalluria and bacterial cystitis a less likely differential diagnosis.

Further assessment would be based on the pending cytology results, but could include urinalysis, possibly urine culture with a tru cut or wedge biopsy of the liver possibly required for a final etiological diagnosis.

Specific therapy would be dependent on an etiological diagnosis. Symptomatic management of the hepatopathy that could be considered would be the use of Ursodiol with regular monitoring of liver enzyme activity.



**PATIENT**

Lucy Noel

**SPECIES**

Canine

**BREED**

Pug

**SEX**

Spayed female

**AGE**

10 years

**WEIGHT**

7.4 kg

**INTERPRETED BY**

Remo Lobetti, BVSc,  
MMedVet (Med),  
PhD, Dipl. ECVIM

**IMAGING PERFORMED BY**

Dr. Louise Corbeil

**HOSPITAL NAME**

Cochrane AC

**REFERRING VET**

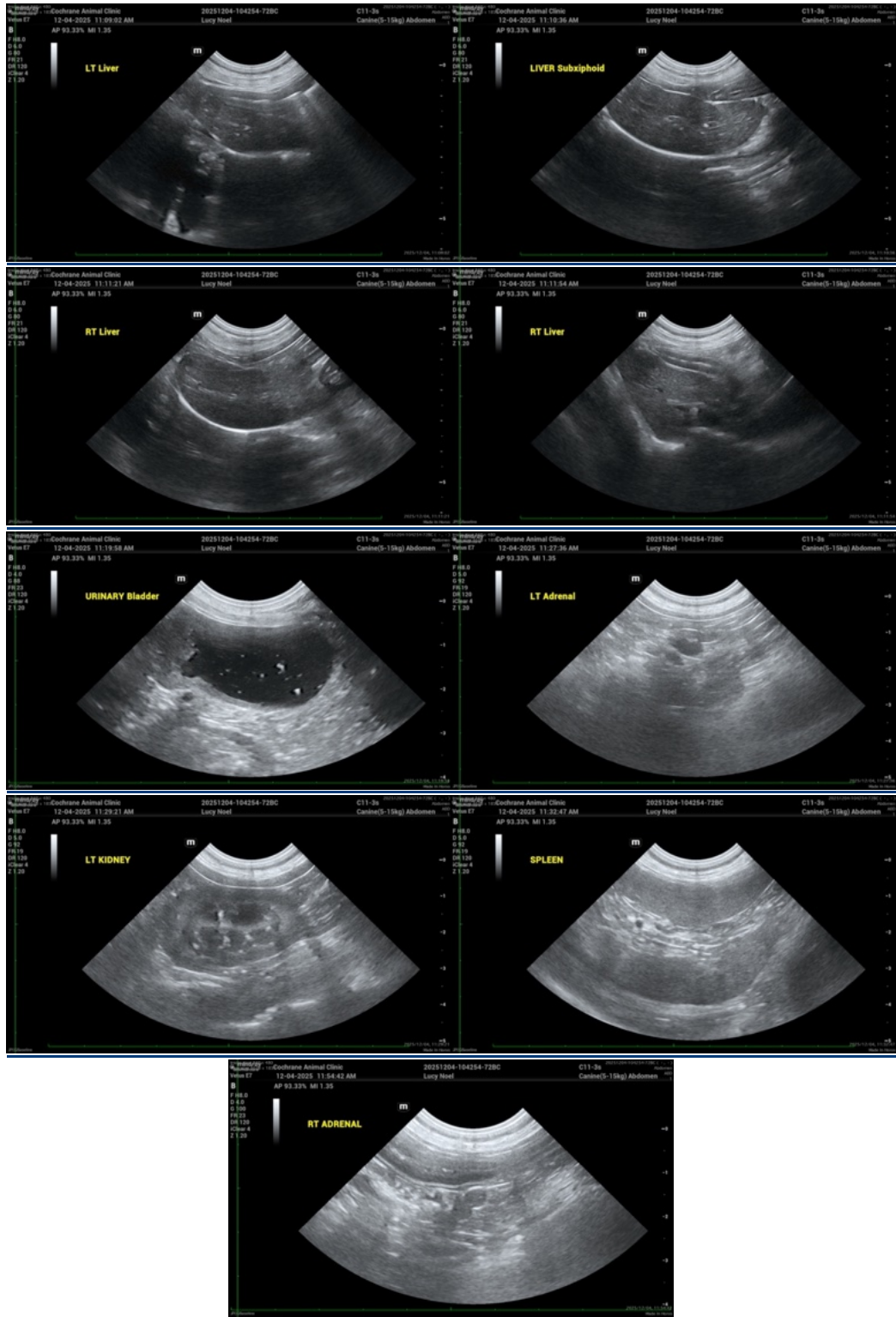
Dr. Corbeil

**INVOICE**

69313

**DATE**

12/4/25





## PATIENT

Lucy Noel

## SPECIES

Canine

## BREED

Pug

## SEX

Spayed female

## AGE

10 years

## WEIGHT

7.4 kg

## INTERPRETED BY

Remo Lobetti, BVSc,  
MMedVet (Med),  
PhD, Dipl. ECVIM

## IMAGING PERFORMED BY

Dr. Louise Corbeil

## HOSPITAL NAME

Cochrane AC

## REFERRING VET

Dr. Corbeil

## INVOICE

69313

## DATE

12/4/25

The information and recommendations provided are based on the images presented by the referring veterinarian/sonographer. No evaluation can be communicated regarding pathology that was not visible in the image/video clips provided.

Thank you for this referral. If the clinical or image interpretation does not parallel your findings or if I can be of any further assistance please contact me.

Remo Lobetti, BVSc, MMedVet (Med), PhD, Dipl. ECVIM (Internal Medicine)

[info@sonopath.com](mailto:info@sonopath.com)