



PATIENT

Ruby Tahmin

SPECIES

Feline

BREED

Domestic Shorthair

SEX

Spayed female

AGE

11 years

WEIGHT

9.84 lbs

INTERPRETED BY

Remo Lobetti, BVSc,
MMedVet (Med),
PhD, Dipl. ECVIM

IMAGING PERFORMED BY

Dr. Marie Allen

HOSPITAL NAME

North County AH

REFERRING VET

Dr. Allen

INVOICE

69679

DATE

12/30/25

PRESENTING CLINICAL SIGNS

History: Previous history of diabetes (currently in remission). O concerned about polyphagia, decreased water consumption, polyuria, excessive gas and large fecal matter. P also vomited but O reports it after eating. This have been present for the last 6 months. Clinical exam does not have any significant findings other than a slightly distended abdomen.

Abnormal PE/Chem/CBC/UA Results: Most recent bloodwork August 13, 2025 CBC/Chem: Glucosuria (254 mg/dL), Spec fPL elevation (34.2 µg/L), Monocytosis (1.451 K/µL), Thrombocytosis (728 K/µL) Urinalysis: Specific gravity (1.027), 1+ Urine protein (Borderline proteinuric by UPC), Blood/Hem (3+), WBC (2-5), RBC (30-50), Epithelial cells (1+ (1-2)/HPF) Rest of lab work WNL

ULTRASONOGRAPHIC EXAMINATION OF THE ABDOMEN

Urinary System

The urinary bladder is full with a normal thickness and smooth appearance of the wall. Normal anechoic urine with no sediment or uroliths evident.

Normal appearance of the trigone area, proximal urethra, and iliac blood vessels.

Normal appearance and size of the iliac lymph nodes. Ureters not visualized, which can be considered a normal finding.

Both kidneys were poorly visualized but appear to be of normal size, shape and echogenic appearance.

Adrenal Glands

The left adrenal gland was not visualized. The right adrenal gland is normal in shape, echogenic appearance, size, position, and appearance of the visible peri-adrenal vasculature. Right adrenal gland measured 0.37 cm in width.

Spleen

Normal size and echogenic appearance. Smooth homogenous parenchyma and regular curvilinear capsule. Normal volume of the splenic vasculature without any overt congestion or thrombosis evident. No inflammatory, neoplastic, infarction, or infiltrative changes evident. The spleen measured 1.0 cm in width.

Liver

Normal size, echogenic appearance, portal markings, and regular curvilinear capsule. No nodules or masses evident. Normal appearance of the hepatic and portal vasculature.



PATIENT

Ruby Tahmin

SPECIES

Feline

BREED

Domestic Shorthair

SEX

Spayed female

AGE

11 years

WEIGHT

9.84 lbs

INTERPRETED BY

Remo Lobetti, BVSc,
MMedVet (Med),
PhD, Dipl. ECVIM

IMAGING PERFORMED BY

Dr. Marie Allen

HOSPITAL NAME

North County AH

REFERRING VET

Dr. Allen

INVOICE

69679

DATE

12/30/25

Gallbladder

The gallbladder is full containing normal anechoic bile. Normal thickness and echogenic appearance of the wall. Normal size and appearance of the cystic and common bile duct.

Gastrointestinal

Normal appearance of the stomach, duodenum, small intestine, ileo-cecal junction, and colon with no loss of layering, 1:3 muscularis to mucosa ratio, normal wall thickness and peristaltic activity, and no distension of the lumen.

Pancreas

The visible sections of the pancreas are of normal size and echogenic appearance with a regular capsule. Normal echogenic appearance of the mesentery and fat surrounding the pancreas.

Free Abdomen

Normal mesenteric lymph nodes.

No ascites evident.

ULTRASONOGRAPHIC FINDINGS

- Normal ultrasound examination of the abdomen.

INTERPRETATION OF THE FINDINGS & FURTHER RECOMMENDATIONS

On this ultrasound there is no obvious etiology for the presenting clinical signs.

With the previous history of pancreatitis and presenting clinical signs, exocrine pancreatic insufficiency would be an important differential diagnosis.

Further assessment would be CBC, serum biochemistry, urinalysis and TLI assay.

Specific therapy would be dependent on an etiological diagnosis.



PATIENT

Ruby Tahmin

SPECIES

Feline

BREED

Domestic Shorthair

SEX

Spayed female

AGE

11 years

WEIGHT

9.84 lbs

INTERPRETED BY

Remo Lobetti, BVSc,
MMedVet (Med),
PhD, Dipl. ECVIM

IMAGING PERFORMED BY

Dr. Marie Allen

HOSPITAL NAME

North County AH

REFERRING VET

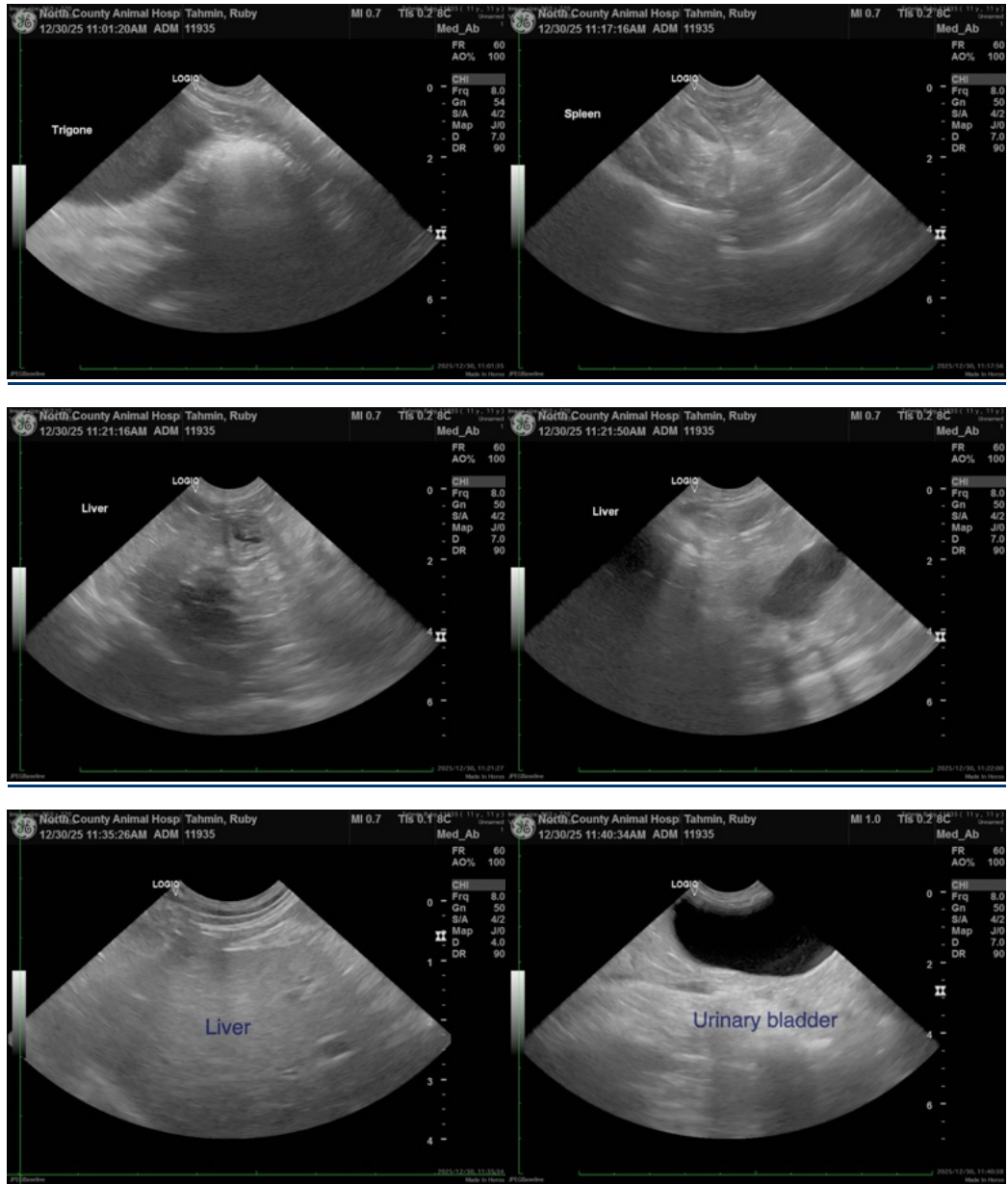
Dr. Allen

INVOICE

69679

DATE

12/30/25





PATIENT

Ruby Tahmin

SPECIES

Feline

BREED

Domestic Shorthair

SEX

Spayed female

AGE

11 years

WEIGHT

9.84 lbs

INTERPRETED BY

Remo Lobetti, BVSc,
MMedVet (Med),
PhD, Dipl. ECVIM

IMAGING PERFORMED BY

Dr. Marie Allen

HOSPITAL NAME

North County AH

REFERRING VET

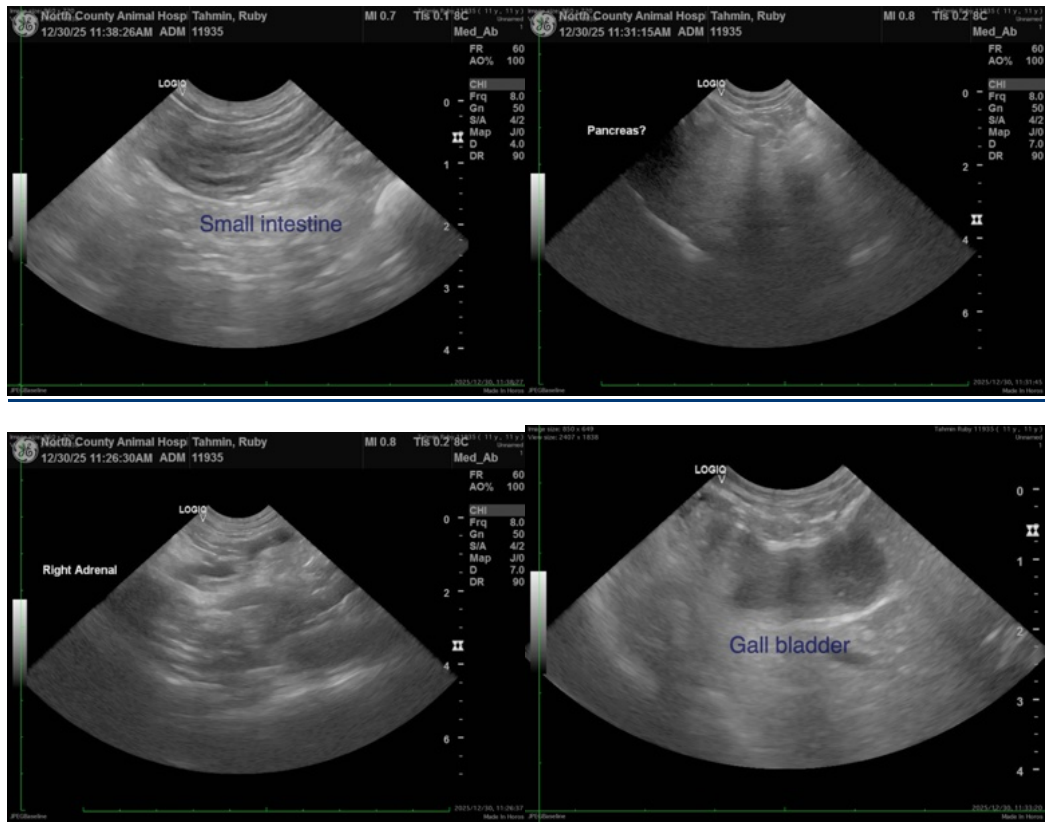
Dr. Allen

INVOICE

69679

DATE

12/30/25



The information and recommendations provided are based on the images presented by the referring veterinarian/sonographer. No evaluation can be communicated regarding pathology that was not visible in the image/video clips provided.

Thank you for this referral. If the clinical or image interpretation does not parallel your findings or if I can be of any further assistance please contact me.

Remo Lobetti, BVSc, MMedVet (Med), PhD, Dipl. ECVIM (Internal Medicine)

info@sonopath.com