



## PATIENT

Bear Corliss

## SPECIES

Feline

## BREED

Domestic Shorthair

## SEX

Neutered male

## AGE

12 years

## WEIGHT

6.1 lbs

## INTERPRETED BY

Remo Lobetti, BVSc,  
MMedVet (Med),  
PhD, Dipl. ECVIM

## IMAGING PERFORMED BY

Anshu Gupta

## HOSPITAL NAME

Liverpool Village AH

## REFERRING VET

Dr. Lathrop

## INVOICE

69676

## DATE

12/30/25

## PRESENTING CLINICAL SIGNS

History: Weight loss and PUPD. Intermittent soft stool and vomiting History of elevated proBNP  
Abnormal PE/Chem/CBC/UA Results: PE: grade 5/6 heart murmur, potbellied appearance to abdomen  
CBC/Chem: NSF

## ULTRASONOGRAPHIC EXAMINATION OF THE ABDOMEN

### *Urinary System*

The urinary bladder is full with a normal thickness and smooth appearance of the wall. Normal anechoic urine with no sediment or uroliths evident.

Normal appearance of the trigone area, proximal urethra, and iliac blood vessels.

Normal appearance and size of the iliac lymph nodes. Ureters not visualized, which can be considered a normal finding.

Normal renal size (left measured 3.6 cm, right measured 4.0 cm), architecture, echogenic appearance, cortico-medullary differentiation, which maintains a 1:3 cortex to medulla ratio, pelvis, and capsule. No infarcts, mineralization or renoliths evident. Normal color flow pattern is evident in both kidneys.

### *Adrenal Glands*

The adrenal glands are not clearly visualized, but appear to be of normal shape, echogenic appearance and size.

### *Spleen*

Normal size and echogenic appearance. Smooth homogenous parenchyma and regular curvilinear capsule. Normal volume of the splenic vasculature without any overt congestion or thrombosis evident. No inflammatory, neoplastic, infarction, or infiltrative changes evident. The spleen measured 0.4 cm in width.

### *Liver*

Normal size, echogenic appearance, portal markings, and regular curvilinear capsule. No nodules or masses evident. Normal appearance of the hepatic and portal vasculature.

### *Gallbladder*

The gallbladder is full containing normal anechoic bile. Normal thickness and echogenic appearance of the wall. Normal size and appearance of the cystic and common bile duct.



## PATIENT

Bear Corliss

## SPECIES

Feline

## BREED

Domestic Shorthair

## SEX

Neutered male

## AGE

12 years

## WEIGHT

6.1 lbs

## INTERPRETED BY

Remo Lobetti, BVSc,  
MMedVet (Med),  
PhD, Dipl. ECVIM

## IMAGING PERFORMED BY

Anshu Gupta

## HOSPITAL NAME

Liverpool Village AH

## REFERRING VET

Dr. Lathrop

## INVOICE

69676

## DATE

12/30/25

## *Gastrointestinal*

Normal appearance of the stomach, duodenum, small intestine, ileo-cecal junction, and colon with no loss of layering, 1:3 muscularis to mucosa ratio, normal wall thickness and peristaltic activity, and no distension of the lumen.

## *Pancreas*

The visible sections of the pancreas are of normal size and echogenic appearance with a regular capsule. Normal echogenic appearance of the mesentery and fat surrounding the pancreas.

## *Free Abdomen*

Prominent mesenteric lymph nodes measuring up to 0.4 x 1.0 cm in size, maintaining a normal shape and echogenic appearance.

No ascites evident.

## ULTRASONOGRAPHIC FINDINGS

- Mesenteric lymphadenomegaly.

## INTERPRETATION OF THE FINDINGS & FURTHER RECOMMENDATIONS

The most likely etiology for the mesenteric lymphadenomegaly would be reactive hyperplasia secondary to the intermittent GI signs with lymphadenitis and infiltrative neoplasia highly unlikely differential diagnosis.

Although the GI tract appears ultrasonographically normal, with the presenting clinical signs, an underlying enteropathy such as parasitic enteritis, dietary hypersensitivity and inflammatory bowel disease should still be considered.

Further assessment would be fecal analysis, cobalamin and folate assay, echocardiography and endoscopy of the upper GI tract with biopsies.

FNA cytology of the mesenteric lymph nodes can also be considered.

Specific therapy would be dependent on an etiological diagnosis.

Symptomatic management that can be considered would be feeding small frequent meals of a novel protein/hypoallergenic diet, cobalamin supplementation, course of Fenbendazole and if there is still not a satisfactory improvement then a course of Prednisolone would then be indicated.



## PATIENT

Bear Corliss

## SPECIES

Feline

## BREED

Domestic Shorthair

## SEX

Neutered male

## AGE

12 years

## WEIGHT

6.1 lbs

## INTERPRETED BY

Remo Lobetti, BVSc,  
MMedVet (Med),  
PhD, Dipl. ECVIM

## IMAGING PERFORMED BY

Anshu Gupta

## HOSPITAL NAME

Liverpool Village AH

## REFERRING VET

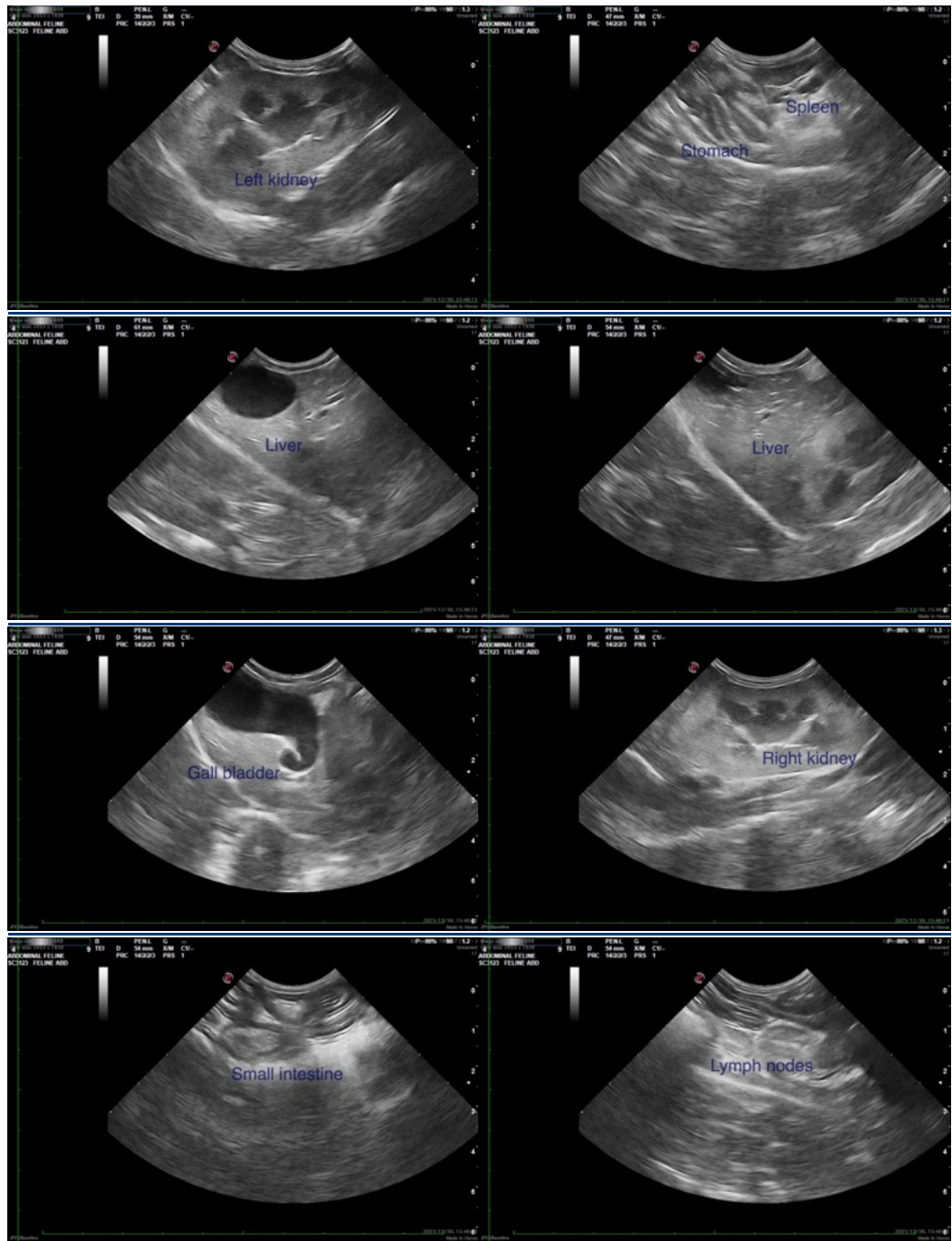
Dr. Lathrop

## INVOICE

69676

## DATE

12/30/25



The information and recommendations provided are based on the images presented by the referring veterinarian/sonographer. No evaluation can be communicated regarding pathology that was not visible in the image/video clips provided.

Thank you for this referral. If the clinical or image interpretation does not parallel your findings or if I can be of any further assistance please contact me.



## PATIENT

Remo Lobetti, BVSc, MMedVet (Med), PhD, Dipl. ECVIM (Internal Medicine)

Bear Corliss

[info@sonopath.com](mailto:info@sonopath.com)

## SPECIES

Feline

## BREED

Domestic Shorthair

## SEX

Neutered male

## AGE

12 years

## WEIGHT

6.1 lbs

## INTERPRETED BY

Remo Lobetti, BVSc,  
MMedVet (Med),  
PhD, Dipl. ECVIM

## IMAGING PERFORMED BY

Anshu Gupta

## HOSPITAL NAME

Liverpool Village AH

## REFERRING VET

Dr. Lathrop

## INVOICE

69676

## DATE

12/30/25