



PATIENT

Schooner Nicolls

SPECIES

Canine

BREED

Golden Retriever

SEX

Spayed female

AGE

12 years

WEIGHT

100 lbs

INTERPRETED BY

Remo Lobetti, BVSc,
MMedVet (Med),
PhD, Dipl. ECVIM

IMAGING PERFORMED BY

Grace Jayne, CVT

HOSPITAL NAME

Ark AH

REFERRING VET

Dr. Penraat

INVOICE

69272

DATE

12/3/25

PRESENTING CLINICAL SIGNS

History: Schooner had a soft tissue sarcoma removed elsewhere on 11/19. She was recovering well until an acute vomiting episode 48 hours ago. Since then her appetite is decreased, she is lethargic, she is PU/PD, panting, and having urinary accidents.
Abnormal PE/Chem/CBC/UA Results: Weak in the hind end, but ambulatory. Obese. MM pale pink and tacky. Leukocytosis, anemia, azotemic, thrombocytopenic. Platelets 86, BUN 68, CREAT 2.7, SDMA 33, cortisol 10.6 WBC 25 HCT 34.7%.

ULTRASONOGRAPHIC EXAMINATION OF THE ABDOMEN

Urinary System

The urinary bladder is small with a normal thickness and smooth appearance of the wall. Normal anechoic urine with no sediment or uroliths evident.

Normal appearance of the trigone area, proximal urethra, and iliac blood vessels.

Normal appearance and size of the iliac lymph nodes. Ureters not visualized, which can be considered a normal finding.

Normal renal size (left measured 6.6 cm, right measured 7.5 cm), architecture, echogenic appearance, cortico-medullary differentiation, which maintains a 1:3 cortex to medulla ratio, pelvis, and capsule. No infarcts, mineralization or renoliths evident. Normal color flow pattern is evident in both kidneys.

Adrenal Glands

The adrenal glands are not visualized.

Spleen

Normal size and echogenic appearance. Smooth homogenous parenchyma and regular curvilinear capsule. Normal volume of the splenic vasculature without any overt congestion or thrombosis evident. No inflammatory, neoplastic, infarction, or infiltrative changes evident. The spleen measured 2.8 cm in width.

Liver

Normal size, echogenic appearance, portal markings, and regular curvilinear capsule. No nodules or masses evident. Normal appearance of the hepatic and portal vasculature.

Gallbladder

The gallbladder is full containing normal anechoic bile. Normal thickness and echogenic appearance of the wall. Normal size and appearance of the cystic and common bile duct.



PATIENT

Schooner Nicolls

SPECIES

Canine

BREED

Golden Retriever

SEX

Spayed female

AGE

12 years

WEIGHT

100 lbs

INTERPRETED BY

Remo Lobetti, BVSc,
MMedVet (Med),
PhD, Dipl. ECVIM

IMAGING PERFORMED BY

Grace Jayne, CVT

HOSPITAL NAME

Ark AH

REFERRING VET

Dr. Penraat

INVOICE

69272

DATE

12/3/25

Gastrointestinal

Normal appearance of the stomach, duodenum, small intestine, ileo-cecal junction, and colon with no loss of layering, 1:3 muscularis to mucosa ratio, normal wall thickness and peristaltic activity, and no distension of the lumen.

Pancreas

The visible sections of the pancreas are of normal size and echogenic appearance with a regular capsule. Normal echogenic appearance of the mesentery and fat surrounding the pancreas.

Free Abdomen

Normal mesenteric lymph nodes.

A scant amount of ascites present. A large amount of intraabdominal fat accumulation evident.

ULTRASONOGRAPHIC FINDINGS

- Mild ascites.

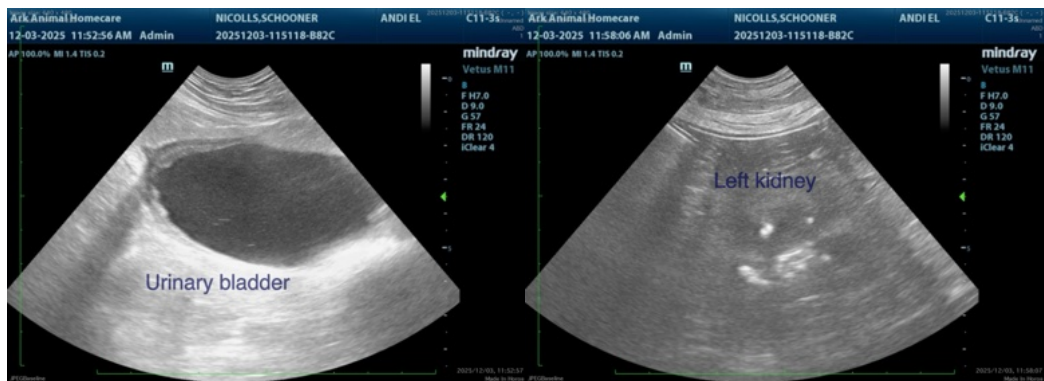
INTERPRETATION OF THE FINDINGS & FURTHER RECOMMENDATIONS

On this ultrasound there is no obvious etiology for the presenting clinical signs.

With the presenting clinical signs differential diagnosis to consider would be intrathoracic pathology, Leptospirosis, acute kidney injury and immune mediated hemolytic anemia/thrombocytopenia.

Further assessment would be urinalysis, possibly urine culture, three view thoracic radiographs, NSAID agglutination/Coombs test and PCR/serology for Leptospirosis.

Specific therapy would be dependent on an etiological diagnosis.





PATIENT

Schooner Nicolls

SPECIES

Canine

BREED

Golden Retriever

SEX

Spayed female

AGE

12 years

WEIGHT

100 lbs

INTERPRETED BY

Remo Lobetti, BVSc,
MMedVet (Med),
PhD, Dipl. ECVIM

IMAGING PERFORMED BY

Grace Jayne, CVT

HOSPITAL NAME

Ark AH

REFERRING VET

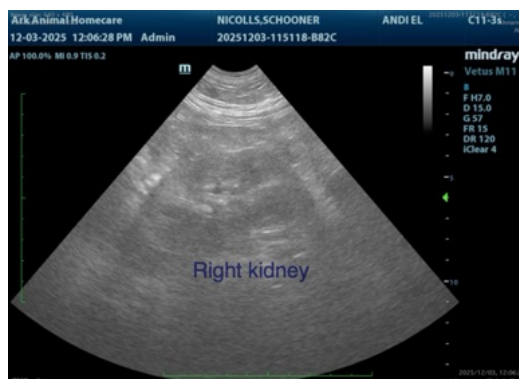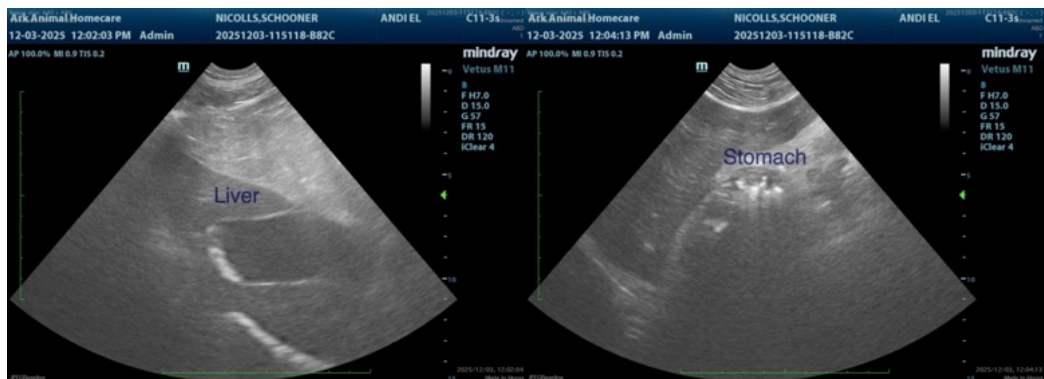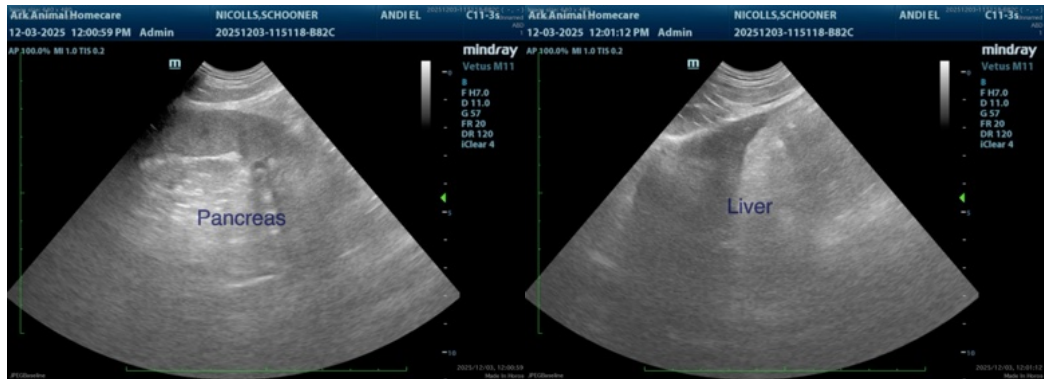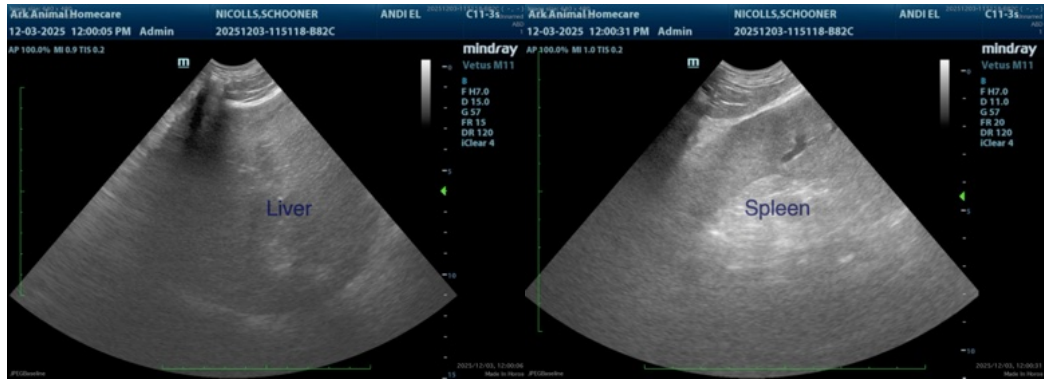
Dr. Penraat

INVOICE

69272

DATE

12/3/25





PATIENT

Schooner Nicolls

SPECIES

Canine

BREED

Golden Retriever

SEX

Spayed female

AGE

12 years

WEIGHT

100 lbs

INTERPRETED BY

Remo Lobetti, BVSc,
MMedVet (Med),
PhD, Dipl. ECVIM

IMAGING PERFORMED BY

Grace Jayne, CVT

HOSPITAL NAME

Ark AH

REFERRING VET

Dr. Penraat

INVOICE

69272

DATE

12/3/25

The information and recommendations provided are based on the images presented by the referring veterinarian/sonographer. No evaluation can be communicated regarding pathology that was not visible in the image/video clips provided.

Thank you for this referral. If the clinical or image interpretation does not parallel your findings or if I can be of any further assistance please contact me.

Remo Lobetti, BVSc, MMedVet (Med), PhD, Dipl. ECVIM (Internal Medicine)

info@sonopath.com