



PATIENT

Sadie Hoffman

SPECIES

Canine

BREED

Border Collie

SEX

Spayed female

AGE

12 years

WEIGHT

25.9 kg

INTERPRETED BY

Remo Lobetti, BVSc,
MMedVet (Med),
PhD, Dipl. ECVIM

IMAGING PERFORMED BY

Danielle RVT

HOSPITAL NAME

Orchard VC

REFERRING VET

Dr. Wade

INVOICE

69275

DATE

12/3/25

PRESENTING CLINICAL SIGNS

History: Reoccurring UTIs (E. Coli) despite multiple rounds of antibiotics. Been going on for about 2 months. Finished course of antibiotics yesterday

ULTRASONOGRAPHIC EXAMINATION OF THE ABDOMEN

Urinary System

The urinary bladder is small with a thickened and irregular appearance of the wall (up to 0.6 cm) with the rest of the wall having a normal thickness and smooth appearance. Normal anechoic urine with no sediment or uroliths evident.

Normal appearance of the trigone area, proximal urethra, and iliac blood vessels.

Normal appearance and size of the iliac lymph nodes. Ureters not visualized, which can be considered a normal finding.

Normal renal size (left measured 5.8 cm, right measured 6.1 cm), architecture, echogenic appearance, cortico-medullary differentiation, which maintains a 1:3 cortex to medulla ratio, pelvis, and capsule. No infarcts, mineralization or renoliths evident. Normal color flow pattern is evident in both kidneys.

Adrenal Glands

Normal shape, echogenic appearance, size, position, and appearance of the visible peri-adrenal vasculature. Left adrenal gland measured 0.69 cm in width. The right adrenal gland measured 0.77 cm in width.

Spleen

Normal size and echogenic appearance. Smooth homogenous parenchyma and regular curvilinear capsule. Normal volume of the splenic vasculature without any overt congestion or thrombosis evident. No inflammatory, neoplastic, infarction, or infiltrative changes evident. The spleen measured 2.4 cm in width. Incidental myelolipomas are present.

Liver

Normal size, echogenic appearance, portal markings, and regular curvilinear capsule. No nodules or masses evident. Normal appearance of the hepatic and portal vasculature.

Gallbladder

The gallbladder is full containing normal anechoic bile. Normal thickness and echogenic appearance of the wall. Normal size and appearance of the cystic and common bile duct.



PATIENT

Sadie Hoffman

SPECIES

Canine

BREED

Border Collie

SEX

Spayed female

AGE

12 years

WEIGHT

25.9 kg

INTERPRETED BY

Remo Lobetti, BVSc,
MMedVet (Med),
PhD, Dipl. ECVIM

IMAGING PERFORMED BY

Danielle RVT

HOSPITAL NAME

Orchard VC

REFERRING VET

Dr. Wade

INVOICE

69275

DATE

12/3/25

Gastrointestinal

Normal appearance of the stomach, duodenum, small intestine, ileo-cecal junction, and colon with no loss of layering, 1:3 muscularis to mucosa ratio, normal wall thickness and peristaltic activity, and no distension of the lumen.

Pancreas

The visible sections of the pancreas are of normal size and echogenic appearance with a regular capsule. Normal echogenic appearance of the mesentery and fat surrounding the pancreas.

Free Abdomen

Normal mesenteric lymph nodes.

No ascites evident.

ULTRASONOGRAPHIC FINDINGS

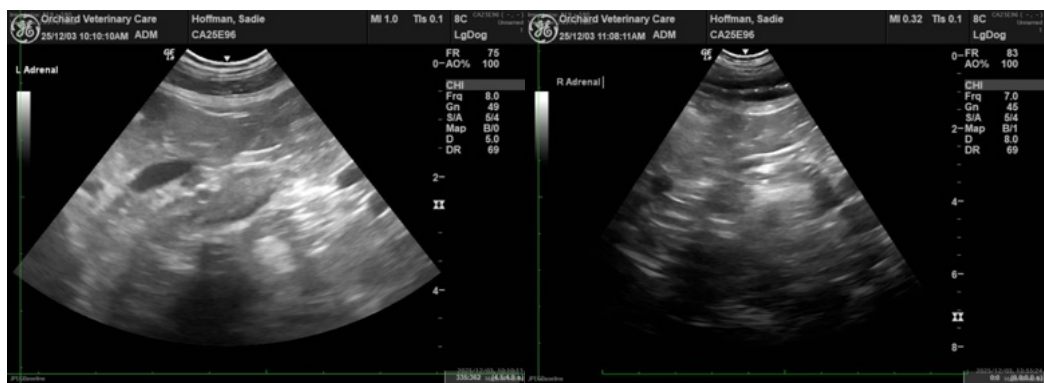
- Urinary bladder pathology.

INTERPRETATION OF THE FINDINGS & FURTHER RECOMMENDATIONS

Etiologies for the urinary bladder pathology would be chronic bacterial cystitis, granulomatous disease and possibly emerging neoplasia.

Further assessment would be urine culture and BRAF analysis and/or a catheter assisted aspirate/biopsy of the urinary bladder wall for cytology/histopathology and culture.

Specific therapy would be dependent on an etiological diagnosis. Management of chronic bacterial cystitis is long term antibiotic therapy being 4-6 weeks based on urine culture results with urine culture repeated 24 hours and a week after completion of the antibiotic therapy to ensure resolution of the bacterial infection.





PATIENT

Sadie Hoffman

SPECIES

Canine

BREED

Border Collie

SEX

Spayed female

AGE

12 years

WEIGHT

25.9 kg

INTERPRETED BY

Remo Lobetti, BVSc,
MMedVet (Med),
PhD, Dipl. ECVIM

IMAGING PERFORMED BY

Danielle RVT

HOSPITAL NAME

Orchard VC

REFERRING VET

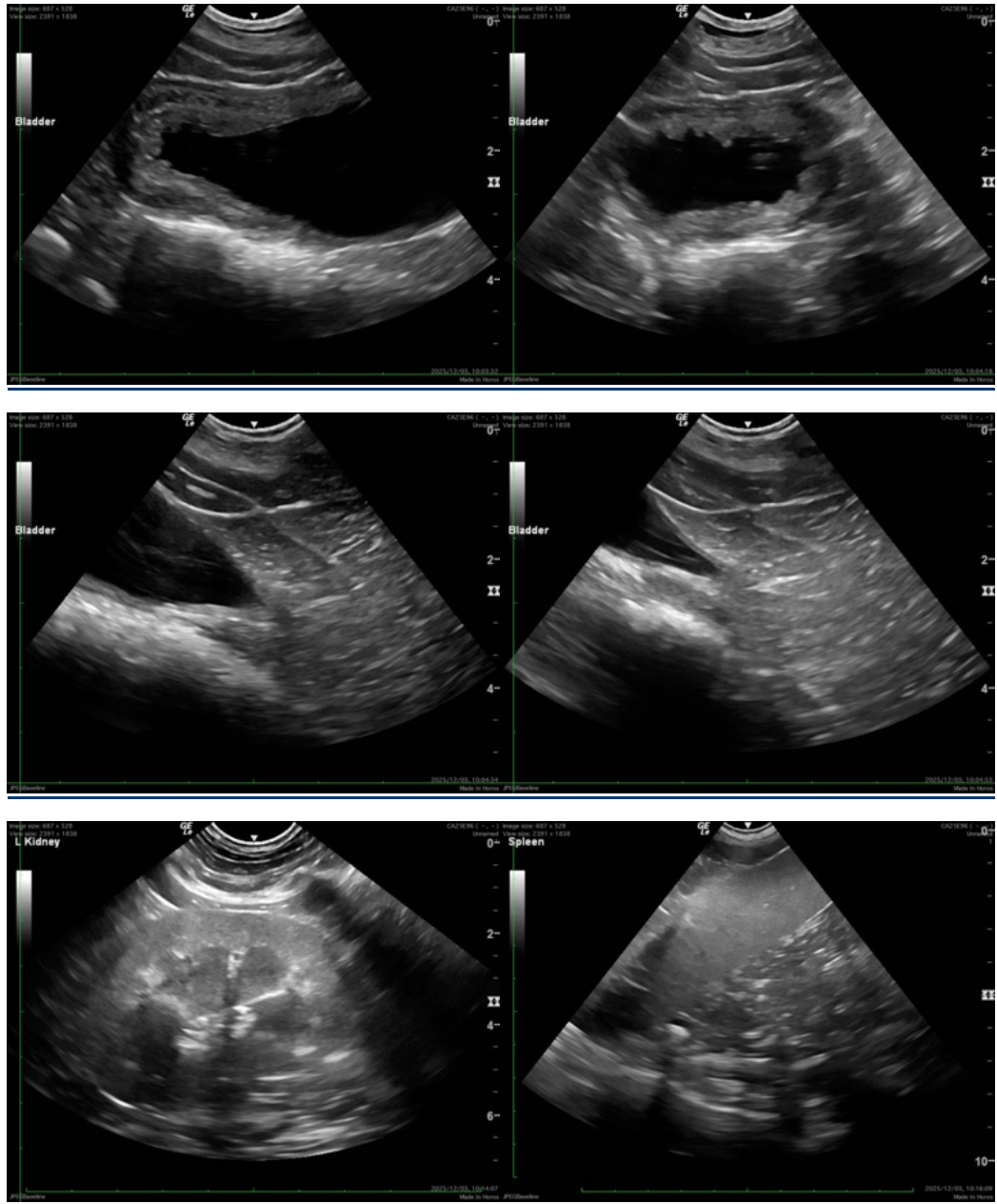
Dr. Wade

INVOICE

69275

DATE

12/3/25





PATIENT

Sadie Hoffman

SPECIES

Canine

BREED

Border Collie

SEX

Spayed female

AGE

12 years

WEIGHT

25.9 kg

INTERPRETED BY

Remo Lobetti, BVSc,
MMedVet (Med),
PhD, Dipl. ECVIM

IMAGING PERFORMED BY

Danielle RVT

HOSPITAL NAME

Orchard VC

REFERRING VET

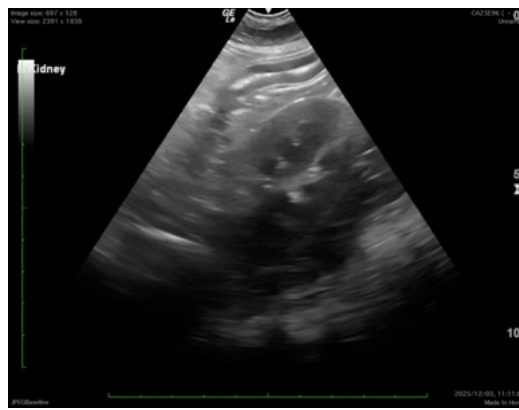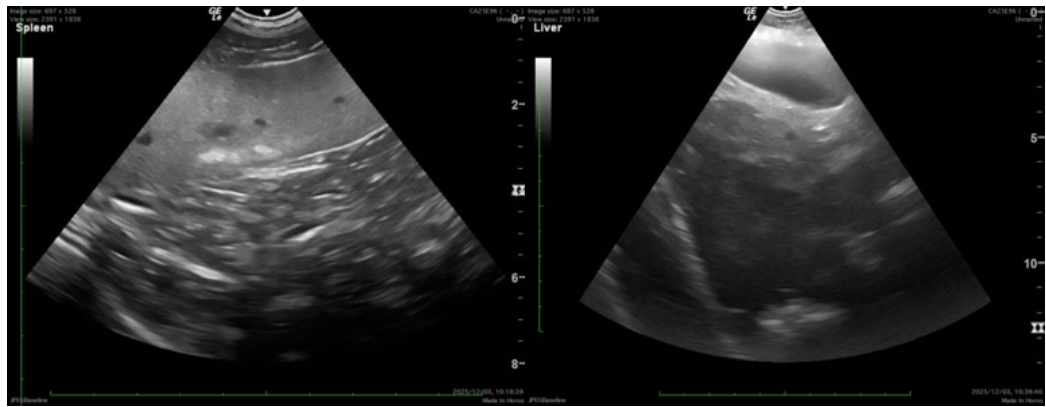
Dr. Wade

INVOICE

69275

DATE

12/3/25



The information and recommendations provided are based on the images presented by the referring veterinarian/sonographer. No evaluation can be communicated regarding pathology that was not visible in the image/video clips provided.

Thank you for this referral. If the clinical or image interpretation does not parallel your findings or if I can be of any further assistance please contact me.

Remo Lobetti, BVSc, MMedVet (Med), PhD, Dipl. ECVIM (Internal Medicine)

info@sonopath.com