



PATIENT

Onion Wright

SPECIES

Canine

BREED

Poodle Mix

SEX

Neutered male

AGE

9 years

WEIGHT

14 lbs

INTERPRETED BY

Remo Lobetti, BVSc,
MMedVet (Med),
PhD, Dipl. ECVIM

IMAGING PERFORMED BY

Dr. Nikki Wright

HOSPITAL NAME

Bush AH

REFERRING VET

Dr. Wright

INVOICE

69637

DATE

12/29/25

PRESENTING CLINICAL SIGNS

History: screening AUS. recently diagnosed single cutaneous MCT on left ventral abdomen near prepuce. planning to treat with stelfonta - chronic anxiety, fluoxetine 8mg PO SID - chronic mild GI sensitivity, occasional cerenia
Abnormal PE/Chem/CBC/UA Results: August 2025 - CBC/Chem/Lytes/T4/cPL - NSF

ULTRASONOGRAPHIC EXAMINATION OF THE ABDOMEN

Urinary System

The urinary bladder is full with a normal thickness and smooth appearance of the wall. Normal anechoic urine with no sediment or uroliths evident.

Normal appearance of the trigone area, proximal urethra, and iliac blood vessels.

Normal appearance and size of the iliac lymph nodes. Ureters not visualized, which can be considered a normal finding.

Normal renal size (left measured 3.8 cm, right measured 3.9 cm), architecture, echogenic appearance, cortico-medullary differentiation, which maintains a 1:3 cortex to medulla ratio, pelvis, and capsule. No infarcts, mineralization or renoliths evident.

The prostate is small and hypoechogenic.

Adrenal Glands

Normal shape, echogenic appearance, size, position, and appearance of the visible peri-adrenal vasculature. Left adrenal gland measured 0.35 cm in width. The right adrenal gland measured 1.41 cm in length x 0.36 cm and 0.34 cm in width.

Spleen

Normal size and echogenic appearance. Smooth homogenous parenchyma and regular curvilinear capsule. Normal volume of the splenic vasculature without any overt congestion or thrombosis evident. No inflammatory, neoplastic, infarction, or infiltrative changes evident. The spleen measured 1.5 cm in width

Liver

Normal size, echogenic appearance, portal markings, and regular curvilinear capsule. No nodules or masses evident. Normal appearance of the hepatic and portal vasculature.



PATIENT

Onion Wright

SPECIES

Canine

BREED

Poodle Mix

SEX

Neutered male

AGE

9 years

WEIGHT

14 lbs

INTERPRETED BY

Remo Lobetti, BVSc,
MMedVet (Med),
PhD, Dipl. ECVIM

IMAGING PERFORMED BY

Dr. Nikki Wright

HOSPITAL NAME

Bush AH

REFERRING VET

Dr. Wright

INVOICE

69637

DATE

12/29/25

Gallbladder

The gallbladder is full containing normal anechoic bile. Normal thickness and echogenic appearance of the wall. Normal size and appearance of the cystic and common bile duct.

Gastrointestinal

Normal appearance of the stomach, duodenum, small intestine, ileo-cecal junction, and colon with no loss of layering, 1:3 muscularis to mucosa ratio, normal wall thickness and peristaltic activity, and no distension of the lumen.

Pancreas

The visible sections of the pancreas are of normal size and echogenic appearance with a regular capsule. Normal echogenic appearance of the mesentery and fat surrounding the pancreas.

Free Abdomen

Normal mesenteric lymph nodes.

No ascites evident.

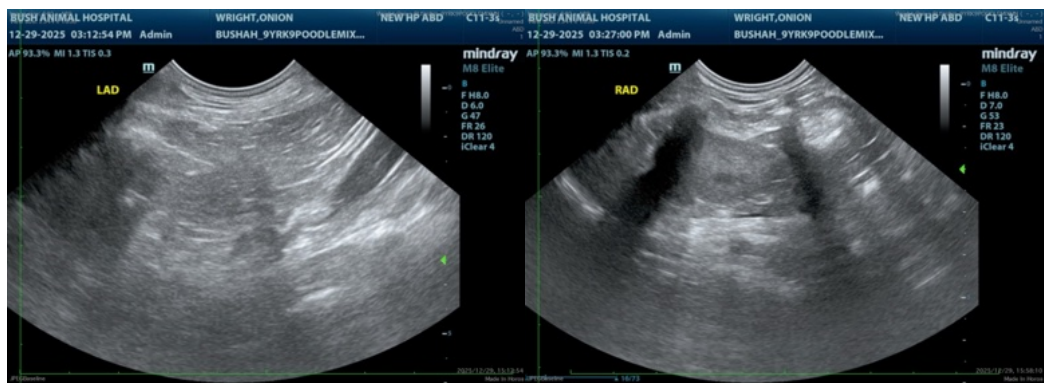
ULTRASONOGRAPHIC FINDINGS

- Normal ultrasound examination of the abdomen.

INTERPRETATION OF THE FINDINGS & FURTHER RECOMMENDATIONS

On this ultrasound there is no obvious evidence of metastatic mast cell tumor.

Further assessment that can be considered would be FNA cytology of the inguinal lymph node, spleen and liver to complete the metastatic screen.





PATIENT

Onion Wright

SPECIES

Canine

BREED

Poodle Mix

SEX

Neutered male

AGE

9 years

WEIGHT

14 lbs

INTERPRETED BY

Remo Lobetti, BVSc,
MMedVet (Med),
PhD, Dipl. ECVIM

IMAGING PERFORMED BY

Dr. Nikki Wright

HOSPITAL NAME

Bush AH

REFERRING VET

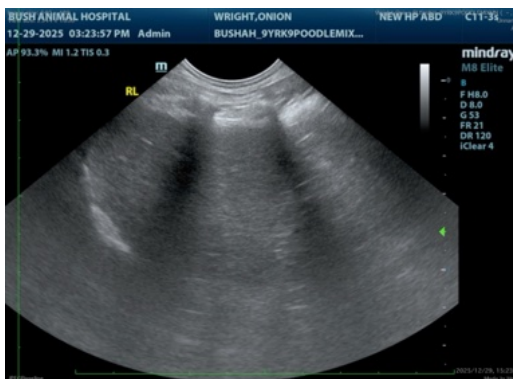
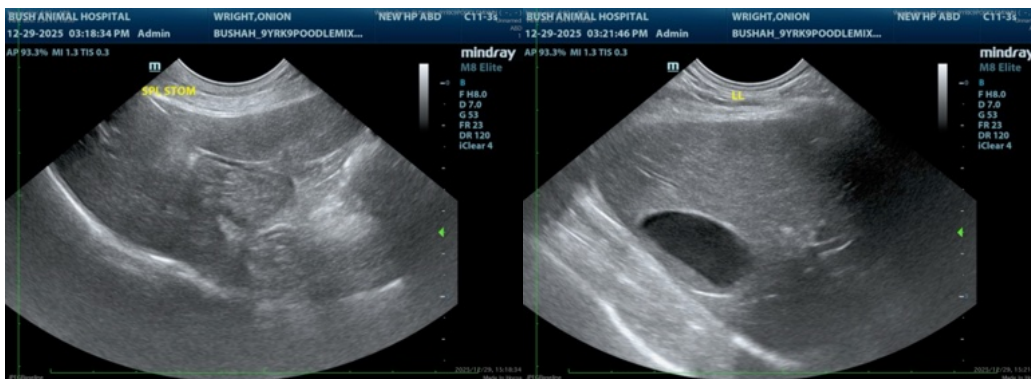
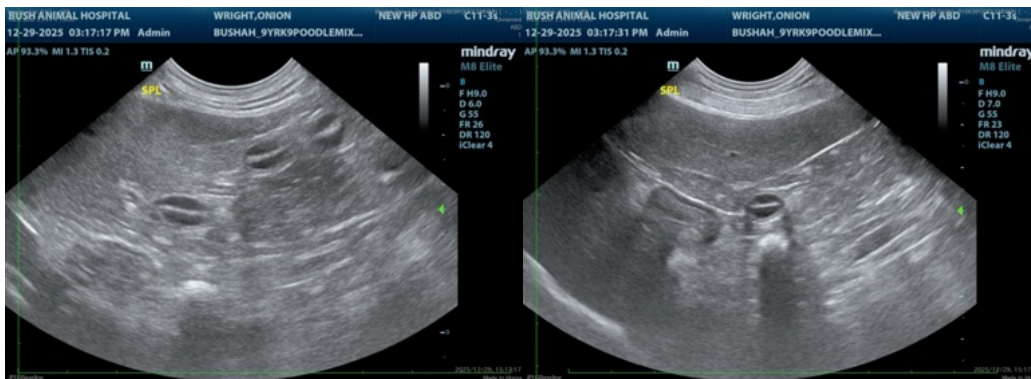
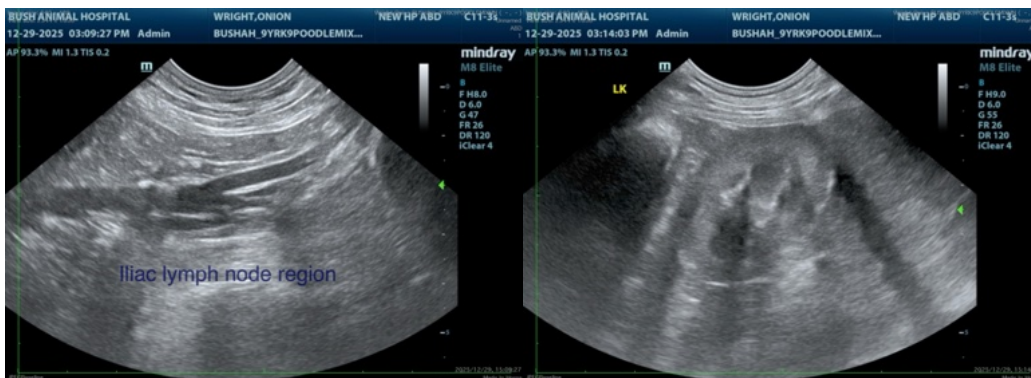
Dr. Wright

INVOICE

69637

DATE

12/29/25





PATIENT

Onion Wright

SPECIES

Canine

BREED

Poodle Mix

SEX

Neutered male

AGE

9 years

WEIGHT

14 lbs

INTERPRETED BY

Remo Lobetti, BVSc,
MMedVet (Med),
PhD, Dipl. ECVIM

IMAGING PERFORMED BY

Dr. Nikki Wright

HOSPITAL NAME

Bush AH

REFERRING VET

Dr. Wright

INVOICE

69637

DATE

12/29/25

The information and recommendations provided are based on the images presented by the referring veterinarian/sonographer. No evaluation can be communicated regarding pathology that was not visible in the image/video clips provided.

Thank you for this referral. If the clinical or image interpretation does not parallel your findings or if I can be of any further assistance please contact me.

Remo Lobetti, BVSc, MMedVet (Med), PhD, Dipl. ECVIM (Internal Medicine)

info@sonopath.com