



## PATIENT

Dixie Jones

## SPECIES

Canine

## BREED

Standard Poodle

## SEX

Spayed female

## AGE

12 years

## WEIGHT

46 lbs

## INTERPRETED BY

Remo Lobetti, BVSc,  
MMedVet (Med),  
PhD, Dipl. ECVIM

## IMAGING PERFORMED BY

Dr. Ashley Bowers

## HOSPITAL NAME

Bowling Green VC

## REFERRING VET

Dr. Bowers

## INVOICE

69631

## DATE

12/29/25

## PRESENTING CLINICAL SIGNS

History: U/S performed on 12/24 - presented on 12/20 for random vomiting on and off for the past couple of weeks with increasing frequency, lethargic, decreased appetite  
Increased ALT 198 GGT 32 Tbil - 1 QPL - 339

## ULTRASONOGRAPHIC EXAMINATION OF THE ABDOMEN

### *Urinary System*

The urinary bladder is small with a normal thickness and smooth appearance of the wall. Normal anechoic urine with no sediment or uroliths evident.

Normal appearance of the trigone area, proximal urethra, and iliac blood vessels.

Normal appearance and size of the iliac lymph nodes. Ureters not visualized, which can be considered a normal finding.

Normal renal size (left measured 5.0 cm, right measured 5.5 cm), architecture, echogenic appearance, cortico-medullary differentiation, which maintains a 1:3 cortex to medulla ratio, pelvis, and capsule. No infarcts, mineralization or renoliths evident.

### *Adrenal Glands*

The left adrenal gland is normal in shape, echogenic appearance, size, position, and appearance of the visible peri-adrenal vasculature. Left adrenal gland measured 0.47 cm in width. The right adrenal gland was not visualized.

### *Spleen*

Normal size and echogenic appearance. Smooth homogenous parenchyma and regular curvilinear capsule. Normal volume of the splenic vasculature without any overt congestion or thrombosis evident. Incidental myelolipomas were present. No inflammatory, neoplastic, infarction, or infiltrative changes evident. The spleen measured 1.6 cm in width.

### *Liver*

Normal size, echogenic appearance, portal markings, and regular curvilinear capsule. No nodules or masses evident. Normal appearance of the hepatic and portal vasculature.

### *Gallbladder*

The gallbladder is full almost distended containing a large amount of both adhered and non-adhered, hyperechogenic sediment with the adhered sediment arranged in a stellate pattern. Normal thickness and echogenic appearance of the wall. Normal size and appearance of the cystic and common bile duct.



## PATIENT

Dixie Jones

## SPECIES

Canine

## BREED

Standard Poodle

## SEX

Spayed female

## AGE

12 years

## WEIGHT

46 lbs

## INTERPRETED BY

Remo Lobetti, BVSc,  
MMedVet (Med),  
PhD, Dipl. ECVIM

## IMAGING PERFORMED BY

Dr. Ashley Bowers

## HOSPITAL NAME

Bowling Green VC

## REFERRING VET

Dr. Bowers

## INVOICE

69631

## DATE

12/29/25

## *Gastrointestinal*

Normal appearance of the stomach, duodenum, small intestine, ileo-cecal junction, and colon with no loss of layering, 1:3 muscularis to mucosa ratio, normal wall thickness and peristaltic activity, and no distension of the lumen.

## *Pancreas*

The visible sections of the pancreas are of normal size and echogenic appearance with a regular capsule. Normal echogenic appearance of the mesentery and fat surrounding the pancreas.

## *Free Abdomen*

Normal mesenteric lymph nodes.

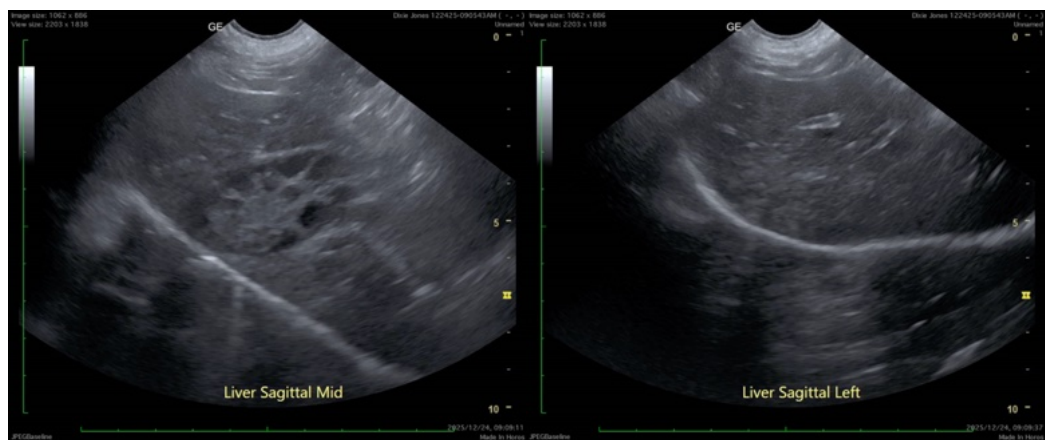
No ascites evident.

## ULTRASONOGRAPHIC FINDINGS

- Mucocele.

## INTERPRETATION OF THE FINDINGS & FURTHER RECOMMENDATIONS

Management of the mucocele would either be cholecystectomy or medical treatment with Ursodiol with regular monitoring of liver enzyme activity and ultrasound.





## PATIENT

Dixie Jones

## SPECIES

Canine

## BREED

Standard Poodle

## SEX

Spayed female

## AGE

12 years

## WEIGHT

46 lbs

## INTERPRETED BY

Remo Lobetti, BVSc,  
MMedVet (Med),  
PhD, Dipl. ECVIM

## IMAGING PERFORMED BY

Dr. Ashley Bowers

## HOSPITAL NAME

Bowling Green VC

## REFERRING VET

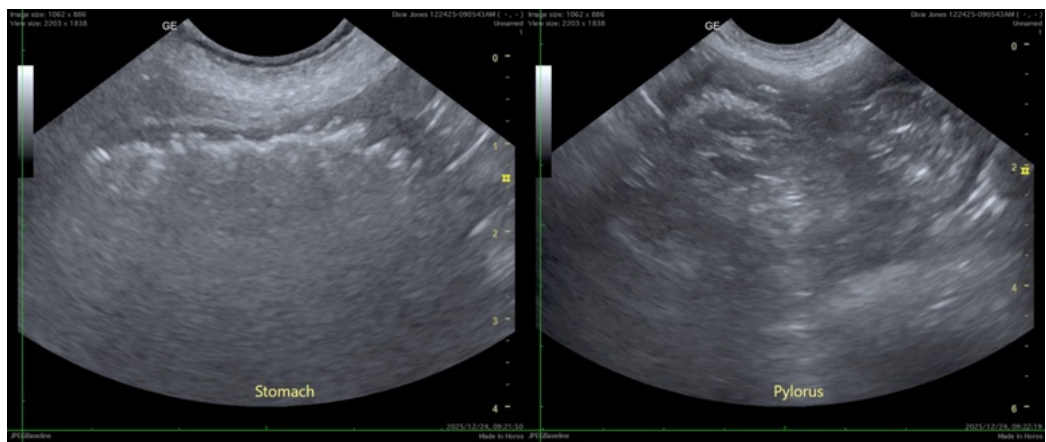
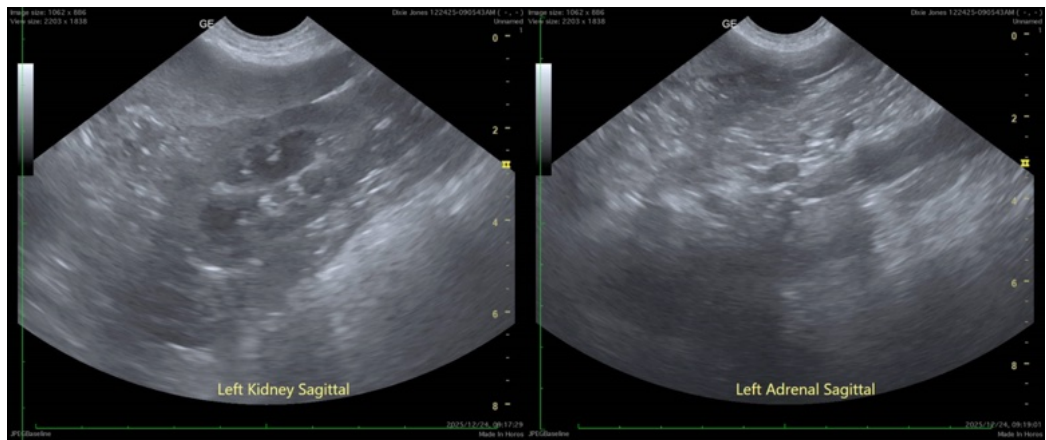
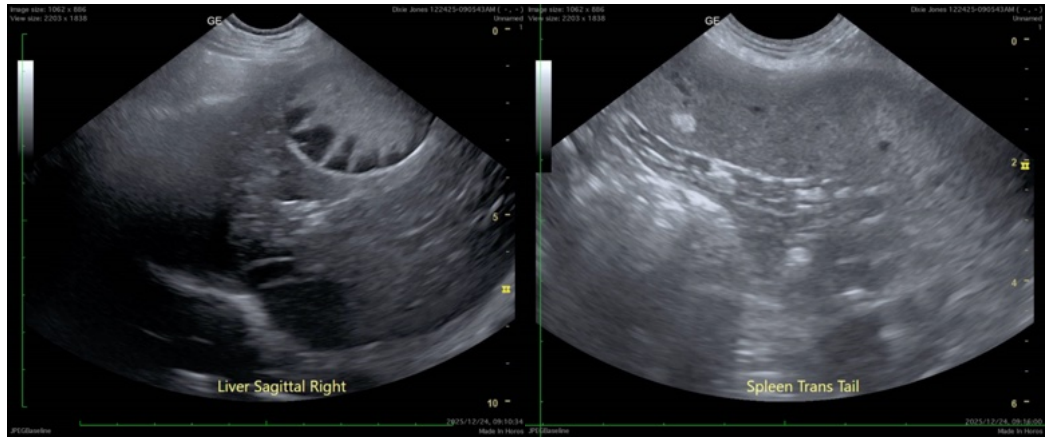
Dr. Bowers

## INVOICE

69631

## DATE

12/29/25





## PATIENT

Dixie Jones

## SPECIES

Canine

## BREED

Standard Poodle

## SEX

Spayed female

## AGE

12 years

## WEIGHT

46 lbs

## INTERPRETED BY

Remo Lobetti, BVSc,  
MMedVet (Med),  
PhD, Dipl. ECVIM

## IMAGING PERFORMED BY

Dr. Ashley Bowers

## HOSPITAL NAME

Bowling Green VC

## REFERRING VET

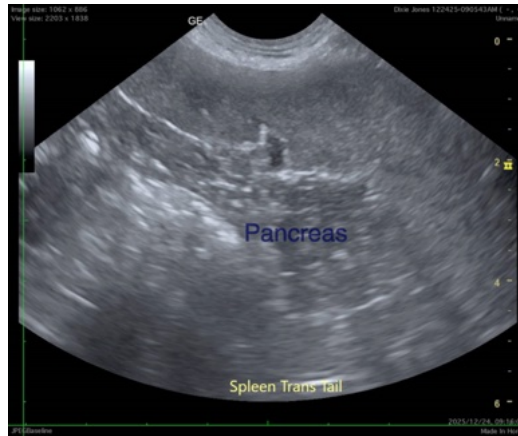Dr. Bowers

## INVOICE

69631

## DATE

12/29/25



The information and recommendations provided are based on the images presented by the referring veterinarian/sonographer. No evaluation can be communicated regarding pathology that was not visible in the image/video clips provided.

Thank you for this referral. If the clinical or image interpretation does not parallel your findings or if I can be of any further assistance please contact me.

Remo Lobetti, BVSc, MMedVet (Med), PhD, Dipl. ECVIM (Internal Medicine)

[info@sonopath.com](mailto:info@sonopath.com)