



PATIENT

Quinn McAtee

SPECIES

Canine

BREED

Lab Heeler Mix

SEX

Spayed female

AGE

12 years

WEIGHT

55.7 lbs

INTERPRETED BY

Remo Lobetti, BVSc,
MMedVet (Med),
PhD, Dipl. ECVIM

IMAGING PERFORMED BY

Karla Schultz

HOSPITAL NAME

Northshore VH

REFERRING VET

Dr. Schultz

INVOICE

69591

DATE

12/24/25

PRESENTING CLINICAL SIGNS

History: AUS scan d/t mild progressive LEZ increase, two recent events of ptialism that self-resolved, and one event last week of possible seizure (full-body spasm/shaking x a few minutes without loss of consciousness/no defecation or urination). P has HX of iris stage 2 renal dysfunction and urinary sphincter incontinence. No pu/PD, normal appetite and energy.

Abnormal PE/Chem/CBC/UA Results: PE: H/L auscultate WNL, good BCS with unremarkable Ortho exam, Neuro exam WNL, multiple soft SC masses throughout trunk, no pain with abdominal palpation, CBC: WNL chem: inc LEZ (ALT 275 prev 157 on 10/9/25, AST 60, ALP 174; bili and GGT WNL, cholesterol WNL), high-NL renal values (SDMA 13, creat 1.4, BUN 23). Electrolytes, protein levels, BG WNL u/a: USG 1.010 with UPC 0.7; no bacteriuria or pyuria leptu witness test: negative

ULTRASONOGRAPHIC EXAMINATION OF THE ABDOMEN

Urinary System

The urinary bladder is full with a normal thickness and smooth appearance of the wall. Normal anechoic urine with no sediment or uroliths evident.

Normal appearance of the trigone area, proximal urethra, and iliac blood vessels.

Normal appearance and size of the iliac lymph nodes. Ureters not visualized, which can be considered a normal finding.

Normal renal size (left measured 5.2 cm, right measured 5.6 cm), increased echogenic appearance, some loss of cortico-medullary differentiation, and normal pelvis and capsule. No infarcts, mineralization or renoliths evident. Normal color flow pattern is evident in both kidneys.

Adrenal Glands

Normal shape, echogenic appearance, size, position, and appearance of the visible peri-adrenal vasculature. Left adrenal gland measured 0.42 cm and 0.46 cm in width. The right adrenal gland measured 0.5 cm and 0.56 cm in width.

Spleen

Normal size and echogenic appearance. Smooth homogenous parenchyma and regular curvilinear capsule. Normal volume of the splenic vasculature without any overt congestion or thrombosis evident. No inflammatory, neoplastic, infarction, or infiltrative changes evident. The spleen measured 2.2 cm in width.

Liver

Normal size with a patchy, mottled echogenic and coarse appearance, prominent portal markings, and regular curvilinear capsule. No nodules or masses evident. Normal appearance of the hepatic and portal vasculature.



PATIENT

Quinn McAtee

SPECIES

Canine

BREED

Lab Heeler Mix

SEX

Spayed female

AGE

12 years

WEIGHT

55.7 lbs

INTERPRETED BY

Remo Lobetti, BVSc,
MMedVet (Med),
PhD, Dipl. ECVIM

IMAGING PERFORMED BY

Karla Schultz

HOSPITAL NAME

Northshore VH

REFERRING VET

Dr. Schultz

INVOICE

69591

DATE

12/24/25

Gallbladder

The gallbladder is full containing small amount of non-adhered hyperechogenic sediment. Normal thickness and echogenic appearance of the wall. Normal size and appearance of the cystic and common bile duct.

Gastrointestinal

Normal appearance of the stomach, duodenum, small intestine, ileo-cecal junction, and colon with no loss of layering, 1:3 muscularis to mucosa ratio, normal wall thickness and peristaltic activity, and no distension of the lumen. Fecal material was present in the colon.

Pancreas

The visible sections of the pancreas are of normal size and echogenic appearance with a regular capsule. Normal echogenic appearance of the mesentery and fat surrounding the pancreas.

Free Abdomen

Normal mesenteric lymph nodes.

No ascites evident.

ULTRASONOGRAPHIC FINDINGS

- Hepatopathy.
- Gallbladder sediment.
- Age related renal changes versus early chronic kidney disease.

INTERPRETATION OF THE FINDINGS & FURTHER RECOMMENDATIONS

The likely etiologies for the hepatopathy would be reactive hyperplasia, early nodular hyperplasia, vacuolar and metabolic with hepatitis and infiltrative neoplasia a highly unlikely differential diagnosis.

The gallbladder sediment is most likely an incidental finding.

Further assessment of the hepatopathy would be FNA cytology; however, a tru cut or wedge biopsy may be required for a final etiological diagnosis.

Further assessment of the kidneys (if not already done) would be blood pressure measurements.

Specific therapy would be dependent on an etiological diagnosis.

Symptomatic management of the hepatopathy and gallbladder sediment would be the use of Ursodiol with regular monitoring of liver enzyme activity.



PATIENT

Quinn McAtee

SPECIES

Canine

BREED

Lab Heeler Mix

SEX

Spayed female

AGE

12 years

WEIGHT

55.7 lbs

INTERPRETED BY

Remo Lobetti, BVSc,
MMedVet (Med),
PhD, Dipl. ECVIM

**IMAGING
PERFORMED BY**

Karla Schultz

HOSPITAL NAME

Northshore VH

REFERRING VET

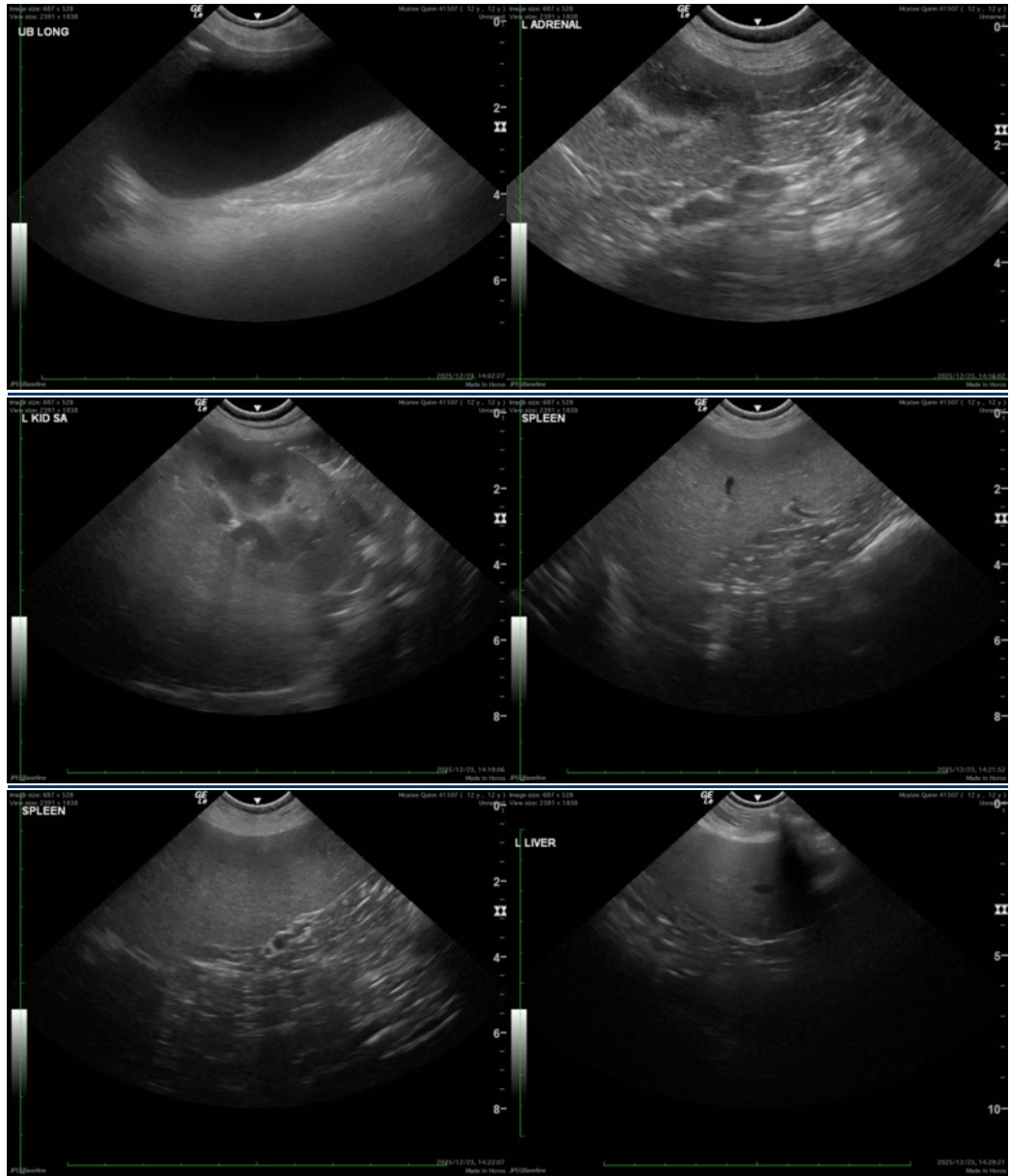
Dr. Schultz

INVOICE

69591

DATE

12/24/25





PATIENT

Quinn McAtee

SPECIES

Canine

BREED

Lab Heeler Mix

SEX

Spayed female

AGE

12 years

WEIGHT

55.7 lbs

INTERPRETED BY

Remo Lobetti, BVSc,
MMedVet (Med),
PhD, Dipl. ECVIM

IMAGING PERFORMED BY

Karla Schultz

HOSPITAL NAME

Northshore VH

REFERRING VET

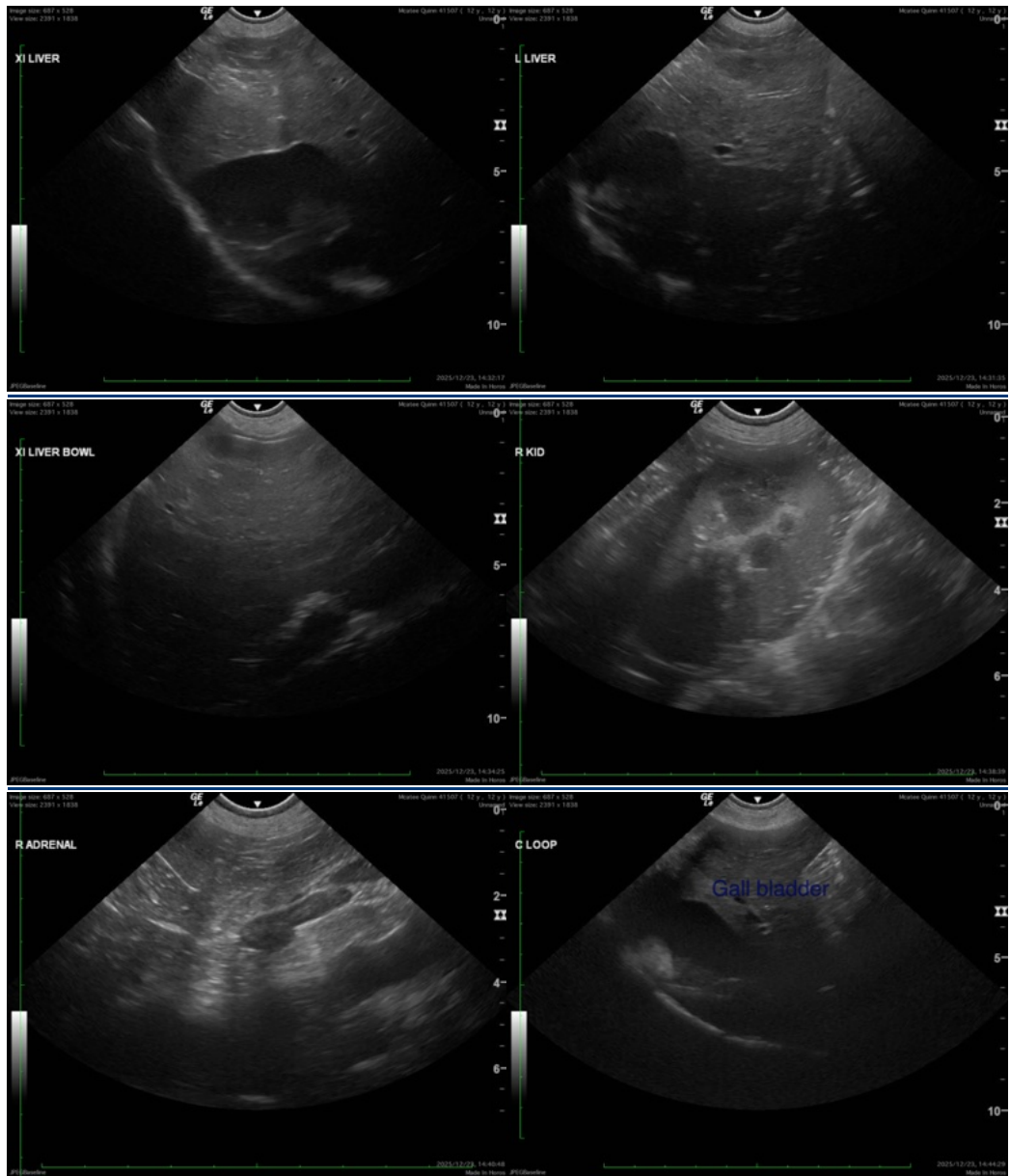
Dr. Schultz

INVOICE

69591

DATE

12/24/25



The information and recommendations provided are based on the images presented by the referring veterinarian/sonographer. No evaluation can be communicated regarding pathology that was not visible in the image/video clips provided.

Thank you for this referral. If the clinical or image interpretation does not parallel your findings or if I can be of any further assistance please contact me.

Remo Lobetti, BVSc, MMedVet (Med), PhD, Dipl. ECVIM (Internal Medicine)

info@sonopath.com