



## PATIENT

Hansel Lacson

## SPECIES

Canine

## BREED

Dachshund

## SEX

Neutered male

## AGE

2 years

## WEIGHT

23.78 lbs

## INTERPRETED BY

Remo Lobetti, BVSc,  
MMedVet (Med),  
PhD, Dipl. ECVIM

## IMAGING PERFORMED BY

Dr. Johnson

## HOSPITAL NAME

Craig Road AH

## REFERRING VET

Dr. Johnson

## INVOICE

69606

## DATE

12/24/25

## PRESENTING CLINICAL SIGNS

History: P is a 2yr 1mo old MN Dachshund presenting for not eating for the past 2-3 days and acting lethargic. O's are currently out of town, so a member of the family has been going over to their house to take care of P. They noted for the past 2-3 days, P was not interested in eating (which is unusual since P is usually a very good eater). They also noted P acting more lethargic than usual. O brought P in on an emergency basis. P had been otherwise doing fine with no other significant medical history. Drinking, defecating, and urinating within normal limits. No coughing, sneezing, vomiting, or diarrhea noted by owner. No known allergies to vaccines/ medication. P has no recent travel history. Current medications: None

## ULTRASONOGRAPHIC EXAMINATION OF THE ABDOMEN

### Urinary System

The urinary bladder is full with a normal thickness and smooth appearance of the wall. Normal anechoic urine with no sediment or uroliths evident.

Normal appearance of the trigone area, proximal urethra, and iliac blood vessels.

Normal appearance and size of the iliac lymph nodes. Ureters not visualized, which can be considered a normal finding.

Normal renal size (left measured 4.8 cm, right measured 5.1 cm, architecture, echogenic appearance, cortico-medullary differentiation, which maintains a 1:3 cortex to medulla ratio, pelvis, and capsule. No infarcts, mineralization or renoliths evident.

### Adrenal Glands

Normal shape, echogenic appearance, size, position, and appearance of the visible peri-adrenal vasculature. Left adrenal gland measured 0.38 cm and 0.39 cm in width. The right adrenal gland measured 0.47 cm and 0.43 cm in width.

### Spleen

Normal size and echogenic appearance. Smooth homogenous parenchyma and regular curvilinear capsule. Normal volume of the splenic vasculature without any overt congestion or thrombosis evident. No inflammatory, neoplastic, infarction, or infiltrative changes evident. The spleen measured 1.5 cm in width.

### Liver

Normal size, echogenic appearance, portal markings, and regular curvilinear capsule. No nodules or masses evident. Normal appearance of the hepatic and portal vasculature.



## PATIENT

Hansel Lacson

## SPECIES

Canine

## BREED

Dachshund

## SEX

Neutered male

## AGE

2 years

## WEIGHT

23.78 lbs

## INTERPRETED BY

Remo Lobetti, BVSc,  
MMedVet (Med),  
PhD, Dipl. ECVIM

## IMAGING PERFORMED BY

Dr. Johnson

## HOSPITAL NAME

Craig Road AH

## REFERRING VET

Dr. Johnson

## INVOICE

69606

## DATE

12/24/25

## Gallbladder

The gallbladder is full containing normal anechoic bile. Normal thickness and echogenic appearance of the wall. Normal size and appearance of the cystic and common bile duct.

## Gastrointestinal

Normal appearance of the stomach, duodenum, small intestine, ileo-cecal junction, and colon with no loss of layering, 1:3 muscularis to mucosa ratio, normal wall thickness and peristaltic activity, and no distension of the lumen. Fecal material is present in the colon.

## Pancreas

The visible sections of the pancreas are of normal size and echogenic appearance with a regular capsule. Normal echogenic appearance of the mesentery and fat surrounding the pancreas.

## Free Abdomen

Normal mesenteric lymph nodes.

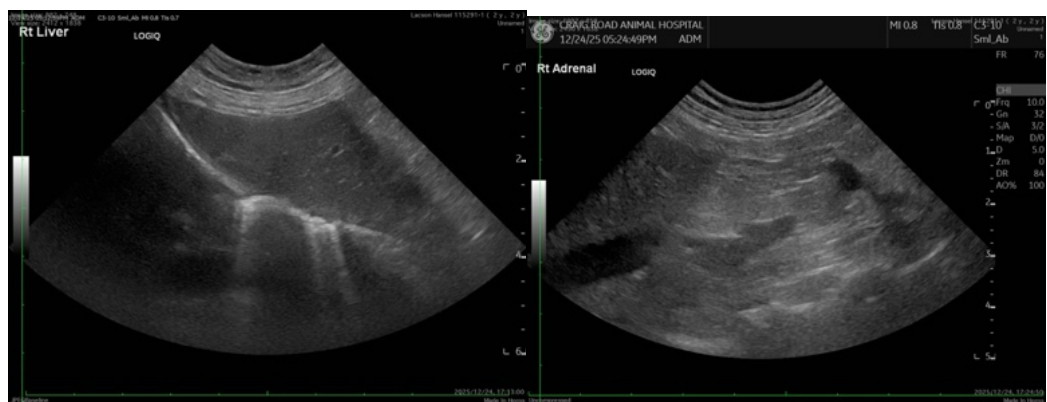
No ascites evident.

## ULTRASONOGRAPHIC FINDINGS

- Normal ultrasound examination of the abdomen.

## INTERPRETATION OF THE FINDINGS & FURTHER RECOMMENDATIONS

On this ultrasound there is no obvious etiology for the presenting clinical signs.





## PATIENT

Hansel Lacson

## SPECIES

Canine

## BREED

Dachshund

## SEX

Neutered male

## AGE

2 years

## WEIGHT

23.78 lbs

## INTERPRETED BY

Remo Lobetti, BVSc,  
MMedVet (Med),  
PhD, Dipl. ECVIM

## IMAGING PERFORMED BY

Dr. Johnson

## HOSPITAL NAME

Craig Road AH

## REFERRING VET

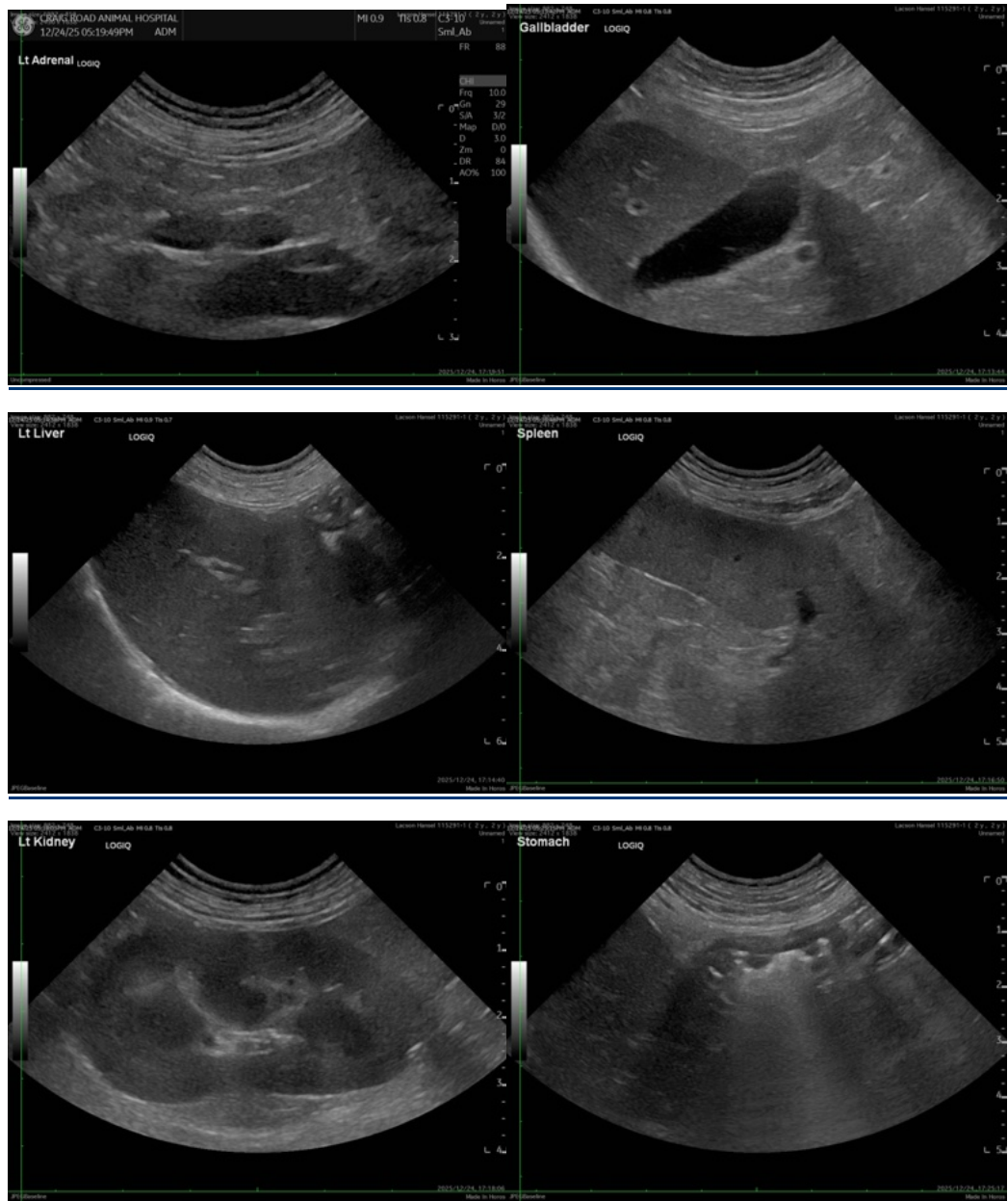
Dr. Johnson

## INVOICE

69606

## DATE

12/24/25





## PATIENT

Hansel Lacson

## SPECIES

Canine

## BREED

Dachshund

## SEX

Neutered male

## AGE

2 years

## WEIGHT

23.78 lbs

## INTERPRETED BY

Remo Lobetti, BVSc,  
MMedVet (Med),  
PhD, Dipl. ECVIM

## IMAGING PERFORMED BY

Dr. Johnson

## HOSPITAL NAME

Craig Road AH

## REFERRING VET

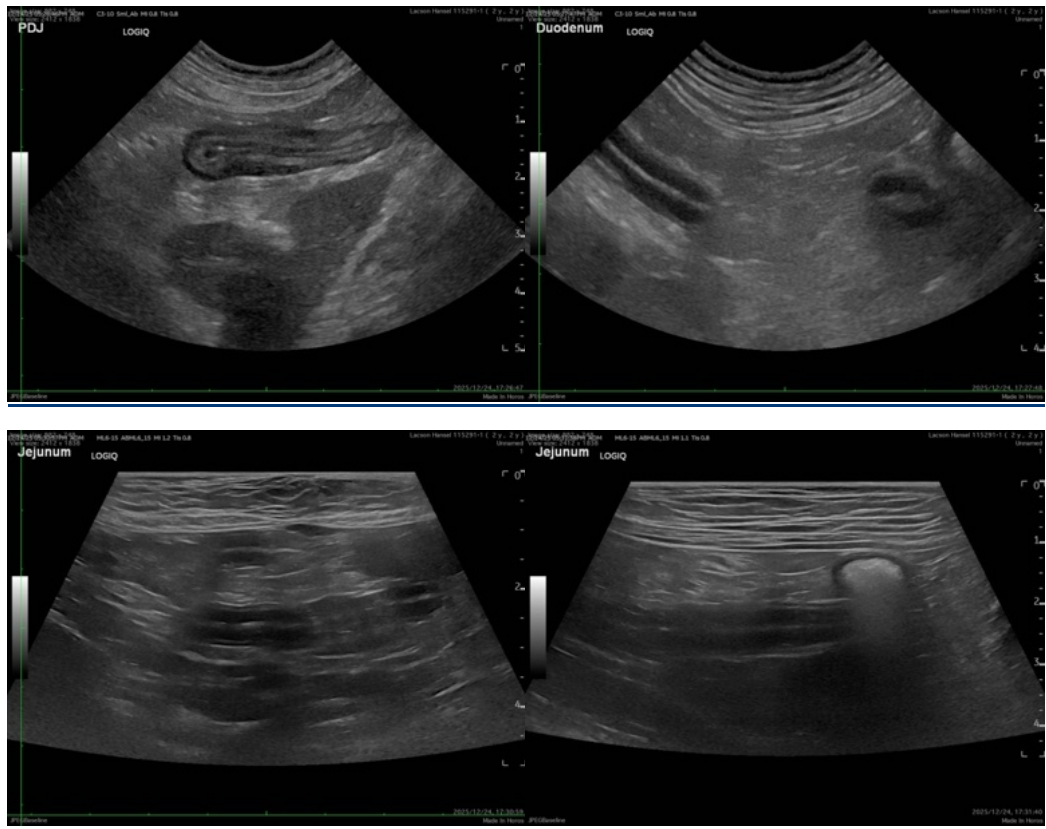
Dr. Johnson

## INVOICE

69606

## DATE

12/24/25



The information and recommendations provided are based on the images presented by the referring veterinarian/sonographer. No evaluation can be communicated regarding pathology that was not visible in the image/video clips provided.

Thank you for this referral. If the clinical or image interpretation does not parallel your findings or if I can be of any further assistance please contact me.

Remo Lobetti, BVSc, MMedVet (Med), PhD, Dipl. ECVIM (Internal Medicine)

[info@sonopath.com](mailto:info@sonopath.com)