



PATIENT

Bear Sciarrino

SPECIES

Canine

BREED

Shipperke

SEX

Neutered male

AGE

14 years

WEIGHT

14 lbs

INTERPRETED BY

Remo Lobetti, BVSc,
MMedVet (Med),
PhD, Dipl. ECVIM

IMAGING PERFORMED BY

Melissa Rosen

HOSPITAL NAME

South Bellmore
Veterinary Group

REFERRING VET

Dr. Franko

INVOICE

69583

DATE

12/24/25

PRESENTING CLINICAL SIGNS

History: wellness bloodwork, abnormalities found elevated liver enzymes hyperalbuminemia and globulinemia mild dec WBC r/o inflammation, infection, neoplasia ...

Abnormal PE/Chem/CBC/UA Results: alb 4.5 alt 195 ast 111 alp 1196

ULTRASONOGRAPHIC EXAMINATION OF THE ABDOMEN

Urinary System

The urinary bladder is full with a normal thickness and smooth appearance of the wall. Normal anechoic urine with no sediment or uroliths evident.

Normal appearance of the trigone area, proximal urethra, and iliac blood vessels.

Normal appearance and size of the iliac lymph nodes. Ureters not visualized, which can be considered a normal finding.

Normal renal size (left measured 3.9 cm, right measured 4.0 cm), architecture, echogenic appearance, cortico-medullary differentiation, which maintains a 1:3 cortex to medulla ratio, pelvis, and capsule. No infarcts, mineralization or renoliths evident. A few, small, incidental cortical cysts are present in both kidneys. Normal color flow pattern is evident in both kidneys.

The prostate is small and hypoechogenic.

Adrenal Glands

Normal shape, echogenic appearance, size, position, and appearance of the visible peri-adrenal vasculature. Left adrenal gland measured 0.46 cm and 0.45 cm in width. The right adrenal gland measured 0.48 cm in width.

Spleen

Normal size and echogenic appearance. Smooth homogenous parenchyma and regular curvilinear capsule. Normal volume of the splenic vasculature without any overt congestion or thrombosis evident. No inflammatory, neoplastic, infarction, or infiltrative changes evident. The spleen measured 1.4 cm in width.

Liver

Normal size with a diffuse, mottled echogenic and coarse appearance, prominent portal markings, and regular curvilinear capsule. No nodules or masses evident. Normal appearance of the hepatic and portal vasculature.



PATIENT

Bear Sciarrino

SPECIES

Canine

BREED

Shipperke

SEX

Neutered male

AGE

14 years

WEIGHT

14 lbs

INTERPRETED BY

Remo Lobetti, BVSc,
MMedVet (Med),
PhD, Dipl. ECVIM

IMAGING PERFORMED BY

Melissa Rosen

HOSPITAL NAME

South Bellmore
Veterinary Group

REFERRING VET

Dr. Franko

INVOICE

69583

DATE

12/24/25

Gallbladder

The gallbladder is full containing a moderate amount of non-adhered, hyperechogenic sediment. Normal thickness and echogenic appearance of the wall. Normal size and appearance of the cystic and common bile duct.

Gastrointestinal

Normal appearance of the stomach, duodenum, small intestine, ileo-cecal junction, and colon with no loss of layering, 1:3 muscularis to mucosa ratio, normal wall thickness and peristaltic activity, and no distension of the lumen.

Pancreas

The visible sections of the pancreas are of normal size and echogenic appearance with a regular capsule. Normal echogenic appearance of the mesentery and fat surrounding the pancreas.

Free Abdomen

Normal mesenteric lymph nodes.

No ascites evident.

ULTRASONOGRAPHIC FINDINGS

- Hepatopathy.
- Gallbladder sediment.

INTERPRETATION OF THE FINDINGS & FURTHER RECOMMENDATIONS

The likely etiologies for the hepatopathy would be age related reactive hyperplasia, early nodular hyperplasia, vacuolar and metabolic with hepatitis and infiltrative neoplasia a less likely differential diagnosis.

The gallbladder sediment is most likely an incidental finding.

Further assessment would be FNA cytology of the liver; however, a tru cut or wedge biopsy may be required for a final etiological diagnosis.

Specific therapy would be dependent on an etiological diagnosis.

Symptomatic management that can be considered would be the use of Ursodiol with regular monitoring of liver enzyme activity.



PATIENT

Bear Sciarrino

SPECIES

Canine

BREED

Shipperke

SEX

Neutered male

AGE

14 years

WEIGHT

14 lbs

INTERPRETED BY

Remo Lobetti, BVSc,
MMedVet (Med),
PhD, Dipl. ECVIM

IMAGING PERFORMED BY

Melissa Rosen

HOSPITAL NAME

South Bellmore
Veterinary Group

REFERRING VET

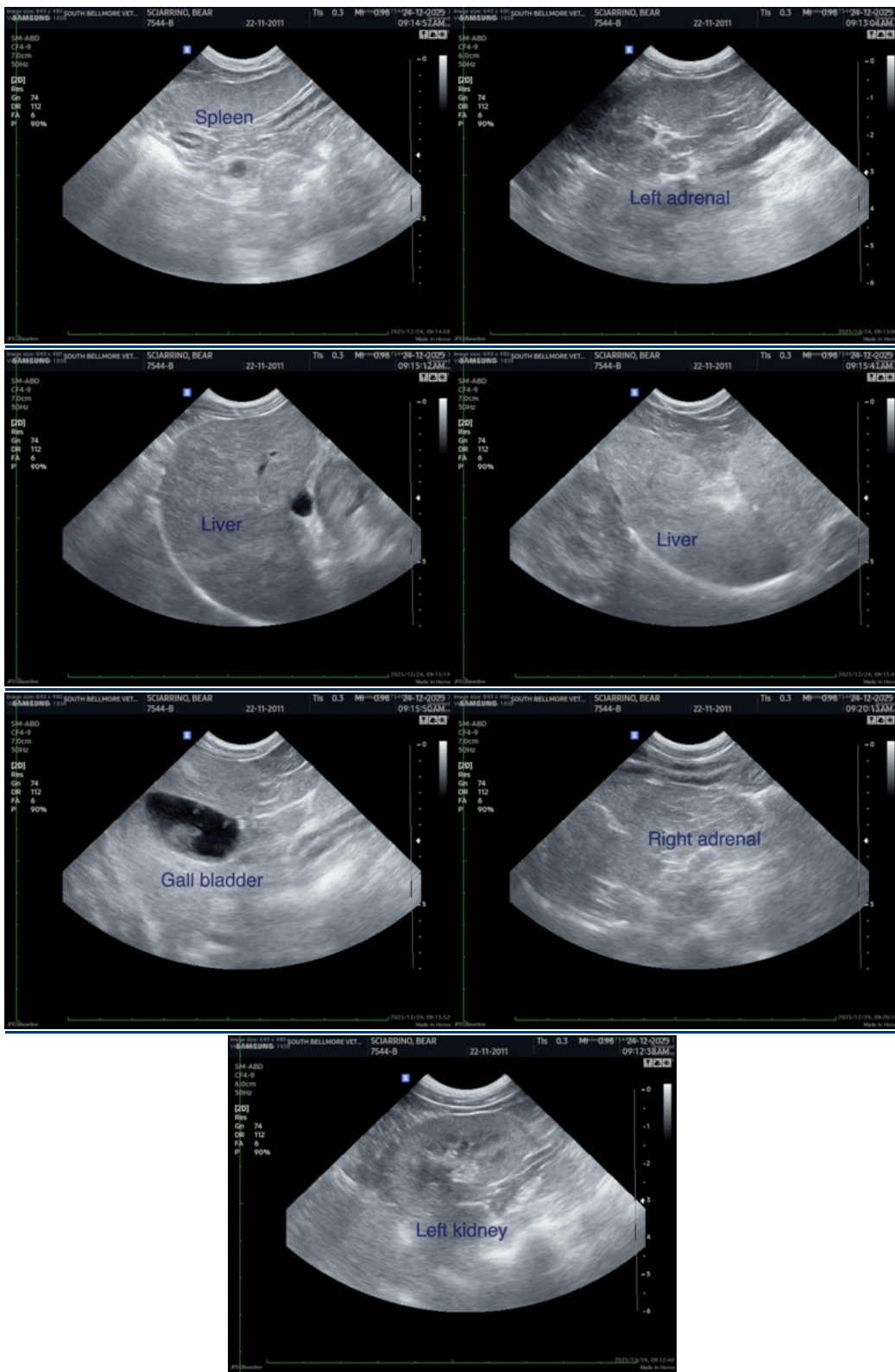
Dr. Franko

INVOICE

69583

DATE

12/24/25





PATIENT

Bear Sciarrino

SPECIES

Canine

BREED

Shipperke

SEX

Neutered male

AGE

14 years

WEIGHT

14 lbs

INTERPRETED BY

Remo Lobetti, BVSc,
MMedVet (Med),
PhD, Dipl. ECVIM

IMAGING PERFORMED BY

Melissa Rosen

HOSPITAL NAME

South Bellmore
Veterinary Group

REFERRING VET

Dr. Franko

INVOICE

69583

DATE

12/24/25

The information and recommendations provided are based on the images presented by the referring veterinarian/sonographer. No evaluation can be communicated regarding pathology that was not visible in the image/video clips provided.

Thank you for this referral. If the clinical or image interpretation does not parallel your findings or if I can be of any further assistance please contact me.

Remo Lobetti, BVSc, MMedVet (Med), PhD, Dipl. ECVIM (Internal Medicine)

info@sonopath.com