



PATIENT

Sophie Cox

SPECIES

Canine

BREED

Plott Hound Mix

SEX

Spayed female

AGE

9 years

WEIGHT

114 lbs

INTERPRETED BY

Remo Lobetti, BVSc,
MMedVet (Med),
PhD, Dipl. ECVIM

IMAGING PERFORMED BY

Brian Klug

HOSPITAL NAME

Sondel Family VC

REFERRING VET

Dr. Mortensen

INVOICE

69552

DATE

12/23/25

PRESENTING CLINICAL SIGNS

History: Kara Wallisch Presenting Complaint: Sophie presents for follow-up after specialist consultation regarding enlarged lymph nodes Patient History: Recent specialist visit found enlarged lymph nodes throughout body Lymph node cytology from three sites (right mandibular, left mandibular, left popliteal) showed reactive changes Oral mass present with purulent discharge Dental procedure scheduled but postponed pending lymph node investigation Recent blood work showed normal white blood cell and red blood cell counts Heartworm/tick-borne disease test performed November 13th (approximately one month ago) Increased appetite - now asks for food frequently, eats immediately upon waking Previously disinterested in food, now food-seeking behavior Possible increased water consumption (difficult to assess due to snow eating) No increased urination, vomiting, diarrhea, or blood in stool Weight loss trend: 115-116 lbs previously, 113-114 lbs today Recent onset right eye discharge Increased shedding in patches
Abnormal PE/Chem/CBC/UA Results: Slightly enlarged right submandibular LN, prescapular and left submandibular normal size but firm. Normal popliteal. Oral mass. USG 1.007 pH 7.5 remainder of UA - NSF Thoracic rads NSF

ULTRASONOGRAPHIC EXAMINATION OF THE ABDOMEN

Urinary System

The urinary bladder is small with a normal thickness and smooth appearance of the wall. Normal anechoic urine with no sediment or uroliths evident.

Normal appearance of the trigone area, proximal urethra, and iliac blood vessels.

Normal appearance and size of the iliac lymph nodes. Ureters not visualized, which can be considered a normal finding.

Normal renal size (left measured 7.0 cm, right measured 7.2 cm), architecture, echogenic appearance, cortico-medullary differentiation, which maintains a 1:3 cortex to medulla ratio, pelvis, and capsule. No infarcts, mineralization or renoliths evident.

Adrenal Glands

Normal shape, echogenic appearance, size, position, and appearance of the visible peri-adrenal vasculature. Left adrenal gland measured 0.59 cm and 0.67 cm in width. The right adrenal gland measured 0.65 cm and 0.59 cm in width.

Spleen

Normal size and echogenic appearance. Smooth homogenous parenchyma and regular curvilinear capsule. Normal volume of the splenic vasculature without any overt congestion or thrombosis evident. No inflammatory, neoplastic, infarction, or infiltrative changes evident. The spleen measured 2.2 cm in width.



PATIENT

Sophie Cox

SPECIES

Canine

BREED

Plott Hound Mix

SEX

Spayed female

AGE

9 years

WEIGHT

114 lbs

INTERPRETED BY

Remo Lobetti, BVSc,
MMedVet (Med),
PhD, Dipl. ECVIM

IMAGING PERFORMED BY

Brian Klug

HOSPITAL NAME

Sondel Family VC

REFERRING VET

Dr. Mortensen

INVOICE

69552

DATE

12/23/25

Liver

Normal size, echogenic appearance, portal markings, and regular curvilinear capsule. No nodules or masses evident. Normal appearance of the hepatic and portal vasculature.

Gallbladder

The gallbladder is full containing normal anechoic bile. Normal thickness and echogenic appearance of the wall. Normal size and appearance of the cystic and common bile duct.

Gastrointestinal

Normal appearance of the stomach, duodenum, small intestine, ileo-cecal junction, and colon with no loss of layering, 1:3 muscularis to mucosa ratio, normal wall thickness and peristaltic activity, and no distension of the lumen. The duodenum measured 0.55 cm, small intestine measured up to 0.38 cm.

Pancreas

The visible sections of the pancreas are of normal size and echogenic appearance with a regular capsule. Normal echogenic appearance of the mesentery and fat surrounding the pancreas.

Free Abdomen

Normal mesenteric lymph nodes.

No ascites evident.

ULTRASONOGRAPHIC FINDINGS

- Normal ultrasound examination of the abdomen.

INTERPRETATION OF THE FINDINGS & FURTHER RECOMMENDATIONS

On this ultrasound there is no obvious evidence of metastatic disease.



PATIENT

Sophie Cox

SPECIES

Canine

BREED

Plott Hound Mix

SEX

Spayed female

AGE

9 years

WEIGHT

114 lbs

INTERPRETED BY

Remo Lobetti, BVSc,
MMedVet (Med),
PhD, Dipl. ECVIM

IMAGING PERFORMED BY

Brian Klug

HOSPITAL NAME

Sondel Family VC

REFERRING VET

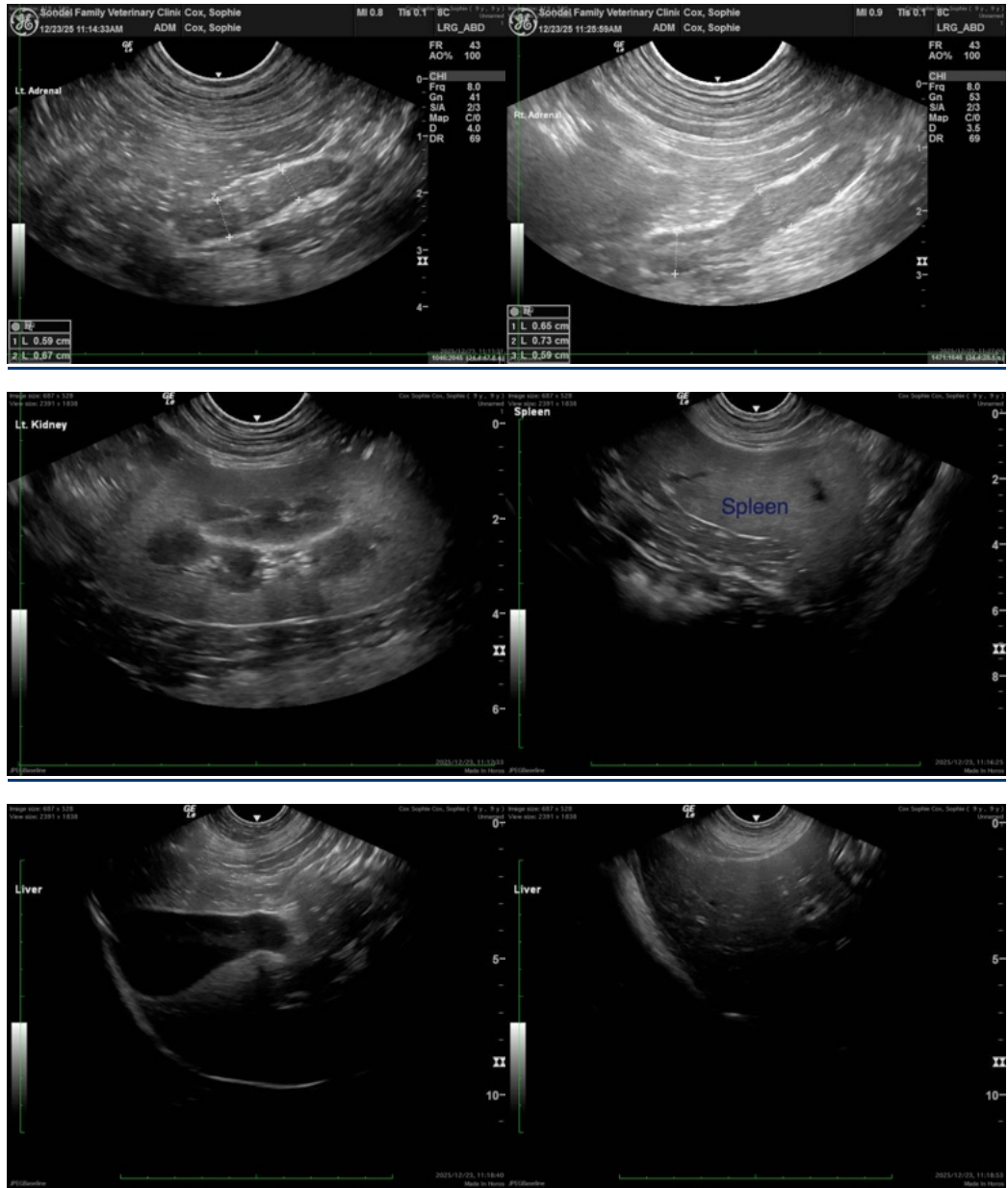
Dr. Mortensen

INVOICE

69552

DATE

12/23/25





PATIENT

Sophie Cox

SPECIES

Canine

BREED

Plott Hound Mix

SEX

Spayed female

AGE

9 years

WEIGHT

114 lbs

INTERPRETED BY

Remo Lobetti, BVSc,
MMedVet (Med),
PhD, Dipl. ECVIM

IMAGING PERFORMED BY

Brian Klug

HOSPITAL NAME

Sondel Family VC

REFERRING VET

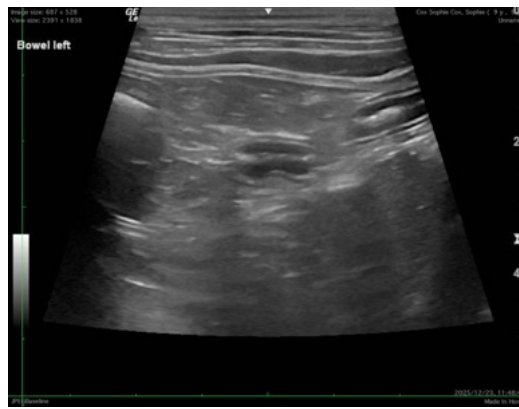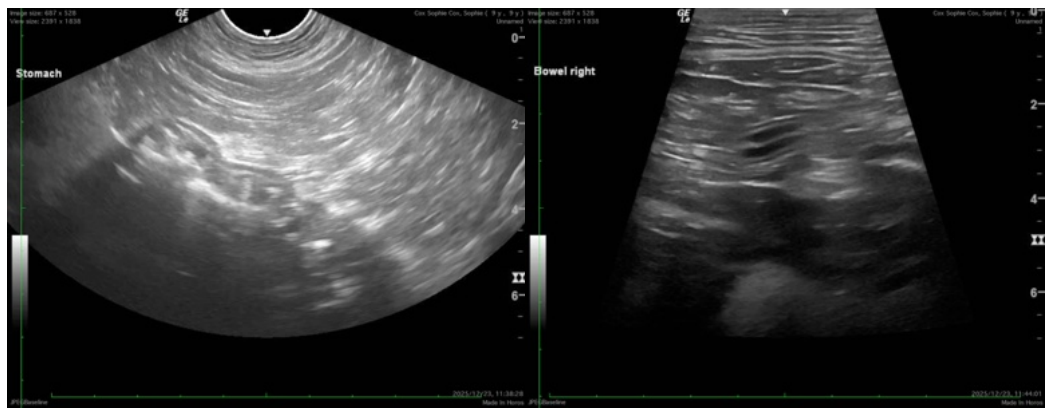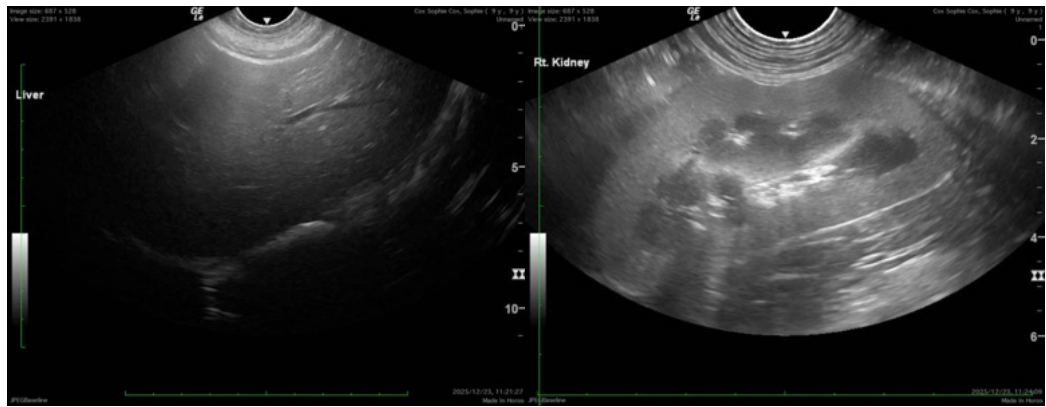
Dr. Mortensen

INVOICE

69552

DATE

12/23/25



The information and recommendations provided are based on the images presented by the referring veterinarian/sonographer. No evaluation can be communicated regarding pathology that was not visible in the image/video clips provided.

Thank you for this referral. If the clinical or image interpretation does not parallel your findings or if I can be of any further assistance please contact me.

Remo Lobetti, BVSc, MMedVet (Med), PhD, Dipl. ECVIM (Internal Medicine)

info@sonopath.com