



PATIENT

Mindi Smith

SPECIES

Canine

BREED

Miniature Pinscher

SEX

Spayed female

AGE

13 years

WEIGHT

9 lbs

INTERPRETED BY

Remo Lobetti, BVSc,
MMedVet (Med),
PhD, Dipl. ECVIM

IMAGING PERFORMED BY

Dr. Cathleen
Whitcraft

HOSPITAL NAME

Craig Road AH

REFERRING VET

Dr. Whitcraft

INVOICE

69553

DATE

12/23/25

PRESENTING CLINICAL SIGNS

History: Rechecking ultrasound after taking pet off ursodiol. Pet has Cushing's. Pet doing well clinically.

ULTRASONOGRAPHIC EXAMINATION OF THE ABDOMEN

Urinary System

The urinary bladder is small with a normal thickness and smooth appearance of the wall. Normal anechoic urine with no sediment or uroliths evident.

Normal appearance of the trigone area, proximal urethra, and iliac blood vessels.

Normal appearance and size of the iliac lymph nodes. Ureters not visualized, which can be considered a normal finding.

Normal renal size (left measured 3.6 cm, right measured 4.3 cm), architecture, echogenic appearance, cortico-medullary differentiation, which maintains a 1:3 cortex to medulla ratio, pelvis, and capsule. No infarcts, mineralization or renoliths evident.

Adrenal Glands

The adrenal glands are bilaterally enlarged with a hypoechogenic appearance, but maintained a normal shape, position and appearance of the visible peri-adrenal vasculature. The left adrenal gland measured 0.76 cm and 0.75 cm in width. The right adrenal gland measured 0.6 cm and 0.48 cm in width.

Spleen

Normal size and echogenic appearance. Smooth homogenous parenchyma and regular curvilinear capsule. Normal volume of the splenic vasculature without any overt congestion or thrombosis evident. No inflammatory, neoplastic, infarction, or infiltrative changes evident. The spleen measured 1.0 cm in width.

Liver

Normal size with a diffuse increased echogenic and coarse appearance, normal portal markings, and regular curvilinear capsule. A focal cyst was noted in the left lobe measuring 1.0 x 2.0 cm in size. No nodules or masses evident. Normal appearance of the hepatic and portal vasculature.

Gallbladder

The gallbladder is full containing a moderate amount of non-adhered, hyperechogenic sediment. Normal thickness and echogenic appearance of the wall. Normal size and appearance of the cystic and common bile duct.



PATIENT

Mindi Smith

SPECIES

Canine

BREED

Miniature Pinscher

SEX

Spayed female

AGE

13 years

WEIGHT

9 lbs

INTERPRETED BY

Remo Lobetti, BVSc,
MMedVet (Med),
PhD, Dipl. ECVIM

IMAGING PERFORMED BY

Dr. Cathleen
Whitcraft

HOSPITAL NAME

Craig Road AH

REFERRING VET

Dr. Whitcraft

INVOICE

69553

DATE

12/23/25

Gastrointestinal

Normal appearance of the stomach, duodenum, small intestine, ileo-cecal junction, and colon with no loss of layering, 1:3 muscularis to mucosa ratio, normal wall thickness and peristaltic activity, and no distension of the lumen.

Pancreas

The visible sections of the pancreas are of normal size and echogenic appearance with a regular capsule. Normal echogenic appearance of the mesentery and fat surrounding the pancreas.

Free Abdomen

Normal mesenteric lymph nodes.

No ascites evident.

ULTRASONOGRAPHIC FINDINGS

- Bilateral adrenomegaly.
- Hepatopathy.
- Hepatic cyst.
- Gallbladder sediment.

INTERPRETATION OF THE FINDINGS & FURTHER RECOMMENDATIONS

The appearance of the adrenal glands is consistent with a diagnosis of Cushing's disease.

The two most likely etiologies for the hepatopathy would be age related reactive hyperplasia and secondary to the Cushing's disease.

Both the hepatic cyst and the gallbladder sediment can be considered incidental findings. However, monitoring of the gallbladder for possible development of a mucocele would be recommended.

At this point further assessment is not indicated.



PATIENT

Mindi Smith

SPECIES

Canine

BREED

Miniature Pinscher

SEX

Spayed female

AGE

13 years

WEIGHT

9 lbs

INTERPRETED BY

Remo Lobetti, BVSc,
MMedVet (Med),
PhD, Dipl. ECVIM

IMAGING PERFORMED BY

Dr. Cathleen
Whitcraft

HOSPITAL NAME

Craig Road AH

REFERRING VET

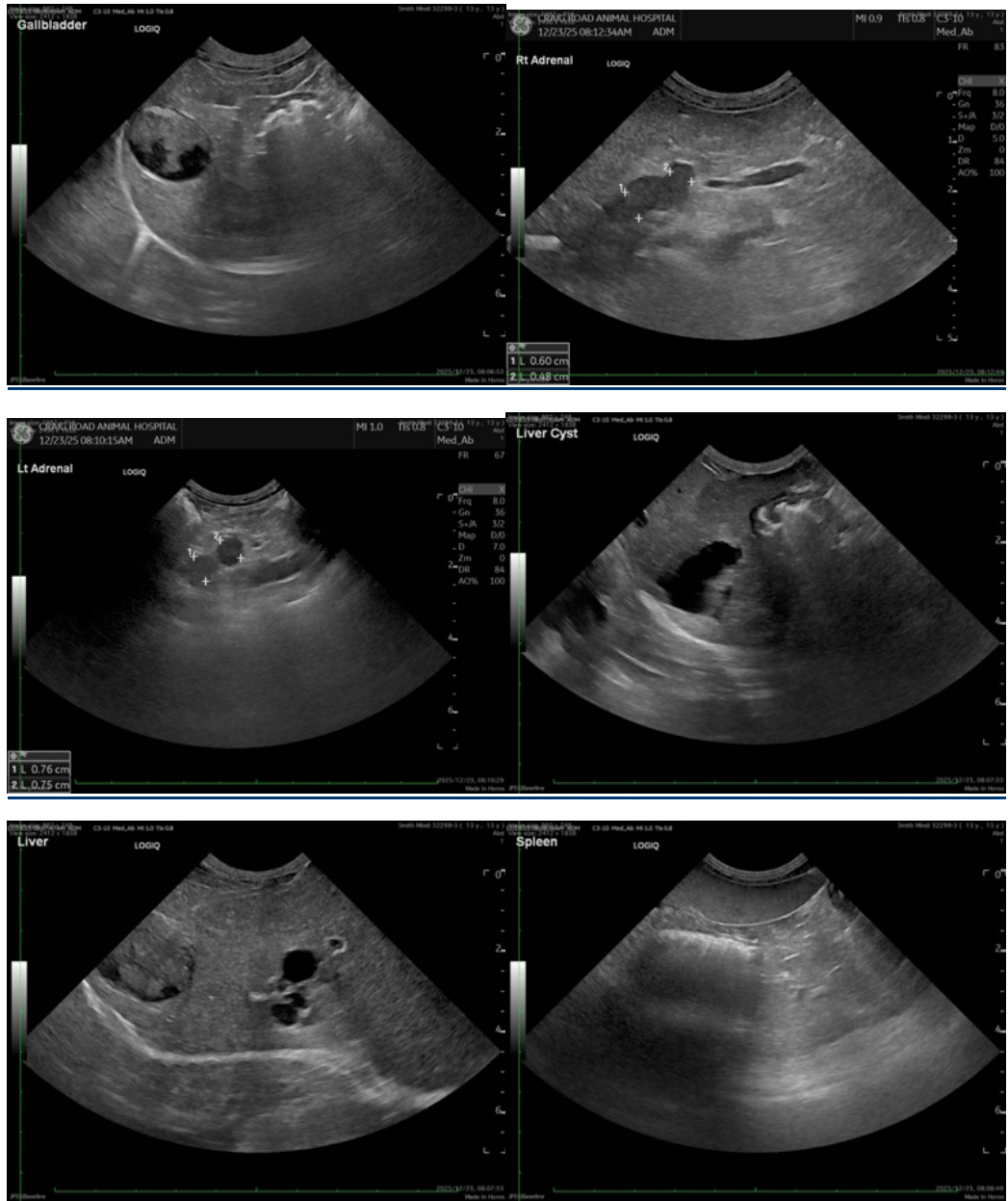
Dr. Whitcraft

INVOICE

69553

DATE

12/23/25





PATIENT

Mindi Smith

SPECIES

Canine

BREED

Miniature Pinscher

SEX

Spayed female

AGE

13 years

WEIGHT

9 lbs

INTERPRETED BY

Remo Lobetti, BVSc,
MMedVet (Med),
PhD, Dipl. ECVIM

IMAGING PERFORMED BY

Dr. Cathleen
Whitcraft

HOSPITAL NAME

Craig Road AH

REFERRING VET

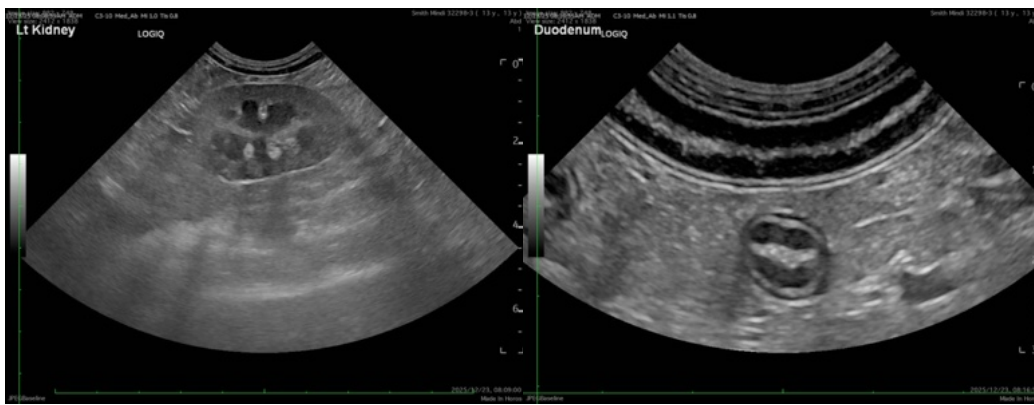
Dr. Whitcraft

INVOICE

69553

DATE

12/23/25



The information and recommendations provided are based on the images presented by the referring veterinarian/sonographer. No evaluation can be communicated regarding pathology that was not visible in the image/video clips provided.

Thank you for this referral. If the clinical or image interpretation does not parallel your findings or if I can be of any further assistance please contact me.

Remo Lobetti, BVSc, MMedVet (Med), PhD, Dipl. ECVIM (Internal Medicine)

info@sonopath.com