



## PATIENT

Jack Fournier

## SPECIES

Canine

## BREED

Labrador Retriever Mix

## SEX

Neutered male

## AGE

8 years

## WEIGHT

85 lbs

## INTERPRETED BY

Remo Lobetti, BVSc,  
MMedVet (Med),  
PhD, Dipl. ECVIM

## IMAGING PERFORMED BY

Grace Jayne, CVT

## HOSPITAL NAME

Ark AH

## REFERRING VET

Dr. Dingle

## INVOICE

69555

## DATE

12/23/25

## PRESENTING CLINICAL SIGNS

History: History from 12/22 :Presented by Stephanie. Reports it has been a month where Jack has been less enthused with eating. Current diet is currently whatever he wants. Mixture of Merrick and Pedigree kibbles and bits. Has been low energy, but not lethargic. Also has been more anxious. Reduced water consumption. Is continuing to urinate in the house, which has always been an issue, but had started to defecate in the house 1.5 weeks ago. The stools are well formed. Saturday he vomited a bit of his kibble once. This morning he dry heaved after eating more than he usually does. Vetoryl 30 mg BID  
Abnormal PE/Chem/CBC/UA Results: Cardiac/Circulatory: No murmur ausculted, irregular rhythm with dropped beats - with synchronous pulses Gastroenterology: Pot-bellied, non-painful Integumentary: chronic alopecic areas - dorsal, proximal tail ALT 166 ALP 1,851 Amylase 489 Eosinophils 0.05 Lymphocytes 0.77

## ULTRASONOGRAPHIC EXAMINATION OF THE ABDOMEN

### *Urinary System*

The urinary bladder is full with a normal thickness and smooth appearance of the wall. Normal anechoic urine with no sediment or uroliths evident.

Normal appearance of the trigone area, proximal urethra, and iliac blood vessels.

Normal appearance and size of the iliac lymph nodes. Ureters not visualized, which can be considered a normal finding.

Normal renal size (left measured 7.6 cm, right measured 8.0 cm), architecture, echogenic appearance, cortico-medullary differentiation, which maintains a 1:3 cortex to medulla ratio, pelvis, and capsule. No infarcts, mineralization or renoliths evident.

### *Adrenal Glands*

The adrenal glands are not clearly visualized, but appear to be of normal shape, echogenic appearance and size.

### *Spleen*

Normal size and echogenic appearance. Smooth homogenous parenchyma and regular curvilinear capsule. Normal volume of the splenic vasculature without any overt congestion or thrombosis evident. No inflammatory, neoplastic, infarction, or infiltrative changes evident. The spleen measured 2.5 cm in width.

### *Liver*

Normal size, echogenic appearance, portal markings, and regular curvilinear capsule. No nodules or masses evident. Normal appearance of the hepatic and portal vasculature.



## PATIENT

Jack Fournier

## SPECIES

Canine

## BREED

Labrador Retriever Mix

## SEX

Neutered male

## AGE

8 years

## WEIGHT

85 lbs

## INTERPRETED BY

Remo Lobetti, BVSc,  
MMedVet (Med),  
PhD, Dipl. ECVIM

## IMAGING PERFORMED BY

Grace Jayne, CVT

## HOSPITAL NAME

Ark AH

## REFERRING VET

Dr. Dingle

## INVOICE

69555

## DATE

12/23/25

## ***Gallbladder***

The gallbladder is full containing normal anechoic bile. Normal thickness and echogenic appearance of the wall. Normal size and appearance of the cystic and common bile duct.

## ***Gastrointestinal***

Normal appearance of the stomach, duodenum, small intestine, ileo-cecal junction, and colon with no loss of layering, 1:3 muscularis to mucosa ratio, normal wall thickness and peristaltic activity, and no distension of the lumen.

## ***Pancreas***

The visible sections of the pancreas are of normal size and echogenic appearance with a regular capsule. Normal echogenic appearance of the mesentery and fat surrounding the pancreas.

## ***Free Abdomen***

Normal mesenteric lymph nodes.

No ascites evident.

## **ULTRASONOGRAPHIC FINDINGS**

- Normal ultrasound examination of the abdomen.

## **INTERPRETATION OF THE FINDINGS & FURTHER RECOMMENDATIONS**

On this ultrasound there is no obvious etiology for the presenting clinical signs.

Although the elevated ALP activity is most likely secondary to the Cushing's disease, an underlying hepatopathy such as reactive hyperplasia, emerging nodular hyperplasia, and vacuolar should still be considered.

Hepatitis and infiltrative neoplasia would be highly unlikely differential diagnosis.

Further assessment would be echocardiography, ACTH stimulation test and possibly FNA cytology of the liver.

Further specific therapy would be dependent on an etiological diagnosis.



**PATIENT**

Jack Fournier

**SPECIES**

Canine

**BREED**

Labrador Retriever Mix

**SEX**

Neutered male

**AGE**

8 years

**WEIGHT**

85 lbs

**INTERPRETED BY**

Remo Lobetti, BVSc,  
MMedVet (Med),  
PhD, Dipl. ECVIM

**IMAGING PERFORMED BY**

Grace Jayne, CVT

**HOSPITAL NAME**

Ark AH

**REFERRING VET**

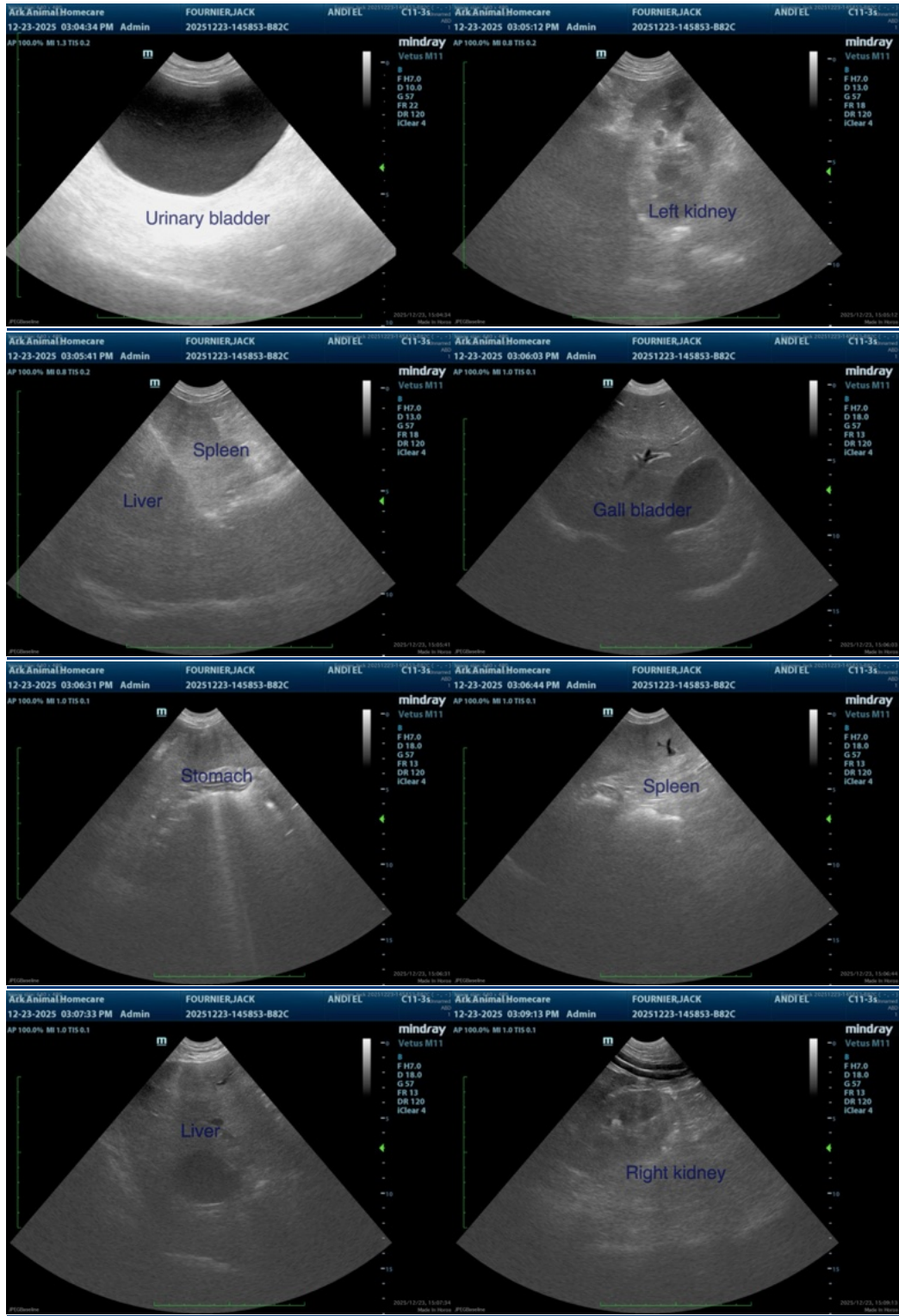
Dr. Dingle

**INVOICE**

69555

**DATE**

12/23/25



The information and recommendations provided are based on the images presented by the



## PATIENT

Jack Fournier

## SPECIES

Canine

## BREED

Labrador Retriever Mix

## SEX

Neutered male

## AGE

8 years

## WEIGHT

85 lbs

## INTERPRETED BY

Remo Lobetti, BVSc,  
MMedVet (Med),  
PhD, Dipl. ECVIM

## IMAGING PERFORMED BY

Grace Jayne, CVT

## HOSPITAL NAME

Ark AH

## REFERRING VET

Dr. Dingle

## INVOICE

69555

## DATE

12/23/25

referring veterinarian/sonographer. No evaluation can be communicated regarding pathology that was not visible in the image/video clips provided.

Thank you for this referral. If the clinical or image interpretation does not parallel your findings or if I can be of any further assistance please contact me.

Remo Lobetti, BVSc, MMedVet (Med), PhD, Dipl. ECVIM (Internal Medicine)

[info@sonopath.com](mailto:info@sonopath.com)