



## PATIENT

Tractor Seagle

## SPECIES

Canine

## BREED

Golden Retriever

## SEX

Neutered male

## AGE

10 years

## WEIGHT

95.2 lbs

## INTERPRETED BY

Remo Lobetti, BVSc,  
MMedVet (Med),  
PhD, Dipl. ECVIM

## IMAGING PERFORMED BY

Dr. Ashley Whitesell

## HOSPITAL NAME

Dickson AC

## REFERRING VET

Dr. Whitesell

## INVOICE

69533

## DATE

12/22/25

## PRESENTING CLINICAL SIGNS

History: Presented for vomiting and not being able to keep food or water down since Friday. Pinna and face were swollen but facial swelling resolved with benadryl.

Abnormal PE/Chem/CBC/UA Results: Urine dark in color- UA USG >1050, bilirubin 2+ urobilinogen 2+ Platelets 70K, RBC normal at 42.6% chemistry panel normal radiographs- on V/D area around head of spleen suspicious for mass effect- see attachments

## ULTRASONOGRAPHIC EXAMINATION OF THE ABDOMEN

### *Urinary System*

The urinary bladder is small with a normal thickness and smooth appearance of the wall. Normal anechoic urine with no sediment or uroliths evident.

Normal appearance of the trigone area, proximal urethra, and iliac blood vessels.

Normal appearance and size of the iliac lymph nodes. Ureters not visualized, which can be considered a normal finding.

Normal renal size (left measured 7.7 cm, right measured 7.5 cm), architecture, echogenic appearance, cortico-medullary differentiation, which maintains a 1:3 cortex to medulla ratio, pelvis, and capsule. No infarcts, mineralization or renoliths evident. Normal color flow pattern is evident in both kidneys.

The prostate is small and hypoechogenic.

### *Adrenal Glands*

Normal shape, echogenic appearance, size, position, and appearance of the visible peri-adrenal vasculature. Left adrenal gland measured 0.52 cm and 0.6 cm in width. The right adrenal gland measured 0.98 cm and 0.9 cm in width.

### *Spleen*

Normal size and echogenic appearance. Smooth homogenous parenchyma and regular curvilinear capsule. Normal volume of the splenic vasculature without any overt congestion or thrombosis evident. No inflammatory, neoplastic, infarction, or infiltrative changes evident. The spleen measured 2.9 cm in width.

### *Liver*

Normal size, echogenic appearance, portal markings, and regular curvilinear capsule. No nodules or masses evident. Normal appearance of the hepatic and portal vasculature.



## PATIENT

Tractor Seagle

## SPECIES

Canine

## BREED

Golden Retriever

## SEX

Neutered male

## AGE

10 years

## WEIGHT

95.2 lbs

## INTERPRETED BY

Remo Lobetti, BVSc,  
MMedVet (Med),  
PhD, Dipl. ECVIM

## IMAGING PERFORMED BY

Dr. Ashley Whitesell

## HOSPITAL NAME

Dickson AC

## REFERRING VET

Dr. Whitesell

## INVOICE

69533

## DATE

12/22/25

## ***Gallbladder***

The gallbladder is not visualized.

## ***Gastrointestinal***

Normal appearance of the stomach, duodenum, small intestine, ileo-cecal junction, and colon with no loss of layering, 1:3 muscularis to mucosa ratio, normal wall thickness and peristaltic activity, and no distension of the lumen.

## ***Pancreas***

The visible sections of the pancreas are of normal size and echogenic appearance with a regular capsule. Normal echogenic appearance of the mesentery and fat surrounding the pancreas.

## ***Free Abdomen***

Normal mesenteric lymph nodes.

No ascites evident.

## ***Thorax***

Normal appearance of the heart. No pericardial or pleural effusion evident.

## **ULTRASONOGRAPHIC FINDINGS**

- Normal ultrasound examination of the abdomen.

## **INTERPRETATION OF THE FINDINGS & FURTHER RECOMMENDATIONS**

No specific therapy is recommended.



**PATIENT**

Tractor Seagle

**SPECIES**

Canine

**BREED**

Golden Retriever

**SEX**

Neutered male

**AGE**

10 years

**WEIGHT**

95.2 lbs

**INTERPRETED BY**

Remo Lobetti, BVSc,  
MMedVet (Med),  
PhD, Dipl. ECVIM

**IMAGING PERFORMED BY**

Dr. Ashley Whitesell

**HOSPITAL NAME**

Dickson AC

**REFERRING VET**

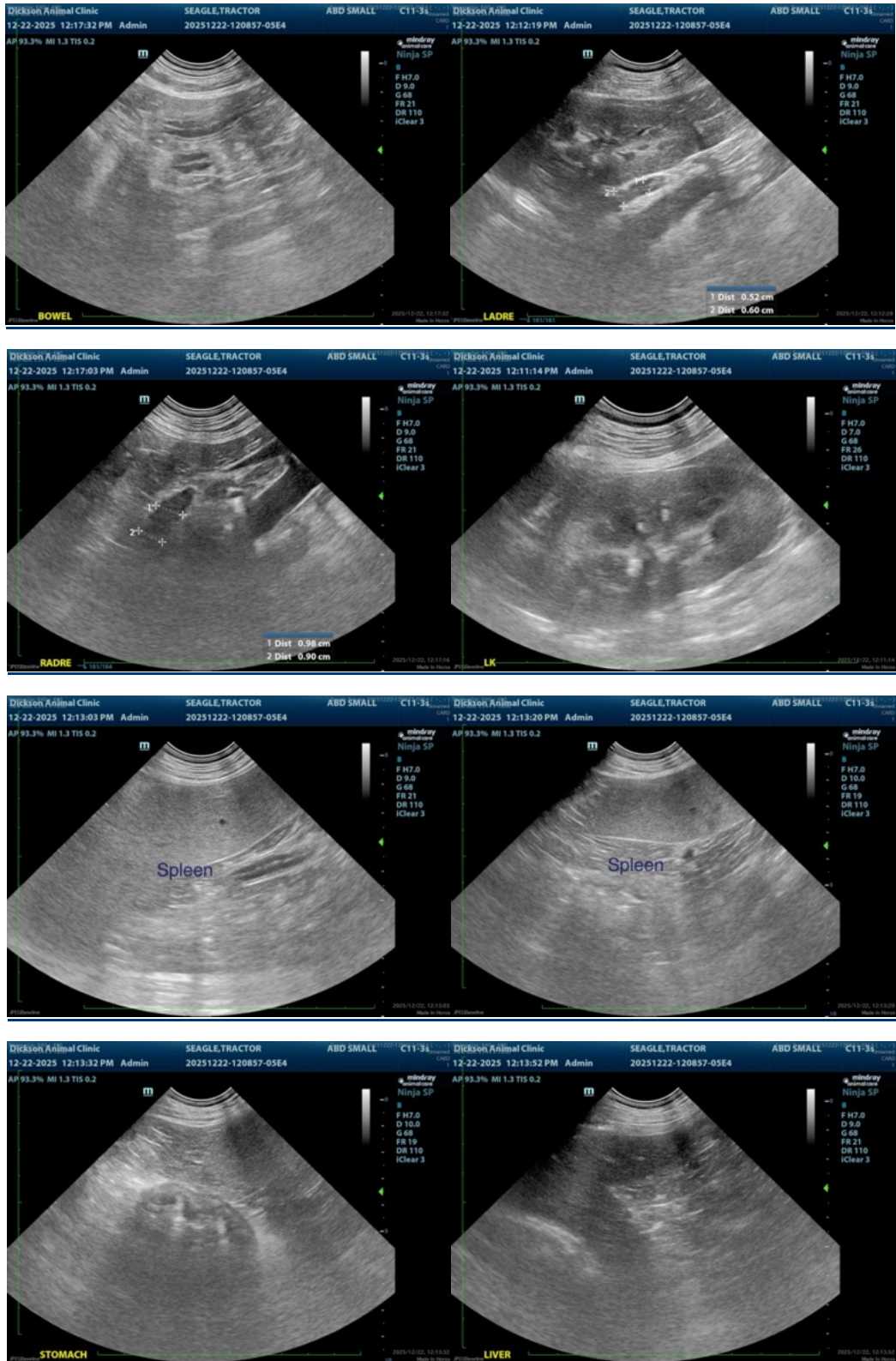
Dr. Whitesell

**INVOICE**

69533

**DATE**

12/22/25





## PATIENT

Tractor Seagle

## SPECIES

Canine

## BREED

Golden Retriever

## SEX

Neutered male

## AGE

10 years

## WEIGHT

95.2 lbs

## INTERPRETED BY

Remo Lobetti, BVSc,  
MMedVet (Med),  
PhD, Dipl. ECVIM

## IMAGING PERFORMED BY

Dr. Ashley Whitesell

## HOSPITAL NAME

Dickson AC

## REFERRING VET

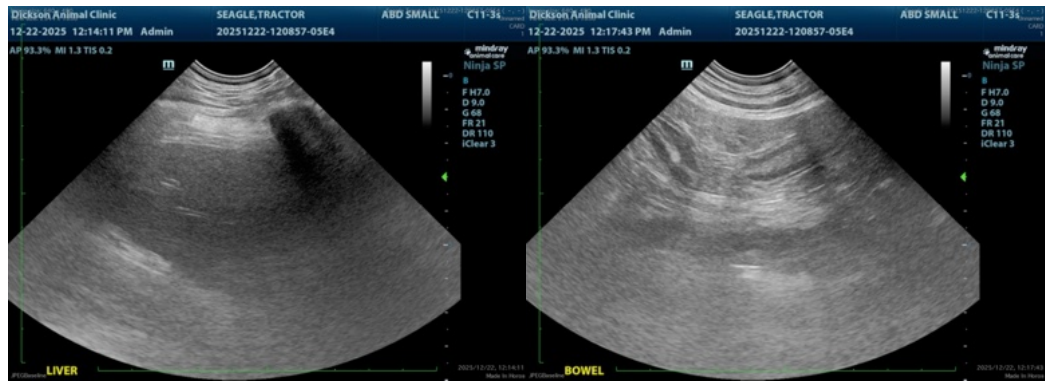
Dr. Whitesell

## INVOICE

69533

## DATE

12/22/25



The information and recommendations provided are based on the images presented by the referring veterinarian/sonographer. No evaluation can be communicated regarding pathology that was not visible in the image/video clips provided.

Thank you for this referral. If the clinical or image interpretation does not parallel your findings or if I can be of any further assistance please contact me.

Remo Lobetti, BVSc, MMedVet (Med), PhD, Dipl. ECVIM (Internal Medicine)

[info@sonopath.com](mailto:info@sonopath.com)