

PATIENT

Poppy Proctor

SPECIES

Canine

BREED

Golden Doodle

SEX

Spayed Female

AGE

3 Years

WEIGHT

11.2 kg

INTERPRETED BY

Remo Lobetti, BVSc,
MMedVet (Med),
PhD, Dipl. ECVIM
(Internal Medicine)

IMAGING PERFORMED BY

Natalia Franco

HOSPITAL NAME

Eagleson VC

REFERRING VET

Dr. Mohamed Madany

INVOICE

35976

DATE

12/20/25

PRESENTING CLINICAL SIGNS

History: Presented for generalized pain/discomfort. Nonresponsive to anti-inflammatory medication. Mild decrease in appetite. Increased anxiety behavior (shaking, panting).

Abnormal PE/Chem/CBC/UA Results: CBC NSF Chem: Mild creatinine increase 132 (range: 27-124umol/L); remaining chem WNL Pancreatic lipase within normal limits.

ULTRASONOGRAPHIC EXAMINATION OF THE ABDOMEN

Urinary System

Small urinary bladder with a normal thickness and smooth appearance of the wall. Normal anechoic urine with no sediment or uroliths evident. Normal appearance of the trigone area, proximal urethra, and iliac blood vessels. Normal appearance and size of the iliac lymph nodes. Ureters not visualized, which can be considered a normal finding.

Normal renal size, architecture, echogenic appearance, cortico-medullary differentiation, which maintains a 1:3 cortex to medulla ratio, pelvis, and capsule. No infarcts, mineralization or renoliths evident. The left kidney measured 5.0 cm. The right kidney measured 4.4 cm. Normal color flow pattern was evident in both kidneys.

Adrenal Glands

The left adrenal gland was normal in shape, echogenic appearance, size, position, and appearance of the visible peri-adrenal vasculature. The left adrenal gland measured 0.44 cm and 0.33 cm in width.

The right adrenal gland was not clearly visualized, but appears to be of normal shape, echogenic appearance, and size.

Spleen

Normal size (1.8 cm in width) and echogenic appearance. Smooth homogenous parenchyma and regular curvilinear capsule. Normal volume of the splenic vasculature without any overt congestion or thrombosis evident. No inflammatory, neoplastic, infarction, or infiltrative changes evident.

Liver

Normal size, echogenic appearance, portal markings, and regular curvilinear capsule. No nodules or masses evident. Normal appearance of the hepatic and portal vasculature.

Gallbladder

Full gallbladder, containing normal anechoic bile. Normal thickness and echogenic appearance of the wall. Normal size and appearance of the cystic and common bile duct.

Gastrointestinal

Normal appearance of the stomach, duodenum, small intestine, ileo-cecal junction, and colon with no loss of layering, 1:3 muscularis to mucosa ratio, normal wall thickness and peristaltic activity, and no distension of the lumen. A small amount of gas was present within the stomach.

Pancreas



PATIENT

Poppy Proctor

SPECIES

Canine

BREED

Golden Doodle

SEX

Spayed Female

AGE

3 Years

WEIGHT

11.2 kg

INTERPRETED BY

Remo Lobetti, BVSc,
MMedVet (Med),
PhD, Dipl. ECVIM
(Internal Medicine)

IMAGING PERFORMED BY

Natalia Franco

HOSPITAL NAME

Eagleson VC

REFERRING VET

Dr. Mohamed Madany

INVOICE

35976

DATE

12/20/25

Visible sections of the pancreas are of normal size and echogenic appearance with a regular capsule. Normal echogenic appearance of the mesentery and fat surrounding the pancreas.

Free Abdomen

Normal mesenteric lymph nodes.

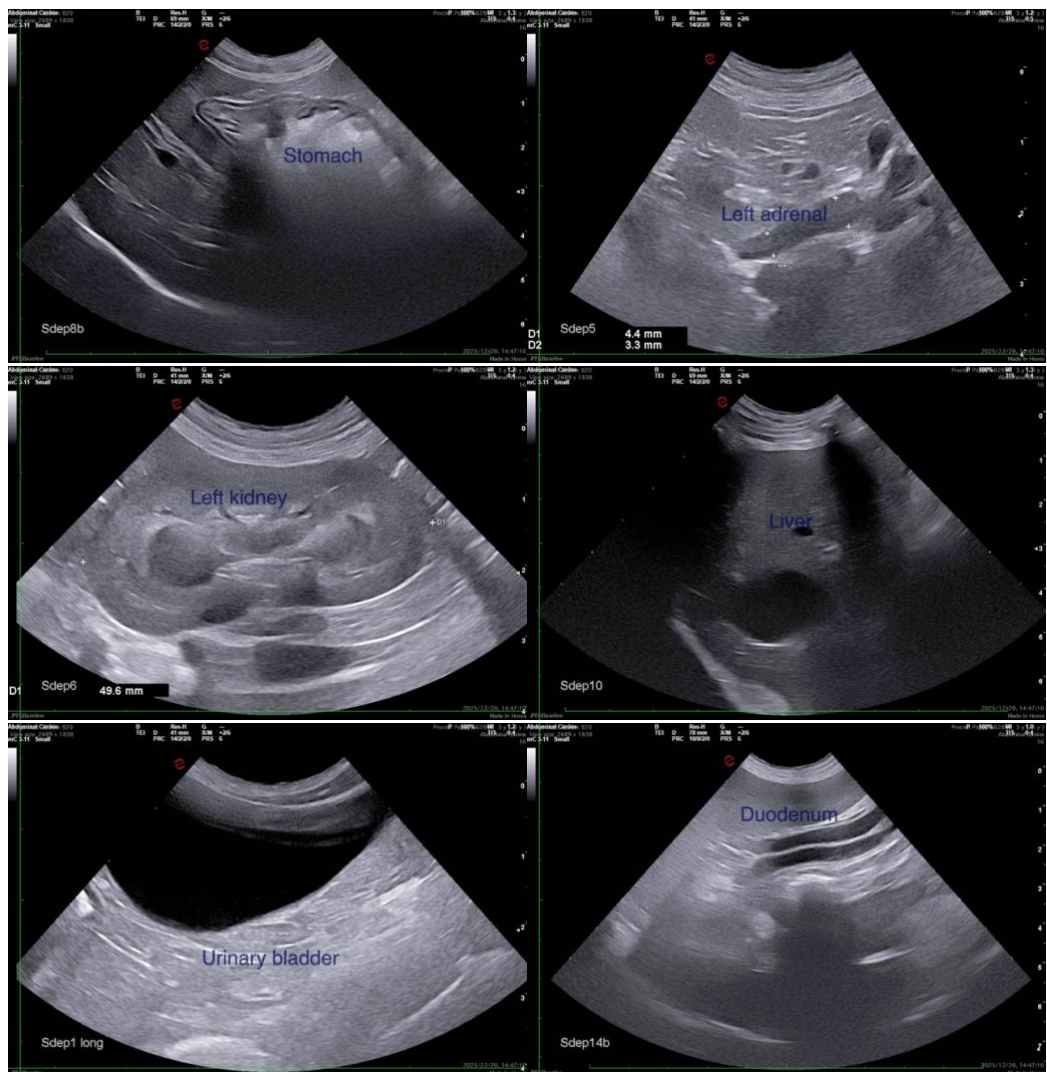
No ascites evident.

ULTRASONOGRAPHIC FINDINGS

- Normal ultrasound examination of the abdomen

INTERPRETATION OF THE FINDINGS & FURTHER RECOMMENDATIONS

On this ultrasound there is no obvious etiology for the presenting clinical signs.





PATIENT

Poppy Proctor

SPECIES

Canine

BREED

Golden Doodle

SEX

Spayed Female

AGE

3 Years

WEIGHT

11.2 kg

INTERPRETED BY

Remo Lobetti, BVSc,
MMedVet (Med),
PhD, Dipl. ECVIM
(Internal Medicine)

IMAGING PERFORMED BY

Natalia Franco

HOSPITAL NAME

Eagleson VC

REFERRING VET

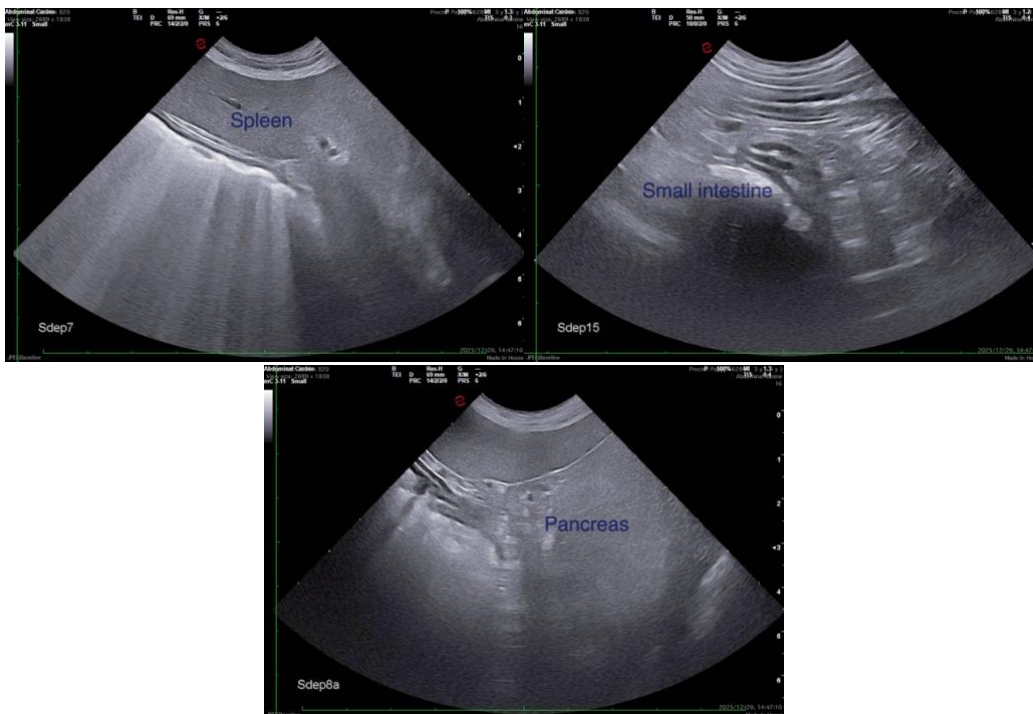
Dr. Mohamed Madany

INVOICE

35976

DATE

12/20/25



The information and recommendations provided are based on the images presented by the referring veterinarian/sonographer. No evaluation can be communicated regarding pathology that was not visible in the image/video clips provided.

Thank you for this referral. If the clinical or image interpretation does not parallel your findings or if I can be of any further assistance, please contact me.

Remo Lobetti, BVSc, MMedVet (Med), PhD, Dipl. ECVIM (Internal Medicine)

info@sonopath.com