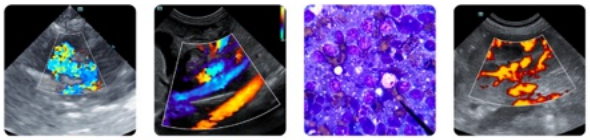

PATIENT

Jelly Bellie II Nicodemus

SPECIES

Canine

BREED

English Bulldog

SEX

Spayed Female

AGE

11 years

WEIGHT

47.1 lbs

INTERPRETED BY

Remo Lobetti, BVSc, MMedVet (Med), PhD, Dipl. ECVIM

IMAGING PERFORMED BY

Dr. Abadia

HOSPITAL NAME

Surfside Pet Hospital

REFERRING VET

Dr. Abadia

INVOICE

69454

DATE

12/19/25

PRESENTING CLINICAL SIGNS

History: Pet had had diarrhea for the past couple of months that doesnt go away. Probiotics dont help much but metro stops it while been on it. No weight loss at this time and pet still eats and drinks wnl. Multiple diets have been performed without controlling it. Since puppy pet had a lot UTI, incontinent and was diagnosed with intramural left ectopic ureter and laser ablation performed 1/13/15 at UF. Also had a paramesonephric remnant and laser ablation perfoemd as well at same time. Pet has always had urinary issues with reocurrent UTI's throughout the years with multiple cultures and treatment in which controls it. Pet is also on DES for incontinence Multiple fecals- wnl Pet doing well with urinary issues at this time. chronic skin allegies with otitis externa.
Abnormal PE/Chem/CBC/UA Results: BW - oct 29 , 2025 - cbc- monocytes 1.257, plt- 598. chem panel- sodium- 141, na:k ratio 27, globulin 4.1 , normal thyroid and cortisol- 1.0. all other nparameters on BW are wnl. ACTH stim test performed nov 2, 2025- showed preacth- 2.5, post acth 11.4 No xrays were performed due to owner wanting to do abdominal ultrasound

ULTRASONOGRAPHIC EXAMINATION OF THE ABDOMEN

Urinary System

The urinary bladder is full with a normal thickness and smooth appearance of the wall. Normal anechoic urine with no sediment or uroliths evident.

Normal appearance of the trigone area, proximal urethra, and iliac blood vessels.

Normal appearance and size of the iliac lymph nodes. Dilated proximal ureter.

Small, irregular left kidney (2.5 cm in size) with a hypoechogenic appearance, complete loss of corticomedullary differentiation and an irregular capsule. No infarcts, mineralization or renoliths evident. The right kidney is normal in size (6.6 cm), architecture, echogenic appearance, cortico-medullary differentiation, which maintains a 1:3 cortex to medulla ratio, pelvis, and capsule. No infarcts, mineralization or renoliths evident.

Adrenal Glands

Normal shape, echogenic appearance, size, position, and appearance of the visible peri-adrenal vasculature. Left adrenal gland measured 1.86 cm in length x 0.56 cm and 0.75 cm in width. The right adrenal gland measured 2.09 cm in length x 0.74 cm and 0.72 cm in width.

Spleen

Normal size and echogenic appearance. Smooth homogenous parenchyma and regular curvilinear capsule. Normal volume of the splenic vasculature without any overt congestion or thrombosis evident. No inflammatory, neoplastic, infarction, or infiltrative changes evident. The spleen measured 1.2 cm in width.

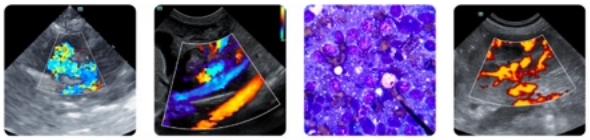

PATIENT
Jelly Bellie II Nicodemus

SPECIES
Canine

BREED
English Bulldog

SEX
Spayed Female

AGE
11 years

WEIGHT
47.1 lbs

INTERPRETED BY
Remo Lobetti, BVSc, MMedVet (Med), PhD, Dipl. ECVIM

IMAGING PERFORMED BY
Dr. Abadia

HOSPITAL NAME
Surfside Pet Hospital

REFERRING VET
Dr. Abadia

INVOICE
69454

DATE
12/19/25

Liver

Normal size, echogenic appearance, portal markings, and regular curvilinear capsule. No nodules or masses evident. Normal appearance of the hepatic and portal vasculature.

Gallbladder

The gallbladder is full containing normal anechoic bile. A small polyp measuring 0.4 cm in size. Normal thickness and echogenic appearance of the wall. Normal size and appearance of the cystic and common bile duct.

Gastrointestinal

Normal appearance of the stomach, duodenum, ileo-cecal junction, and colon with no loss of layering, 1:3 muscularis to mucosa ratio, normal wall thickness and peristaltic activity, and no distension of the lumen. The small intestine has normal thickness with no loss of layering, but with an increase in the muscularis to mucosa ratio, normal peristaltic activity and no distension of the lumen.

Pancreas

The visible sections of the pancreas are of normal size and echogenic appearance with a regular capsule. Normal echogenic appearance of the mesentery and fat surrounding the pancreas.

Free Abdomen

Normal mesenteric lymph nodes.

No ascites evident.

ULTRASONOGRAPHIC FINDINGS

- Enteropathy.
- Left nephropathy, dilated left ureter.
- Gallbladder polyp.

INTERPRETATION OF THE FINDINGS & FURTHER RECOMMENDATIONS

Etiologies for the enteropathy would be dietary hypersensitivity and inflammatory bowel disease. Exocrine pancreatic insufficiency would be a less likely differential diagnosis.

The appearance of the left kidney and dilated left ureter can be considered an incidental findings associated with the previous diagnosis of ectopic ureter.

The gallbladder polyp can be considered an incidental finding.

PATIENT

Jelly Bellie II Nicodemus

SPECIES

Canine

BREED

English Bulldog

SEX

Spayed Female

AGE

11 years

WEIGHT

47.1 lbs

INTERPRETED BY

Remo Lobetti, BVSc, MMedVet (Med), PhD, Dipl. ECVIM

IMAGING PERFORMED BY

Dr. Abadia

HOSPITAL NAME

Surfside Pet Hospital

REFERRING VET

Dr. Abadia

INVOICE

69454

DATE

12/19/25

Further assessment would be cobalamin, folate and TLI assay and endoscopy of the upper GI tract with biopsies.

Specific therapy would be dependent on an etiological diagnosis. Symptomatic management that can be considered would be feeding a novel protein/hypoallergenic diet, cobalamin supplementation and if there is still not a satisfactory improvement then a course of Prednisolone would then be indicated.

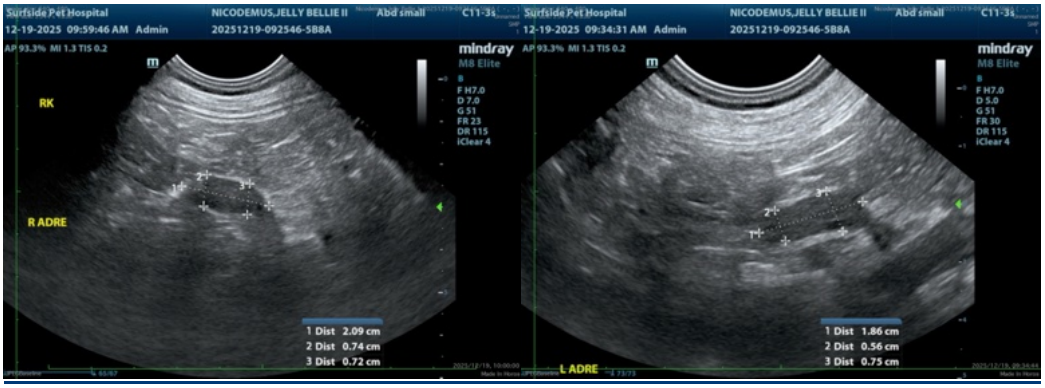

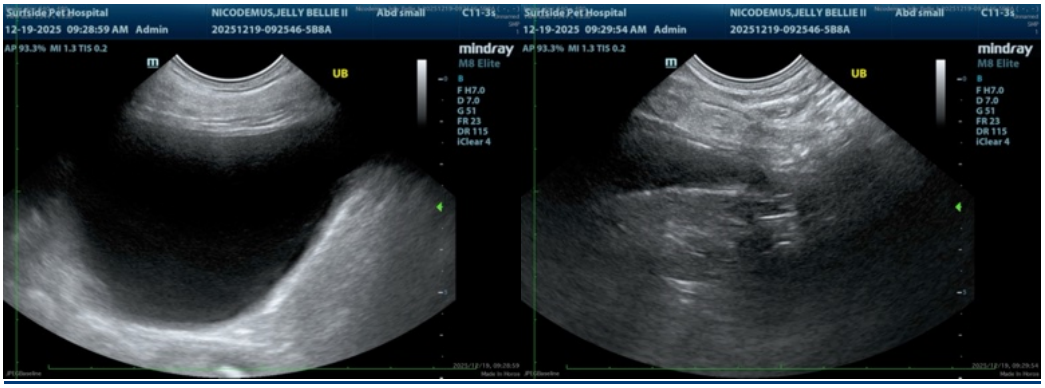

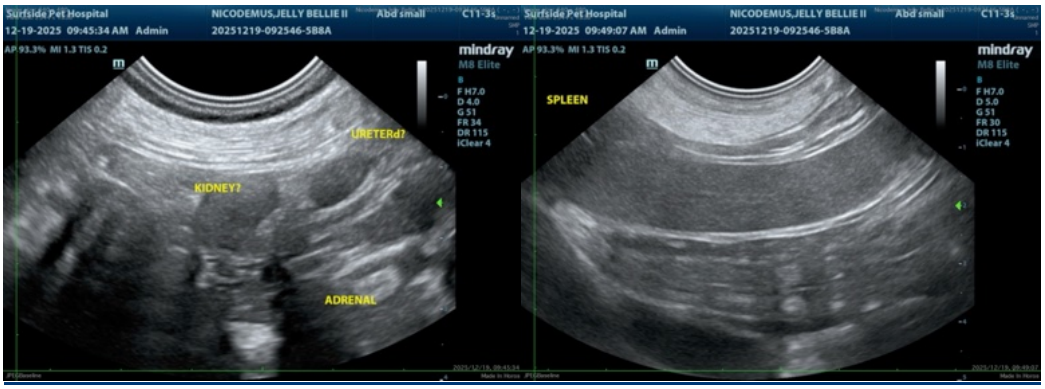

SonoPath

FOSTERING THE ART OF VETERINARY MEDICINE™

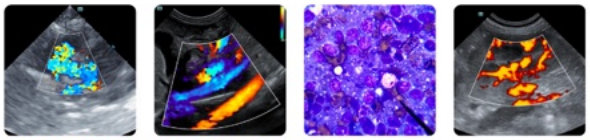

Clinical Sonography & Telecytology

Educational Teleconsultation Services™

SonoPath.com info@sonopath.com 1.800.838.4268

PATIENT

Jelly Bellie II Nicodemus

SPECIES

Canine

BREED

English Bulldog

SEX

Spayed Female

AGE

11 years

WEIGHT

47.1 lbs

INTERPRETED BY

Remo Lobetti, BVSc, MMedVet (Med), PhD, Dipl. ECVIM

IMAGING PERFORMED BY

Dr. Abadia

HOSPITAL NAME

Surfside Pet Hospital

REFERRING VET

Dr. Abadia

INVOICE

69454

DATE

12/19/25

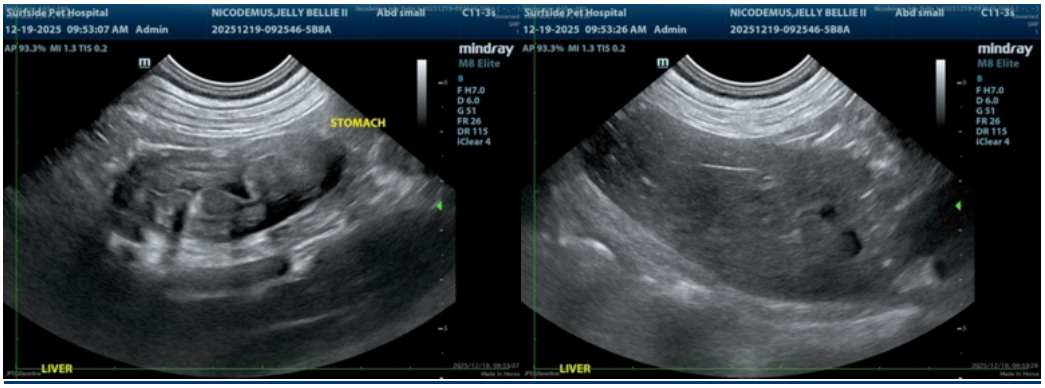

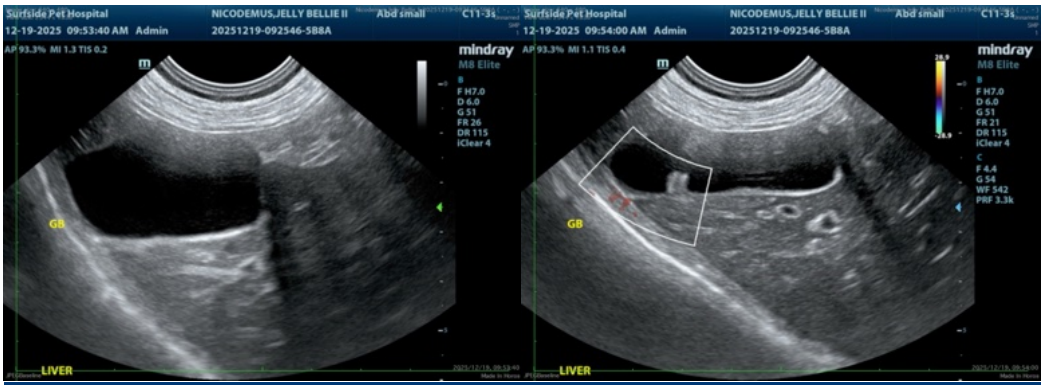

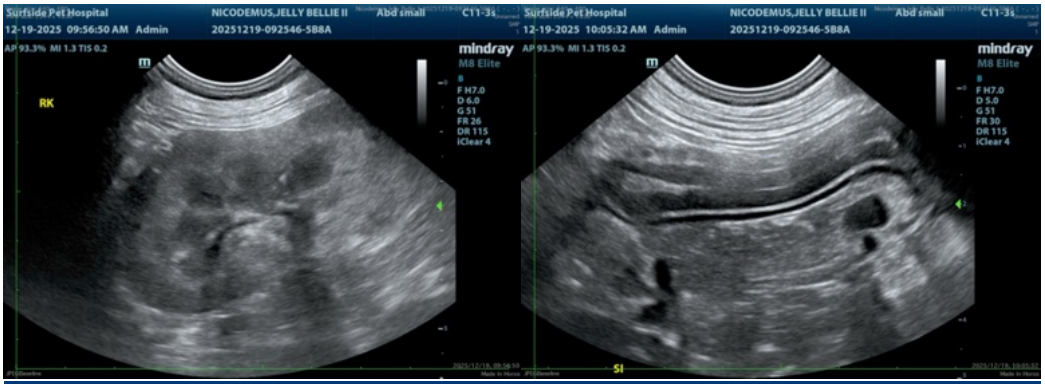

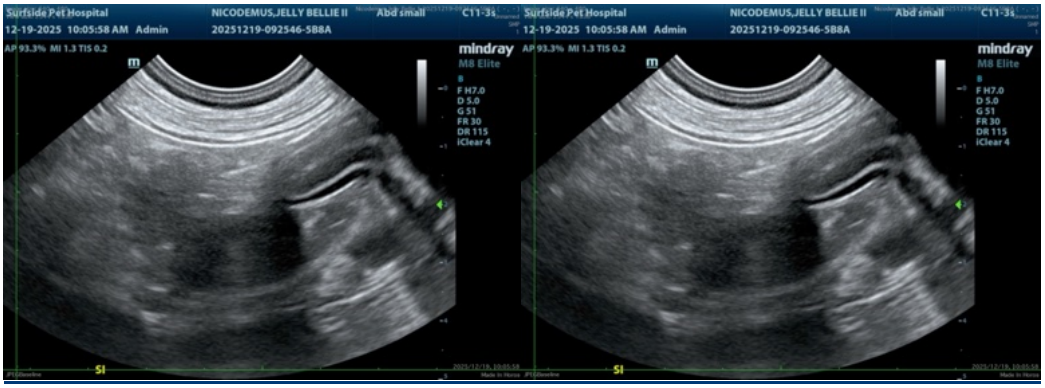

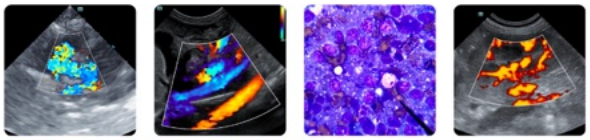

PATIENT

Jelly Bellie II Nicodemus

SPECIES

Canine

BREED

English Bulldog

SEX

Spayed Female

AGE

11 years

WEIGHT

47.1 lbs

INTERPRETED BY

Remo Lobetti, BVSc, MMedVet (Med), PhD, Dipl. ECVIM

IMAGING PERFORMED BY

Dr. Abadia

HOSPITAL NAME

Surfside Pet Hospital

REFERRING VET

Dr. Abadia

INVOICE

69454

DATE

12/19/25

The information and recommendations provided are based on the images presented by the referring veterinarian/sonographer. No evaluation can be communicated regarding pathology that was not visible in the image/video clips provided.

Thank you for this referral. If the clinical or image interpretation does not parallel your findings or if I can be of any further assistance please contact me.

Remo Lobetti, BVSc, MMedVet (Med), PhD, Dipl. ECVIM (Internal Medicine)

info@sonopath.com