



## PATIENT

Penny Groff

## SPECIES

Canine

## BREED

Basset Hound

## SEX

Spayed female

## AGE

5 years

## WEIGHT

38 lbs

## INTERPRETED BY

Remo Lobetti, BVSc,  
MMedVet (Med),  
PhD, Dipl. ECVIM

## IMAGING PERFORMED BY

Jack Reese

## HOSPITAL NAME

Willow Run VC

## REFERRING VET

Dr. Witmer

## INVOICE

69399

## DATE

12/17/25

## PRESENTING CLINICAL SIGNS

History: Patient presented for evaluation of progressive weight loss noted to have started in April 2025. Owner reports that weight loss seems to have increased over last 2 months. ~10 lb weight loss since April 2025 (47.4 lbs) to today (38 lbs). Owner reports that P acting normally at home, but is noting mild, intermittent gastrointestinal symptoms.

Abnormal PE/Chem/CBC/UA Results: Albumin 2.6 (2.7 - 3.9 g/dL) ALT 456 (18 - 121 U/L) AST 96 (16 - 55 U/L) GGT 14 (0 - 13 U/L) Trace urine protein and UPC of 0.2

## ULTRASONOGRAPHIC EXAMINATION OF THE ABDOMEN

### Urinary System

The urinary bladder is full with a normal thickness and smooth appearance of the wall. A scant amount of floating hyperechogenic sediment was noted.

Normal appearance of the trigone area, proximal urethra, and iliac blood vessels.

Normal appearance and size of the iliac lymph nodes. Ureters not visualized, which can be considered a normal finding.

Normal renal size (left measured 6.3 cm, right measured 5.5 cm), architecture, echogenic appearance, cortico-medullary differentiation, which maintains a 1:3 cortex to medulla ratio, pelvis, and capsule. No infarcts, mineralization or renoliths evident. Normal color flow pattern was noted in both kidneys.

### Adrenal Glands

Normal shape, echogenic appearance, size, position, and appearance of the visible peri-adrenal vasculature. Left adrenal gland measured 0.39 and 0.4 cm in width. The right adrenal gland measured 0.4 cm in width.

### Spleen

Normal size and echogenic appearance. Smooth homogenous parenchyma and regular curvilinear capsule. Normal volume of the splenic vasculature without any overt congestion or thrombosis evident. No inflammatory, neoplastic, infarction, or infiltrative changes evident. The spleen measured 1.4 cm in width.

### Liver

Normal size, echogenic appearance, portal markings, and regular curvilinear capsule. No nodules or masses evident. Normal appearance of the hepatic and portal vasculature.

### Gallbladder

The gallbladder is full containing normal anechoic bile. Normal thickness and echogenic appearance of the wall. Normal size and appearance of the cystic and common bile duct.



## PATIENT

Penny Groff

## SPECIES

Canine

## BREED

Basset Hound

## SEX

Spayed female

## AGE

5 years

## WEIGHT

38 lbs

## INTERPRETED BY

Remo Lobetti, BVSc,  
MMedVet (Med),  
PhD, Dipl. ECVIM

## IMAGING PERFORMED BY

Jack Reese

## HOSPITAL NAME

Willow Run VC

## REFERRING VET

Dr. Witmer

## INVOICE

69399

## DATE

12/17/25

## ***Gastrointestinal***

Normal appearance of the stomach, ileo-cecal junction, and colon with no loss of layering, 1:3 muscularis to mucosa ratio, normal wall thickness and peristaltic activity, and no distension of the lumen.

Thickening of the duodenum (up to 0.76 cm) with no loss of layering, but marked increase in the muscularis to mucosa ratio, normal peristaltic activity and no distension of the lumen.

## ***Pancreas***

The visible sections of the pancreas are of normal size and echogenic appearance with a regular capsule. Normal echogenic appearance of the mesentery and fat surrounding the pancreas.

## ***Free Abdomen***

Normal mesenteric lymph nodes.

No ascites evident.

## **ULTRASONOGRAPHIC FINDINGS**

- Enteropathy

## **INTERPRETATION OF THE FINDINGS & FURTHER RECOMMENDATIONS**

Etiologies for the enteropathy would be parasitic enteritis, dietary hypersensitivity and inflammatory bowel disease with emerging lymphoma a less likely differential diagnosis.

Further assessment would be fecal analysis, cobalamin, and folate assay and endoscopy of the upper GI tract with biopsies.

Specific therapy would be dependent on an etiological diagnosis.

Symptomatic management that can be considered would be feeding a novel protein/hypoallergenic diet, course of Fenbendazole and cobalamin supplementation and if there is still not a satisfactory improvement then a course of Prednisolone would be indicated.



## PATIENT

Penny Groff

## SPECIES

Canine

## BREED

Basset Hound

## SEX

Spayed female

## AGE

5 years

## WEIGHT

38 lbs

## INTERPRETED BY

Remo Lobetti, BVSc,  
MMedVet (Med),  
PhD, Dipl. ECVIM

## IMAGING PERFORMED BY

Jack Reese

## HOSPITAL NAME

Willow Run VC

## REFERRING VET

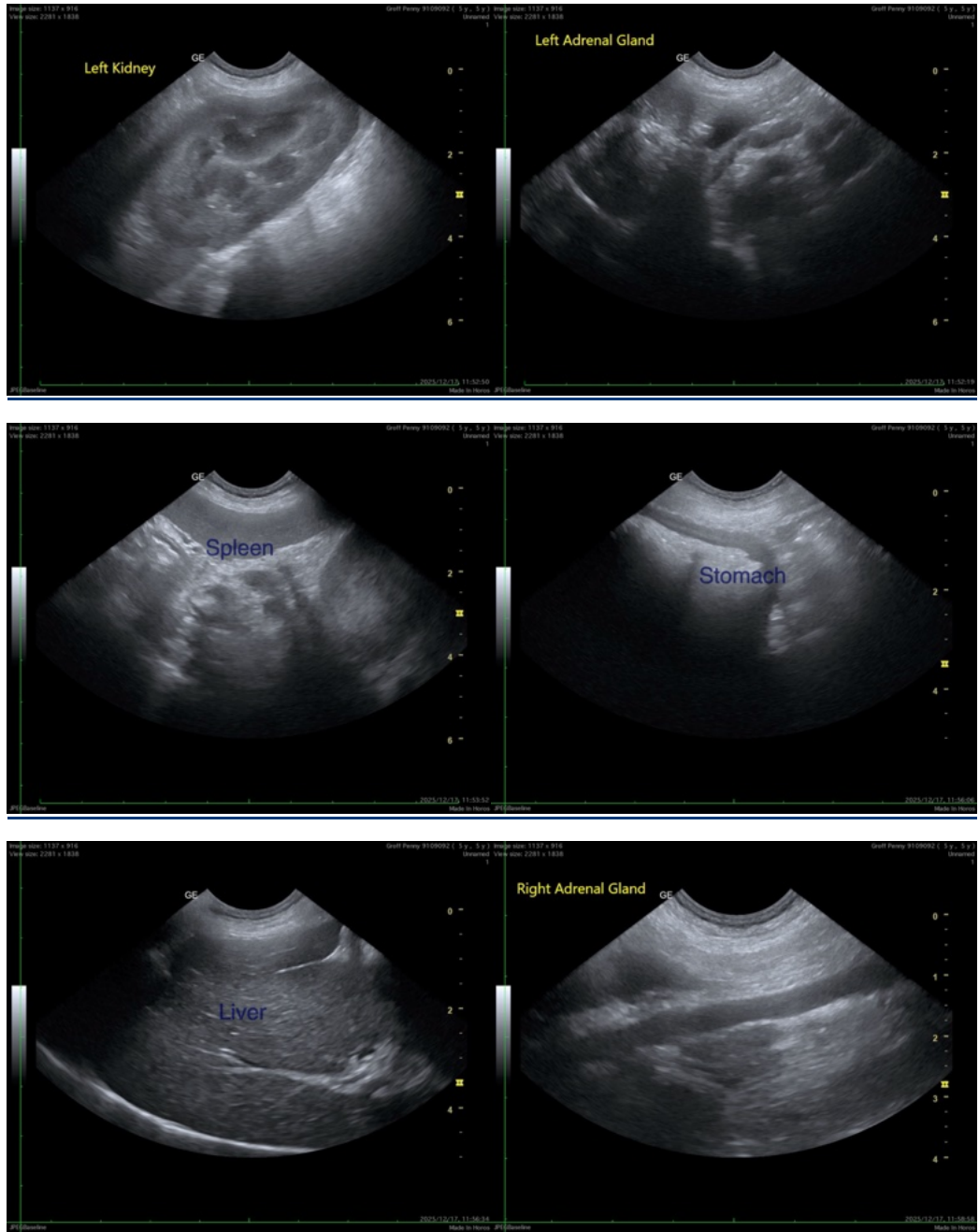
Dr. Witmer

## INVOICE

69399

## DATE

12/17/25





## PATIENT

Penny Groff

## SPECIES

Canine

## BREED

Basset Hound

## SEX

Spayed female

## AGE

5 years

## WEIGHT

38 lbs

## INTERPRETED BY

Remo Lobetti, BVSc,  
MMedVet (Med),  
PhD, Dipl. ECVIM

## IMAGING PERFORMED BY

Jack Reese

## HOSPITAL NAME

Willow Run VC

## REFERRING VET

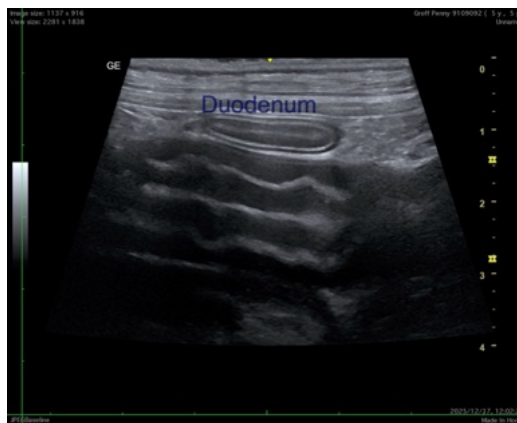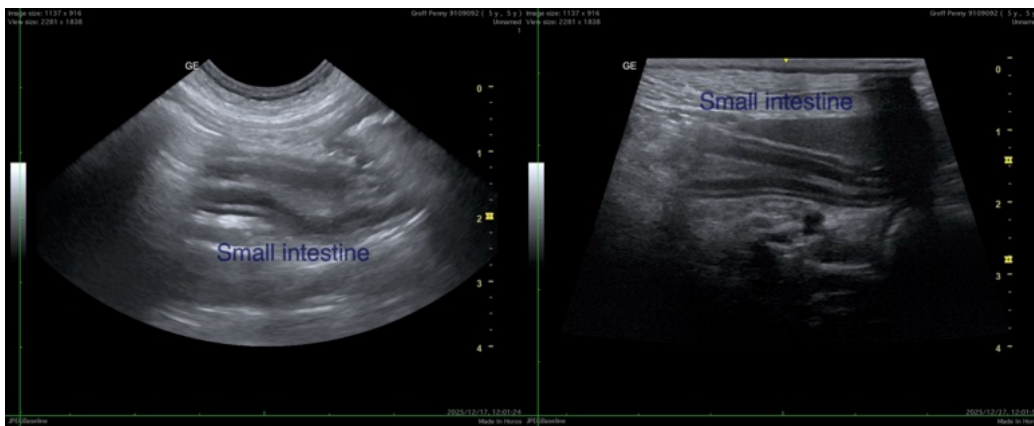Dr. Witmer

## INVOICE

69399

## DATE

12/17/25



The information and recommendations provided are based on the images presented by the referring veterinarian/sonographer. No evaluation can be communicated regarding pathology that was not visible in the image/video clips provided.

Thank you for this referral. If the clinical or image interpretation does not parallel your findings or if I can be of any further assistance please contact me.

Remo Lobetti, BVSc, MMedVet (Med), PhD, Dipl. ECVIM (Internal Medicine)

[info@sonopath.com](mailto:info@sonopath.com)