



PATIENT

Ziggy Marcano

SPECIES

Canine

BREED

Maltese Mix

SEX

Male

AGE

13 years

WEIGHT

13.8 lbs

INTERPRETED BY

Remo Lobetti, BVSc,
MMedVet (Med),
PhD, Dipl. ECVIM

IMAGING PERFORMED BY

Dr. Giuliani

HOSPITAL NAME

The Pet Hospital of
Stratford

REFERRING VET

Dr. Giuliani

INVOICE

69342

DATE

12/16/25

PRESENTING CLINICAL SIGNS

History: Pt presented in Sept for increase drinking/urinating, bw including LDDS consistent with Cushing's. Pt has not started medications yet.

ULTRASONOGRAPHIC EXAMINATION OF THE ABDOMEN

Urinary System

The urinary bladder is full with a normal thickness and smooth appearance of the wall. Normal anechoic urine with no sediment or uroliths evident.

Normal appearance of the trigone area, proximal urethra, and iliac blood vessels.

Normal appearance and size of the iliac lymph nodes. Ureters not visualized, which can be considered a normal finding.

Normal renal size (left measured 4.3 cm, right measured 4.5 cm), architecture, echogenic appearance, cortico-medullary differentiation, which maintains a 1:3 cortex to medulla ratio, pelvis, and capsule. No infarcts, mineralization or renoliths evident. Normal color flow pattern is evident in both kidneys.

Normal size and appearance of the prostate.

Adrenal Glands

The right adrenal gland is rounded, mottled echogenic cystic mass measuring 3.0 x 3.4 cm in size maintaining normal position and appearance of the visible peri-adrenal vasculature. The left adrenal gland was not visualized.

Spleen

Normal size and echogenic appearance. Smooth homogenous parenchyma and regular curvilinear capsule. Incidental myelolipoma is present. Normal volume of the splenic vasculature without any overt congestion or thrombosis evident. No inflammatory, neoplastic, infarction, or infiltrative changes evident. The spleen measured 0.8 cm in width.

Liver

Normal size with a diffuse increased echogenic and coarse appearance, normal portal markings, and regular curvilinear capsule. No nodules or masses evident. Normal appearance of the hepatic and portal vasculature.



PATIENT

Ziggy Marcano

SPECIES

Canine

BREED

Maltese Mix

SEX

Male

AGE

13 years

WEIGHT

13.8 lbs

INTERPRETED BY

Remo Lobetti, BVSc,
MMedVet (Med),
PhD, Dipl. ECVIM

IMAGING PERFORMED BY

Dr. Giuliani

HOSPITAL NAME

The Pet Hospital of
Stratford

REFERRING VET

Dr. Giuliani

INVOICE

69342

DATE

12/16/25

Gallbladder

The gallbladder is full containing a small amount of non-adhered, hyperechogenic sediment. Normal thickness and echogenic appearance of the wall. Normal size and appearance of the cystic and common bile duct.

Gastrointestinal

Normal appearance of the stomach, duodenum, small intestine, ileo-cecal junction, and colon with no loss of layering, 1:3 muscularis to mucosa ratio, normal wall thickness and peristaltic activity, and no distension of the lumen.

Pancreas

The visible sections of the pancreas are of normal size and echogenic appearance with a regular capsule. Normal echogenic appearance of the mesentery and fat surrounding the pancreas.

Free Abdomen

Normal mesenteric lymph nodes.

No ascites evident.

ULTRASONOGRAPHIC FINDINGS

- Right adrenal mass.
- Hepatopathy.
- Gallbladder sediment.

INTERPRETATION OF THE FINDINGS & FURTHER RECOMMENDATIONS

With the presenting clinical signs and the positive low-dose Dexamethasone suppression test, the appearance of the right adrenal gland is consistent with a functional carcinoma.

The hepatopathy can be ascribed as metabolic secondary to the Cushing's disease.

The gallbladder sediment can be considered an incidental finding.

Ideal management would be right-sided adrenalectomy and ideally if being considered a CT scan would be recommended.

Medical management with Trilostane would be an alternative approach.



PATIENT

Ziggy Marcano

SPECIES

Canine

BREED

Maltese Mix

SEX

Male

AGE

13 years

WEIGHT

13.8 lbs

INTERPRETED BY

Remo Lobetti, BVSc,
MMedVet (Med),
PhD, Dipl. ECVIM

IMAGING PERFORMED BY

Dr. Giuliani

HOSPITAL NAME

The Pet Hospital of
Stratford

REFERRING VET

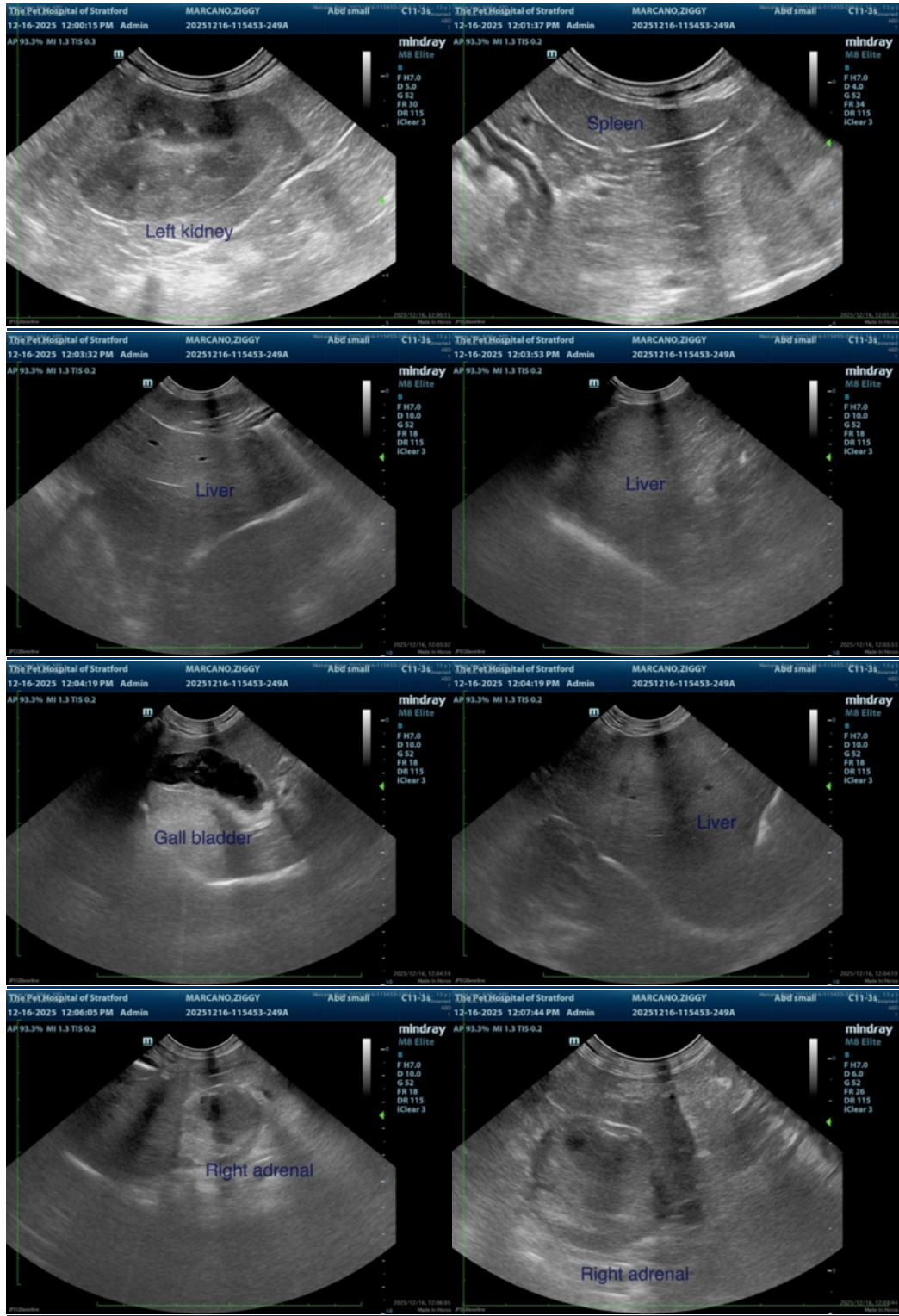
Dr. Giuliani

INVOICE

69342

DATE

12/16/25





PATIENT

Ziggy Marcano

SPECIES

Canine

BREED

Maltese Mix

SEX

Male

AGE

13 years

WEIGHT

13.8 lbs

INTERPRETED BY

Remo Lobetti, BVSc,
MMedVet (Med),
PhD, Dipl. ECVIM

IMAGING PERFORMED BY

Dr. Giuliani

HOSPITAL NAME

The Pet Hospital of
Stratford

REFERRING VET

Dr. Giuliani

INVOICE

69342

DATE

12/16/25

The information and recommendations provided are based on the images presented by the referring veterinarian/sonographer. No evaluation can be communicated regarding pathology that was not visible in the image/video clips provided.

Thank you for this referral. If the clinical or image interpretation does not parallel your findings or if I can be of any further assistance please contact me.

Remo Lobetti, BVSc, MMedVet (Med), PhD, Dipl. ECVIM (Internal Medicine)

info@sonopath.com