



PATIENT

Taggie Lucky

SPECIES

Canine

BREED

Labrador Cross

SEX

Spayed female

AGE

1 year

WEIGHT

15 kg

INTERPRETED BY

Remo Lobetti, BVSc,
MMedVet (Med),
PhD, Dipl. ECVIM

IMAGING PERFORMED BY

Dr. Ward

HOSPITAL NAME

Kenora VC

REFERRING VET

Dr. Ward

INVOICE

69348

DATE

12/16/25

PRESENTING CLINICAL SIGNS

History: Ongoing polyuria and inappropriate urination. At times, will urinate >10x/day. Not polydipsic. History of bacteriuria but recent culture negative. Please note that we often experience negative cultures in our region due to transport (nearest lab 3hrs away). In the past has responded to abx therapy. Bloodwork normal. Was on Stilbestrol and experienced inappropriate side effects such as vulvar bleeding and mammary enlargement after <1 week of therapy. Currently on 25mg Proin BID and incontinence has reduced to 3x episodes/week, but remains present.

ULTRASONOGRAPHIC EXAMINATION OF THE ABDOMEN

Urinary System

The urinary bladder is full with a normal thickness and smooth appearance of the wall. Normal anechoic urine with no sediment or uroliths evident.

Normal appearance of the trigone area, proximal urethra, and iliac blood vessels.

Normal appearance and size of the iliac lymph nodes. Ureters not visualized, which can be considered a normal finding.

Normal renal size (left measured 5.0 cm, right measured 4.5 cm), architecture, echogenic appearance, cortico-medullary differentiation, which maintains a 1:3 cortex to medulla ratio, pelvis, and capsule. No infarcts, mineralization or renoliths evident. Normal color flow pattern is evident in both kidneys.

Adrenal Glands

Normal shape, echogenic appearance, size, position, and appearance of the visible peri-adrenal vasculature. Left adrenal gland measured 0.45 cm in width. The right adrenal gland measured 0.41 cm in width.

Spleen

Normal size and echogenic appearance. Smooth homogenous parenchyma and regular curvilinear capsule. Normal volume of the splenic vasculature without any overt congestion or thrombosis evident. No inflammatory, neoplastic, infarction, or infiltrative changes evident. The spleen measured 2.0 cm in width.

Liver

Normal size, echogenic appearance, portal markings, and regular curvilinear capsule. No nodules or masses evident. Normal appearance of the hepatic and portal vasculature.



PATIENT

Taggie Lucky

SPECIES

Canine

BREED

Labrador Cross

SEX

Spayed female

AGE

1 year

WEIGHT

15 kg

INTERPRETED BY

Remo Lobetti, BVSc,
MMedVet (Med),
PhD, Dipl. ECVIM

IMAGING PERFORMED BY

Dr. Ward

HOSPITAL NAME

Kenora VC

REFERRING VET

Dr. Ward

INVOICE

69348

DATE

12/16/25

Gallbladder

The gallbladder is full containing normal anechoic bile. Normal thickness and echogenic appearance of the wall. Normal size and appearance of the cystic and common bile duct.

Gastrointestinal

Normal appearance of the stomach, duodenum, small intestine, ileo-cecal junction, and colon with no loss of layering, 1:3 muscularis to mucosa ratio, normal wall thickness and peristaltic activity, and no distension of the lumen. Fecal material is present in the colon.

Pancreas

The visible sections of the pancreas are of normal size and echogenic appearance with a regular capsule. Normal echogenic appearance of the mesentery and fat surrounding the pancreas.

Free Abdomen

Normal mesenteric lymph nodes.

No ascites evident.

ULTRASONOGRAPHIC FINDINGS

- Normal ultrasound examination of the abdomen.

INTERPRETATION OF THE FINDINGS & FURTHER RECOMMENDATIONS

Based on the patient's history with the good response to antibiotic therapy, the most likely etiology would be bacterial cystitis.

Differential diagnosis to consider would be urethral pathology and vaginal pooling of urine.

Further assessment would be vaginoscopy and retrograde contrast urethrogram.

Management would be antibiotic therapy.



PATIENT

Taggie Lucky

SPECIES

Canine

BREED

Labrador Cross

SEX

Spayed female

AGE

1 year

WEIGHT

15 kg

INTERPRETED BY

Remo Lobetti, BVSc,
MMedVet (Med),
PhD, Dipl. ECVIM

IMAGING PERFORMED BY

Dr. Ward

HOSPITAL NAME

Kenora VC

REFERRING VET

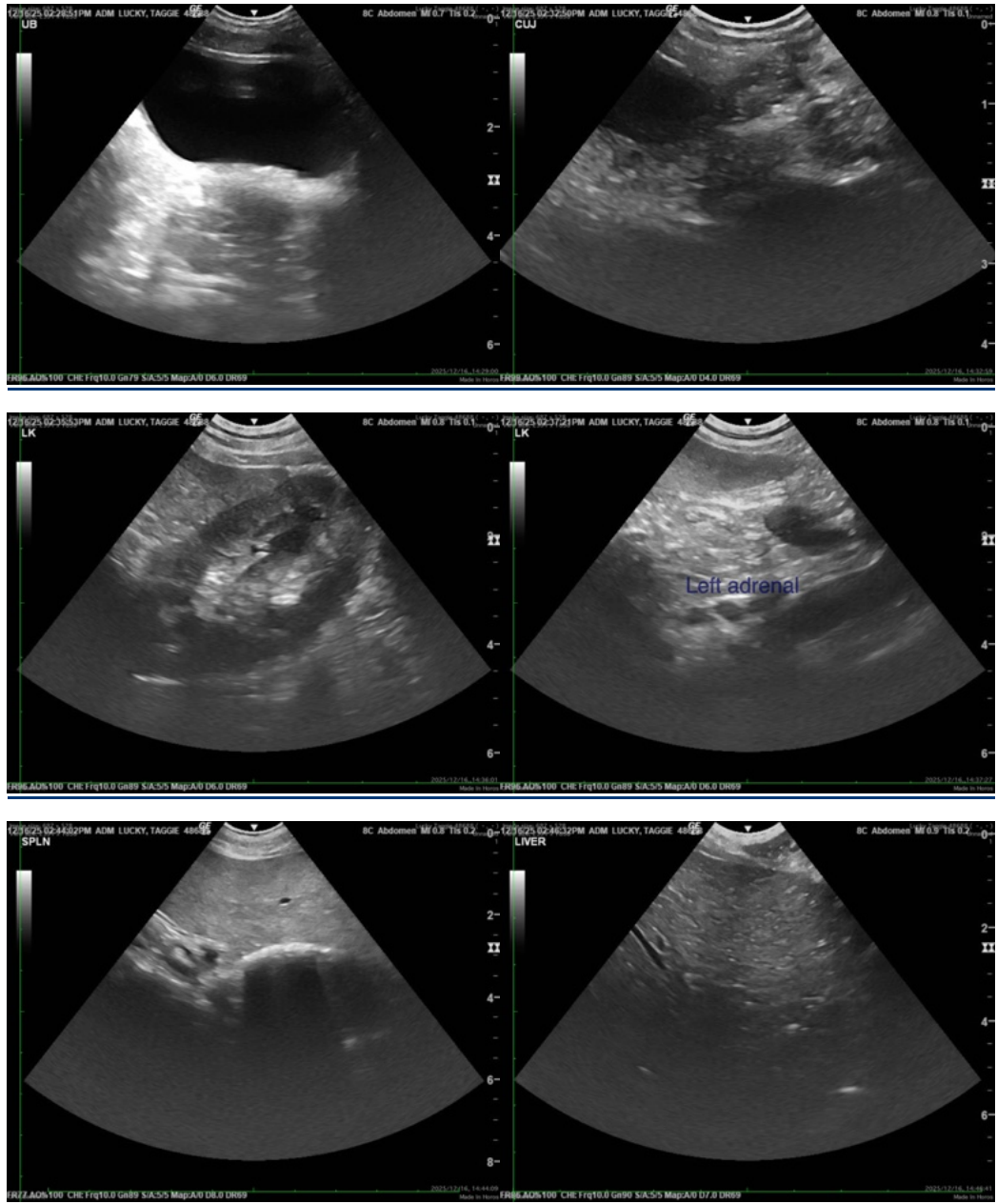
Dr. Ward

INVOICE

69348

DATE

12/16/25





PATIENT

Taggie Lucky

SPECIES

Canine

BREED

Labrador Cross

SEX

Spayed female

AGE

1 year

WEIGHT

15 kg

INTERPRETED BY

Remo Lobetti, BVSc,
MMedVet (Med),
PhD, Dipl. ECVIM

IMAGING PERFORMED BY

Dr. Ward

HOSPITAL NAME

Kenora VC

REFERRING VET

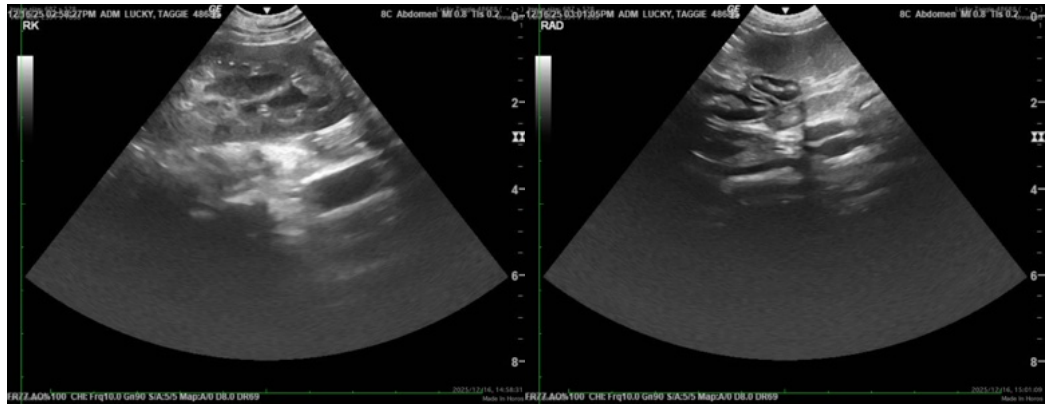
Dr. Ward

INVOICE

69348

DATE

12/16/25



The information and recommendations provided are based on the images presented by the referring veterinarian/sonographer. No evaluation can be communicated regarding pathology that was not visible in the image/video clips provided.

Thank you for this referral. If the clinical or image interpretation does not parallel your findings or if I can be of any further assistance please contact me.

Remo Lobetti, BVSc, MMedVet (Med), PhD, Dipl. ECVIM (Internal Medicine)

info@sonopath.com