



## PATIENT

Aspen Bingaman

## SPECIES

Canine

## BREED

St Bernard

## SEX

Intact male

## AGE

5 years

## WEIGHT

130 lbs

## INTERPRETED BY

Remo Lobetti, BVSc,  
MMedVet (Med),  
PhD, Dipl. ECVIM

## IMAGING PERFORMED BY

Amanda Hockenbrock

## HOSPITAL NAME

Lewisburg VH

## REFERRING VET

Dr. Huepenbecker

## INVOICE

69306

## DATE

12/15/25

## PRESENTING CLINICAL SIGNS

History: Chronic straining to pass a BM for a few months.

Abnormal PE/Chem/CBC/UA Results: Firm soft tissue structure palpable in caudal abdomen near pelvis, suspected to be large prostate.

## ULTRASONOGRAPHIC EXAMINATION OF THE ABDOMEN

### *Urinary System*

The urinary bladder is small with a normal thickness and smooth appearance of the wall. Normal anechoic urine with no sediment or uroliths evident.

Normal appearance of the trigone area, proximal urethra, and iliac blood vessels.

Normal appearance and size of the iliac lymph nodes. Ureters not visualized, which can be considered a normal finding.

Normal renal size (left measured 7.7 cm, right measured 8.0 cm), architecture, echogenic appearance, cortico-medullary differentiation, which maintains a 1:3 cortex to medulla ratio, pelvis, and capsule. No infarcts, mineralization or renoliths evident.

The prostate was symmetrically enlarged measuring 4.8 x 6.5 cm in size with a diffuse hyperechogenic appearance and a regular curvilinear capsule. Normal echogenic appearance of the periprostatic tissue.

### *Adrenal Glands*

The left adrenal gland is normal in shape, echogenic appearance, size, position, and appearance of the visible peri-adrenal vasculature. Left adrenal gland measured 0.5 cm and 0.49 cm in width. The right adrenal gland was not visualized.

### *Spleen*

Normal size and echogenic appearance. Smooth homogenous parenchyma and regular curvilinear capsule. Normal volume of the splenic vasculature without any overt congestion or thrombosis evident. No inflammatory, neoplastic, infarction, or infiltrative changes evident. The spleen measured 3.1 cm in width.

### *Liver*

Normal size, echogenic appearance, portal markings, and regular curvilinear capsule. No nodules or masses evident. Normal appearance of the hepatic and portal vasculature.



## PATIENT

Aspen Bingaman

## SPECIES

Canine

## BREED

St Bernard

## SEX

Intact male

## AGE

5 years

## WEIGHT

130 lbs

## INTERPRETED BY

Remo Lobetti, BVSc,  
MMedVet (Med),  
PhD, Dipl. ECVIM

## IMAGING PERFORMED BY

Amanda Hockenbrock

## HOSPITAL NAME

Lewisburg VH

## REFERRING VET

Dr. Huepenbecker

## INVOICE

69306

## DATE

12/15/25

## ***Gallbladder***

The gallbladder is full containing normal anechoic bile. Normal thickness and echogenic appearance of the wall. Normal size and appearance of the cystic and common bile duct.

## ***Gastrointestinal***

Normal appearance of the stomach, duodenum, small intestine, ileo-cecal junction, and colon with no loss of layering, 1:3 muscularis to mucosa ratio, normal wall thickness and peristaltic activity, and no distension of the lumen.

## ***Pancreas***

The visible sections of the pancreas are of normal size and echogenic appearance with a regular capsule. Normal echogenic appearance of the mesentery and fat surrounding the pancreas.

## ***Free Abdomen***

Normal mesenteric lymph nodes.

No ascites evident.

## **ULTRASONOGRAPHIC FINDINGS**

- Prostatomegaly.

## **INTERPRETATION OF THE FINDINGS & FURTHER RECOMMENDATIONS**

The most likely etiology for the prostatomegaly would be benign prostatic hyperplasia with prostatitis an unlikely differential diagnosis.

Further assessment that can be considered would be either FNA cytology of the prostate or prostatic wash for cytology and culture.

Management of the prostatomegaly would be either surgical or chemical castration.

Chemical castration would be the use of osaterone acetate, delmadinone acetate, or deslorelin acetate. This is less invasive and safer than surgical castration in systemically ill and potentially unstable patients.



**PATIENT**

Aspen Bingaman

**SPECIES**

Canine

**BREED**

St Bernard

**SEX**

Intact male

**AGE**

5 years

**WEIGHT**

130 lbs

**INTERPRETED BY**

Remo Lobetti, BVSc,  
MMedVet (Med),  
PhD, Dipl. ECVIM

**IMAGING PERFORMED BY**

Amanda Hockenbrock

**HOSPITAL NAME**

Lewisburg VH

**REFERRING VET**

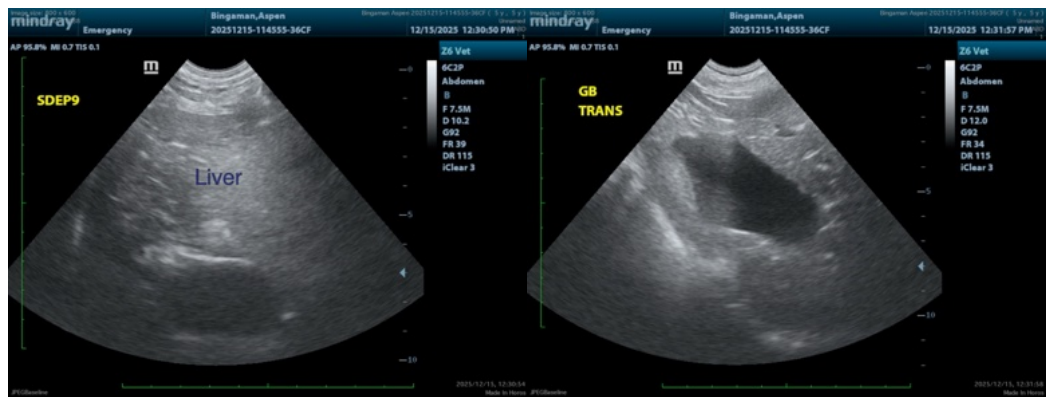
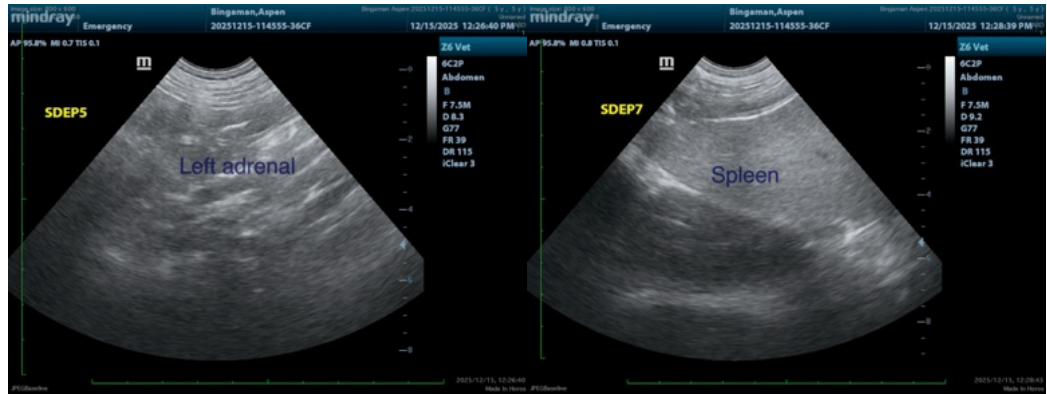
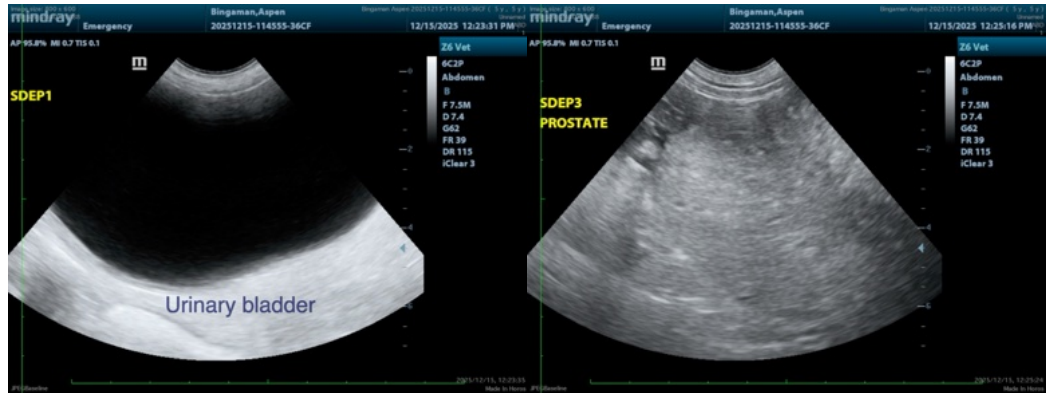
Dr. Huepenbecker

**INVOICE**

69306

**DATE**

12/15/25





## PATIENT

Aspen Bingaman

## SPECIES

Canine

## BREED

St Bernard

## SEX

Intact male

## AGE

5 years

## WEIGHT

130 lbs

## INTERPRETED BY

Remo Lobetti, BVSc,  
MMedVet (Med),  
PhD, Dipl. ECVIM

## IMAGING PERFORMED BY

Amanda Hockenbrock

## HOSPITAL NAME

Lewisburg VH

## REFERRING VET

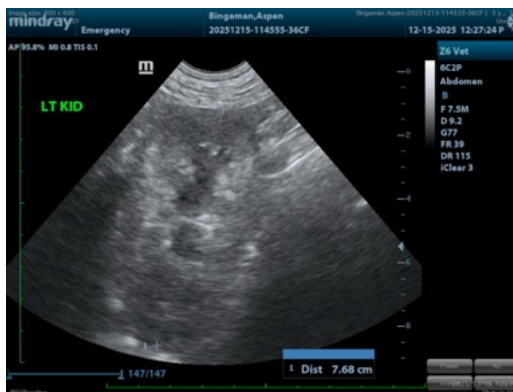
Dr. Huepenbecker

## INVOICE

69306

## DATE

12/15/25



The information and recommendations provided are based on the images presented by the referring veterinarian/sonographer. No evaluation can be communicated regarding pathology that was not visible in the image/video clips provided.

Thank you for this referral. If the clinical or image interpretation does not parallel your findings or if I can be of any further assistance please contact me.

Remo Lobetti, BVSc, MMedVet (Med), PhD, Dipl. ECVIM (Internal Medicine)

[info@sonopath.com](mailto:info@sonopath.com)