



PATIENT

Ruger Karrer

SPECIES

Canine

BREED

Rottweiler

SEX

Neutered male

AGE

9 years

WEIGHT

30.8 kg

INTERPRETED BY

Remo Lobetti, BVSc,
MMedVet (Med),
PhD, Dipl. ECVIM

IMAGING PERFORMED BY

Erin Wicks

HOSPITAL NAME

Shores Veterinary
Emergency Center

REFERRING VET

Dr. Law

INVOICE

69583

DATE

12/12/25

PRESENTING CLINICAL SIGNS

History: P has been having issues with hind limbs for months, Seemingly increasing where he can't do the activities he used to Previous Health Concerns none Current Medications Carprofen 75mg, Dasuquin senior, Omega's
Abnormal PE/Chem/CBC/UA Results: Rads: narrow disc before and after L4 displaced spleen caudally . small liver Full Bloodwork: Chol 326 ; TT3 0.4; CLIA 0.76

ULTRASONOGRAPHIC EXAMINATION OF THE ABDOMEN

Urinary System

The urinary bladder is small with a normal thickness and smooth appearance of the wall. Normal anechoic urine with no sediment or uroliths evident.

Normal appearance of the trigone area, proximal urethra, and iliac blood vessels.

Normal appearance and size of the iliac lymph nodes. Ureters not visualized, which can be considered a normal finding.

Normal renal size (left measured 7.0 cm, right measured 6.6 cm), architecture, echogenic appearance, cortico-medullary differentiation, which maintains a 1:3 cortex to medulla ratio, pelvis, and capsule. No infarcts, mineralization or renoliths evident. Normal color flow pattern is evident in both kidneys.

The prostate is small and hypoechogenic.

Adrenal Glands

Normal shape, echogenic appearance, size, position, and appearance of the visible peri-adrenal vasculature. Left adrenal gland measured 0.63 cm and 0.68 cm in width. The right adrenal gland measured 0.52 cm in width.

Spleen

Normal size and echogenic appearance. Smooth homogenous parenchyma and regular curvilinear capsule. Normal volume of the splenic vasculature without any overt congestion or thrombosis evident. Small focal hypoechogenic nodule in the body of the spleen measuring approximately 1 cm in size. The spleen measured 2.1 cm in width.

Liver

Normal size, echogenic appearance, portal markings, and regular curvilinear capsule. No nodules or masses evident. Normal appearance of the hepatic and portal vasculature.



PATIENT

Ruger Karrer

SPECIES

Canine

BREED

Rottweiler

SEX

Neutered male

AGE

9 years

WEIGHT

30.8 kg

INTERPRETED BY

Remo Lobetti, BVSc,
MMedVet (Med),
PhD, Dipl. ECVIM

IMAGING PERFORMED BY

Erin Wicks

HOSPITAL NAME

Shores Veterinary
Emergency Center

REFERRING VET

Dr. Law

INVOICE

69583

DATE

12/12/25

Gallbladder

The gallbladder is full containing normal anechoic bile. Normal thickness and echogenic appearance of the wall. Normal size and appearance of the cystic and common bile duct.

Gastrointestinal

Normal appearance of the stomach, duodenum, small intestine, ileo-cecal junction, and colon with no loss of layering, 1:3 muscularis to mucosa ratio, normal wall thickness and peristaltic activity, and no distension of the lumen. A moderate amount of ingesta is present in the stomach compatible with a recent meal.

Pancreas

The visible sections of the pancreas are of normal size and echogenic appearance with a regular capsule. Normal echogenic appearance of the mesentery and fat surrounding the pancreas.

Free Abdomen

Normal mesenteric lymph nodes.

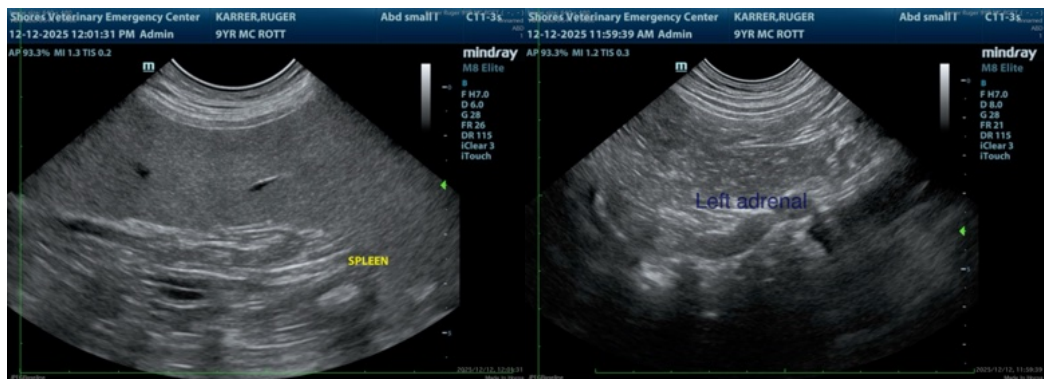
No ascites evident.

ULTRASONOGRAPHIC FINDINGS

Splenic nodule, otherwise a normal ultrasound examination of the abdomen.

INTERPRETATION OF THE FINDINGS & FURTHER RECOMMENDATIONS

Although the most likely etiology for the splenic nodule would be incidental reactive hyperplasia/extramedullary hematopoiesis, regular ultrasound monitoring would be recommended. No specific therapy is recommended at this time.





PATIENT

Ruger Karrer

SPECIES

Canine

BREED

Rottweiler

SEX

Neutered male

AGE

9 years

WEIGHT

30.8 kg

INTERPRETED BY

Remo Lobetti, BVSc,
MMedVet (Med),
PhD, Dipl. ECVIM

IMAGING PERFORMED BY

Erin Wicks

HOSPITAL NAME

Shores Veterinary
Emergency Center

REFERRING VET

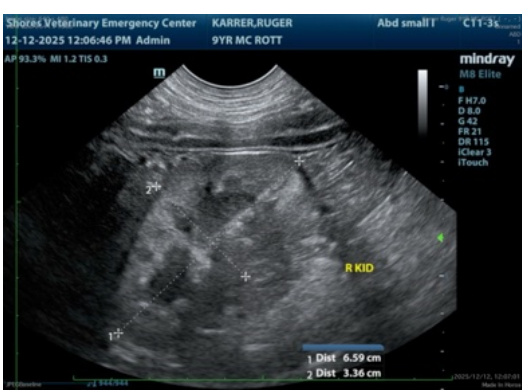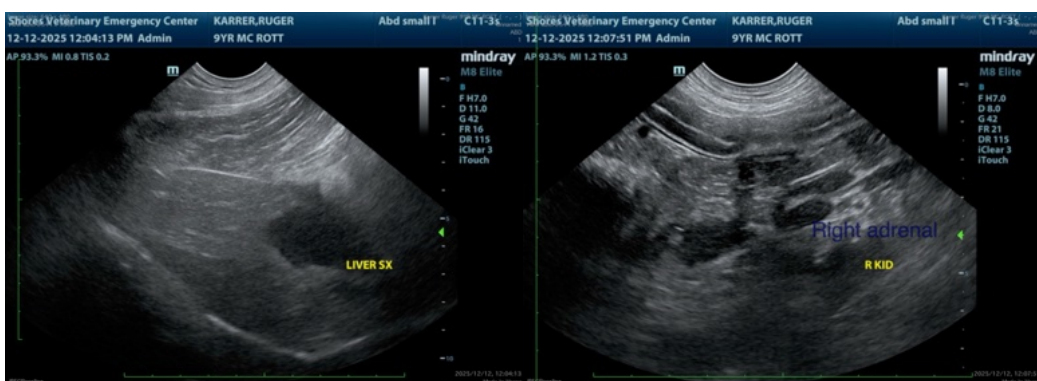
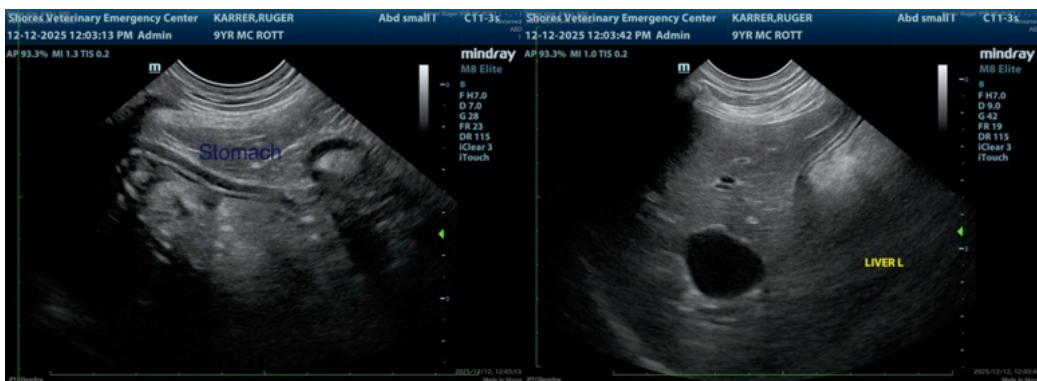
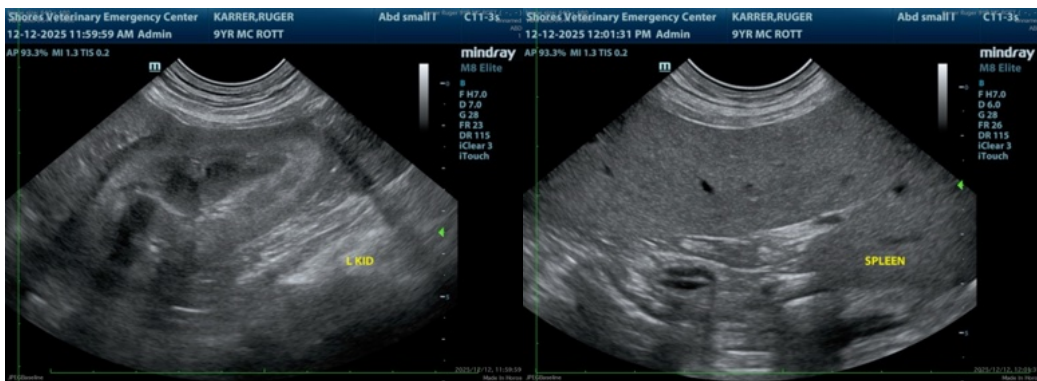
Dr. Law

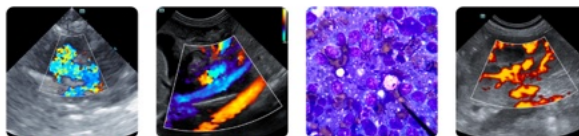
INVOICE

69583

DATE

12/12/25





PATIENT

Ruger Karrer

SPECIES

Canine

BREED

Rottweiler

SEX

Neutered male

AGE

9 years

WEIGHT

30.8 kg

INTERPRETED BY

Remo Lobetti, BVSc,
MMedVet (Med),
PhD, Dipl. ECVIM

IMAGING PERFORMED BY

Erin Wicks

HOSPITAL NAME

Shores Veterinary
Emergency Center

REFERRING VET

Dr. Law

INVOICE

69583

DATE

12/12/25

The information and recommendations provided are based on the images presented by the referring veterinarian/sonographer. No evaluation can be communicated regarding pathology that was not visible in the image/video clips provided.

Thank you for this referral. If the clinical or image interpretation does not parallel your findings or if I can be of any further assistance please contact me.

Remo Lobetti, BVSc, MMedVet (Med), PhD, Dipl. ECVIM (Internal Medicine)

info@sonopath.com