



PATIENT

Max Mills

SPECIES

Canine

BREED

Mix

SEX

Neutered male

AGE

13 years

WEIGHT

33.6 lbs

INTERPRETED BY

Remo Lobetti, BVSc,
MMedVet (Med),
PhD, Dipl. ECVIM

IMAGING PERFORMED BY

Dr. Vida

HOSPITAL NAME

Sherrills Ford AH

REFERRING VET

Dr. Vida

INVOICE

69620

DATE

12/12/25

PRESENTING CLINICAL SIGNS

History: Patient presented today for weakness in hind legs. Noted osteoarthritis previously but possible ataxia reported this AM after eating. He wanted to eat the other dog's food which is abnormal for him. Previous BW had hypoglycemia in 11/2025.
Abnormal PE/Chem/CBC/UA Results: IH BG: 59--confirmed with several readings (previous BG last month as 52 at Antech) Noted osteoarthritis in limbs. Possible slower CP in RR limb.

ULTRASONOGRAPHIC EXAMINATION OF THE ABDOMEN

Urinary System

The urinary bladder is full with a normal thickness and smooth appearance of the wall. Normal anechoic urine with no sediment or uroliths evident.

Normal appearance of the trigone area, proximal urethra, and iliac blood vessels.

Normal appearance and size of the iliac lymph nodes. Ureters not visualized, which can be considered a normal finding.

Normal renal size (left measured 5.4 cm, right measured 4.9 cm), architecture, echogenic appearance, cortico-medullary differentiation, which maintains a 1:3 cortex to medulla ratio, pelvis, and capsule. No infarcts, mineralization or renoliths evident.

The prostate is small and hypoechogenic.

Adrenal Glands

Normal shape, echogenic appearance, size, position, and appearance of the visible peri-adrenal vasculature. Left adrenal gland measured 2.51 cm in length x 0.49 cm and 0.45 cm in width. The right adrenal gland measured 1.98 cm in length x 0.4 cm and 0.52 cm in width.

Spleen

Normal size and echogenic appearance. Smooth homogenous parenchyma and regular curvilinear capsule. Normal volume of the splenic vasculature without any overt congestion or thrombosis evident. Focal, hypoechogenic parenchymal nodule in the body of the spleen measuring 0.7 cm in width. The spleen measures 1.4 cm in width.

Liver

Normal size, echogenic appearance, portal markings, and regular curvilinear capsule. No nodules or masses evident. Normal appearance of the hepatic and portal vasculature.



PATIENT

Max Mills

SPECIES

Canine

BREED

Mix

SEX

Neutered male

AGE

13 years

WEIGHT

33.6 lbs

INTERPRETED BY

Remo Lobetti, BVSc,
MMedVet (Med),
PhD, Dipl. ECVIM

IMAGING PERFORMED BY

Dr. Vida

HOSPITAL NAME

Sherrills Ford AH

REFERRING VET

Dr. Vida

INVOICE

69620

DATE

12/12/25

Gallbladder

The gallbladder is full containing normal anechoic bile. Normal thickness and echogenic appearance of the wall. Normal size and appearance of the cystic and common bile duct.

Gastrointestinal

Normal appearance of the stomach, duodenum, small intestine, ileo-cecal junction, and colon with no loss of layering, 1:3 muscularis to mucosa ratio, normal wall thickness and peristaltic activity, and no distension of the lumen.

Pancreas

The visible sections of the pancreas are of normal size and echogenic appearance with a regular capsule. Normal echogenic appearance of the mesentery and fat surrounding the pancreas.

Free Abdomen

Normal mesenteric lymph nodes.

No ascites evident.

ULTRASONOGRAPHIC FINDINGS

- Splenic nodule.

INTERPRETATION OF THE FINDINGS & FURTHER RECOMMENDATIONS

The most likely etiology for the splenic nodule would be reactive hyperplasia/extramedullary hemopoiesis with hematoma, granuloma and emerging neoplasia an unlikely differential diagnosis.

On this ultrasound there is no obvious etiology for the hypoglycemia.

Further assessment would be insulin assay (taken at the time of hyperglycemia) and possibly a CT scan of the thorax and abdomen.

Specific therapy would be dependent on an etiological diagnosis.



PATIENT

Max Mills

SPECIES

Canine

BREED

Mix

SEX

Neutered male

AGE

13 years

WEIGHT

33.6 lbs

INTERPRETED BY

Remo Lobetti, BVSc,
MMedVet (Med),
PhD, Dipl. ECVIM

IMAGING PERFORMED BY

Dr. Vida

HOSPITAL NAME

Sherrills Ford AH

REFERRING VET

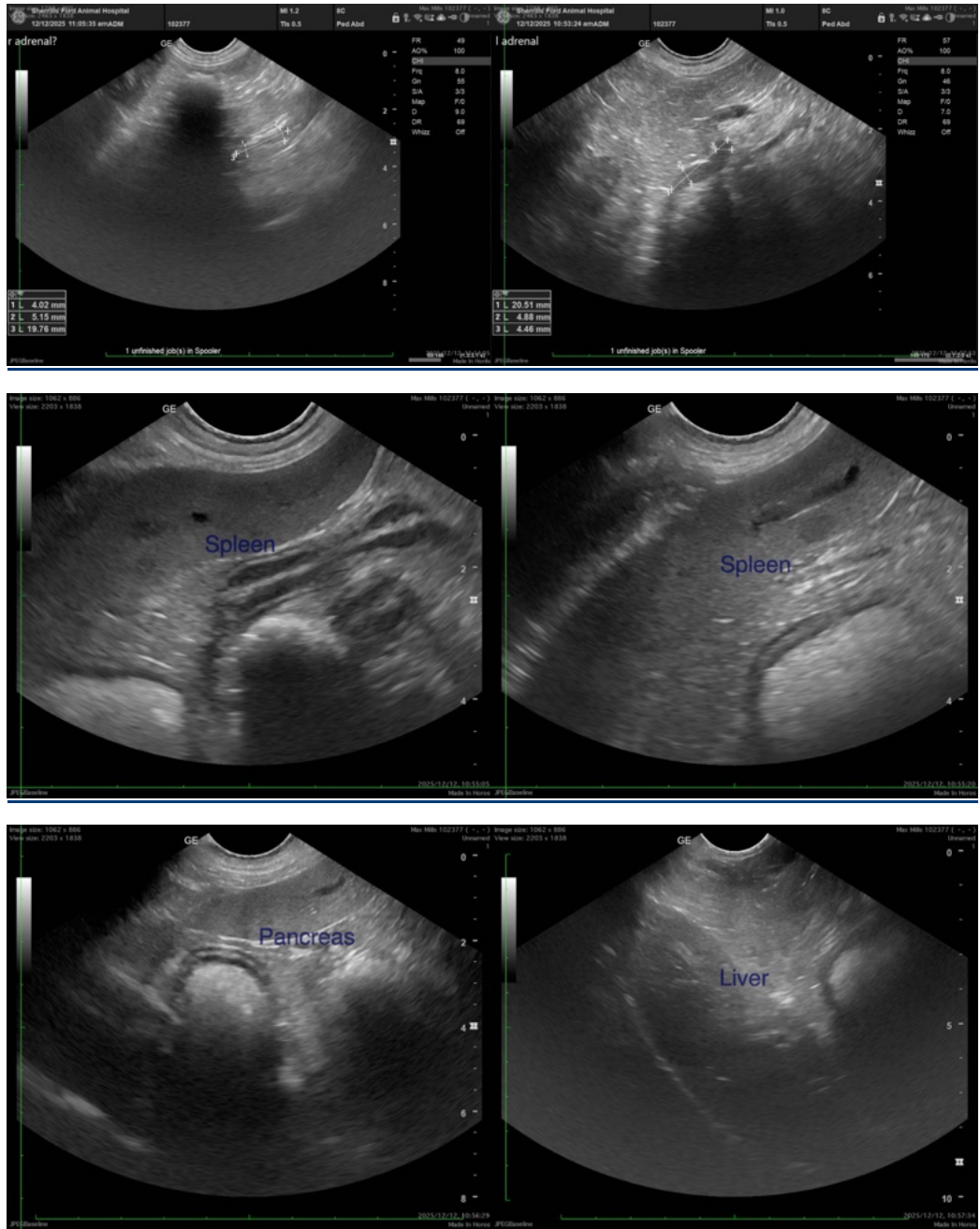
Dr. Vida

INVOICE

69620

DATE

12/12/25





PATIENT

Max Mills

SPECIES

Canine

BREED

Mix

SEX

Neutered male

AGE

13 years

WEIGHT

33.6 lbs

INTERPRETED BY

Remo Lobetti, BVSc,
MMedVet (Med),
PhD, Dipl. ECVIM

IMAGING PERFORMED BY

Dr. Vida

HOSPITAL NAME

Sherrills Ford AH

REFERRING VET

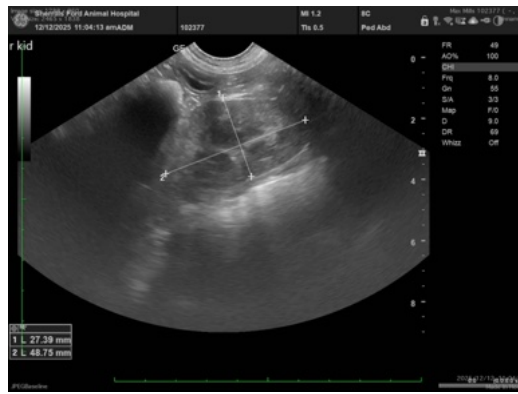
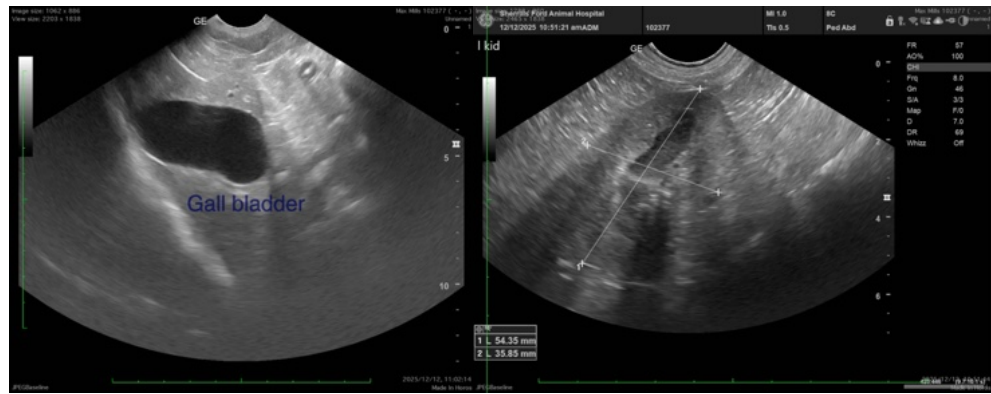
Dr. Vida

INVOICE

69620

DATE

12/12/25



The information and recommendations provided are based on the images presented by the referring veterinarian/sonographer. No evaluation can be communicated regarding pathology that was not visible in the image/video clips provided.

Thank you for this referral. If the clinical or image interpretation does not parallel your findings or if I can be of any further assistance please contact me.

Remo Lobetti, BVSc, MMedVet (Med), PhD, Dipl. ECVIM (Internal Medicine)

info@sonopath.com