



PATIENT

Moose Redifer

SPECIES

Canine

BREED

Maltese

SEX

Neutered male

AGE

7 years

WEIGHT

8.5 lbs

INTERPRETED BY

Remo Lobetti, BVSc,
MMedVet (Med),
PhD, Dipl. ECVIM

IMAGING PERFORMED BY

Charlie Rodriguez

HOSPITAL NAME

Bethany Family Pet
Clinic

REFERRING VET

Dr. Rodriguez

INVOICE

69534

DATE

12/11/25

PRESENTING CLINICAL SIGNS

Doing well at home but, repeated labwork over the years show increasing ALKP. ALT is normal.
Abnormal PE/Chem/CBC/UA Results: ALKP is 309 (5-131)

ULTRASONOGRAPHIC EXAMINATION OF THE ABDOMEN

Urinary System

The urinary bladder is full with a normal thickness and smooth appearance of the wall. Normal anechoic urine with no sediment or uroliths evident.

Normal appearance of the trigone area, proximal urethra, and iliac blood vessels.

Normal appearance and size of the iliac lymph nodes. Ureters not visualized, which can be considered a normal finding.

Normal renal size (left measured 3.0 cm, right measured 3.6 cm), architecture, echogenic appearance, cortico-medullary differentiation, which maintains a 1:3 cortex to medulla ratio, pelvis, and capsule. No infarcts, mineralization or renoliths evident.

The prostate is small and hypoechoic.

Adrenal Glands

The adrenal glands were not clearly visualized, but appear to be of normal shape, echogenic appearance and size.

Spleen

Normal size and echogenic appearance. Smooth homogenous parenchyma and regular curvilinear capsule. Normal volume of the splenic vasculature without any overt congestion or thrombosis evident. No inflammatory, neoplastic, infarction, or infiltrative changes evident. The spleen measured 1.1 cm in width.

Liver

Normal size, echogenic appearance, portal markings, and regular curvilinear capsule. No nodules or masses evident. Normal appearance of the hepatic and portal vasculature.

Gallbladder

The gallbladder is full containing normal anechoic bile. Normal thickness and echogenic appearance of the wall. Normal size and appearance of the cystic and common bile duct.



PATIENT

Moose Redifer

SPECIES

Canine

BREED

Maltese

SEX

Neutered male

AGE

7 years

WEIGHT

8.5 lbs

INTERPRETED BY

Remo Lobetti, BVSc,
MMedVet (Med),
PhD, Dipl. ECVIM

IMAGING PERFORMED BY

Charlie Rodriguez

HOSPITAL NAME

Bethany Family Pet
Clinic

REFERRING VET

Dr. Rodriguez

INVOICE

69534

DATE

12/11/25

Gastrointestinal

Normal appearance of the stomach, duodenum, small intestine, ileo-cecal junction, and colon with no loss of layering, 1:3 muscularis to mucosa ratio, normal wall thickness and peristaltic activity, and no distension of the lumen.

Pancreas

The visible sections of the pancreas are of normal size and echogenic appearance with a regular capsule. Normal echogenic appearance of the mesentery and fat surrounding the pancreas.

Free Abdomen

Normal mesenteric lymph nodes.

No ascites evident.

ULTRASONOGRAPHIC FINDINGS

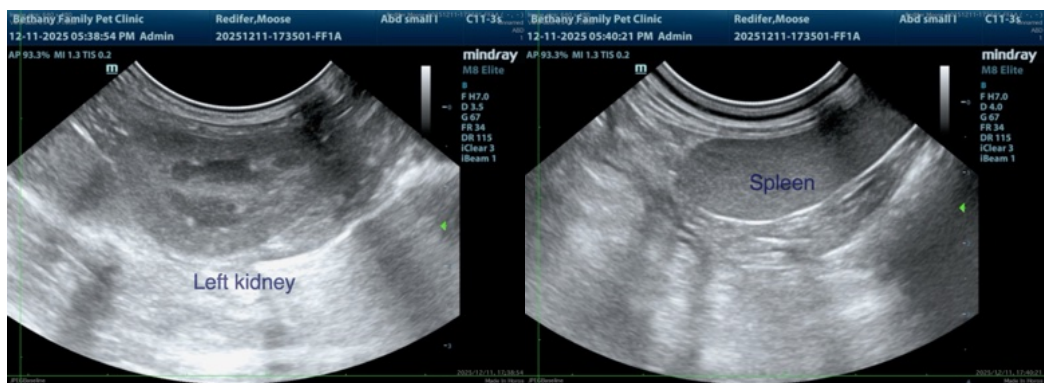
- Normal ultrasound examination of the abdomen.

INTERPRETATION OF THE FINDINGS & FURTHER RECOMMENDATIONS

On this ultrasound there is no obvious etiology for the mildly elevated ALP activity. Although the liver appears ultrasonographically normal, with the progressive elevation of ALP activity an underlying hepatopathy such as reactive hyperplasia, vacuolar and metabolic should still be considered with hepatitis and infiltrative neoplasia highly unlikely differential diagnosis.

Further assessment would be FNA cytology of the liver; however, a tru cut or wedge biopsy may be required for a final etiological diagnosis.

Specific therapy would be dependent on an etiological diagnosis. Symptomatic management would be the use of Ursodiol with regular monitoring of liver enzyme activity.





PATIENT

Moose Redifer

SPECIES

Canine

BREED

Maltese

SEX

Neutered male

AGE

7 years

WEIGHT

8.5 lbs

INTERPRETED BY

Remo Lobetti, BVSc,
MMedVet (Med),
PhD, Dipl. ECVIM

IMAGING PERFORMED BY

Charlie Rodriguez

HOSPITAL NAME

Bethany Family Pet
Clinic

REFERRING VET

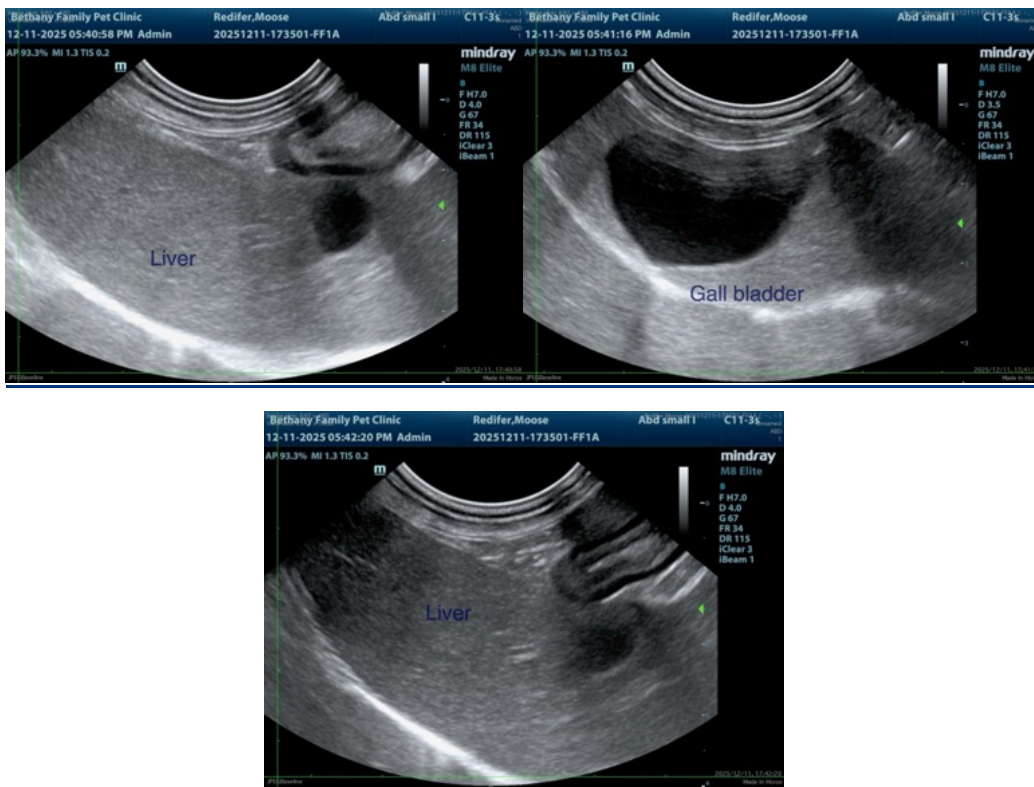
Dr. Rodriguez

INVOICE

69534

DATE

12/11/25



The information and recommendations provided are based on the images presented by the referring veterinarian/sonographer. No evaluation can be communicated regarding pathology that was not visible in the image/video clips provided.

Thank you for this referral. If the clinical or image interpretation does not parallel your findings or if I can be of any further assistance please contact me.

Remo Lobetti, BVSc, MMedVet (Med), PhD, Dipl. ECVIM (Internal Medicine)

info@sonopath.com